

# When No Tumor can be Found in Patients with the Diagnosis of Pancreatic Hyperinsulinism—Unsuccessful Operation or a Noninsulinoma Pancreatic Hypoglycemia Syndromes (NIPHS): Personal Experience in 20 of 125 Patients

<sup>1</sup>Shun Yu Chi, <sup>2</sup>Achim Starke, <sup>3</sup>Bernhard Lammers, <sup>4</sup>Fong Fu Chou, <sup>5</sup>Peter Goretzki

<sup>1</sup>Department of Visceral and Endocrine Surgery, Lukaskrankenhaus, Preussenstrasse 84, 41464 Neuss, Germany, Department of Surgery, Chang Gung Memorial Hospital-Kaohsiung Medical Center, Chang Gung University College of Medicine, Taiwan

<sup>2</sup>Insulinoma and GEP Tumor Center Neuss-Düsseldorf, Lukaskrankenhaus Neuss, Preussenstrasse 84, 41464 Neuss, Germany Department of Internal Medicine, University Hospital, Heinrich-Heine-University, Moorenstrasse 5, 40225 Düsseldorf, Germany

<sup>3</sup>Department of Visceral and Endocrine Surgery, Lukaskrankenhaus, Preussenstrasse 84, 41464 Neuss, Germany

<sup>4</sup>Department of Surgery, Chang Gung Memorial Hospital-Kaohsiung Medical Center, Chang Gung University College of Medicine, Taiwan

<sup>5</sup>Insulinoma and GEP Tumor Center Neuss-Düsseldorf, Lukaskrankenhaus Neuss, Preussenstrasse 84, 41464 Neuss, Germany Department of Visceral and Endocrine Surgery, Lukaskrankenhaus, Preussenstrasse 84, 41464 Neuss, Germany

**Correspondence:** Professor Peter Goretzki, Department of Visceral and Endocrine Surgery, Lukaskrankenhaus Preussenstrasse 84, 41464 Neuss, Germany, Phone: +49-2131-888-3000, Fax: +49-2131-888-3099 e-mail: pgoretzki@lukasneuss.de

## Abstract

**Background:** With combination of intraoperative ultrasound and palpation, more than 90-95% of all insulinomas will be found during exploration. But even in experienced hands some are not detected. When a familial multiple endocrine neoplasia type 1 (MEN-1) has been excluded, the question arises intraoperatively, whether we just failed to find an insulinoma or whether another illness is causing the disease. The latter may be a noninsulinoma pancreatic hypoglycemia caused by focal hyperplastic of islets or by neoplastic isleta with or without microadenomas (synonymous: "adult nesidioblastosis" or "insulinomatosis" by pathologists and "NIPHS" by clinicians).

Our own experience with 20 out of 125 patients with pancreatic hyperinsulinism is demonstrated, where we did not find an insulinoma intraoperatively. In some of them operative flaws led to this result and in the majority preoperative diagnosis of NIPHS was confirmed. Thus NIPHS accounts for 16% of all forms of sporadic pancreatic hyperinsulinism and has to be integrated into our daily preoperative work-up and intraoperative management.

**Patients and methods:** The charts of 125 adult patients with documented endogenous hyperinsulinemic hypoglycemia were extracted, operated on between 1986 and 2008. All patients with benign or malignant solid insulinoma and all patients with familial MEN-1 were excluded, leaving 20 patients (xx%) with sporadic disease, in whom no insulinoma was detected during exploration. These were 4 men and 16 women with a mean age of  $45.4 \pm 14.8$  years (range 18 to 76 years).

**Results:** Eleven patients underwent operation for a presumed insulinoma, of which the final diagnoses were insulinoma in 4 (three at the head and one at the tail of pancreas) and NIPHS in 7, respectively. The other 9 patients underwent operation for preoperatively diagnosed NIPHS and were all proven to have NIPHS, postoperatively. Patients with insulinoma were all cured by removal of their tumors. The 11 patients with NIPHS were treated by a partial or subtotal pancreatectomy and none had reported further episodes of neuroglycopenia after 77 months of follow-up. Three of them developed postoperative insulin-dependent diabetes mellitus.

**Conclusion:** When a circumscribed insulinoma cannot be detected by preoperative localization studies in patients with proven endogenous hyperinsulinemic hypoglycemia the biochemical results of oral glucose tolerance test (OGTT) and 72 hours fast should be reassessed, carefully. When the data clearly point to an insulinoma, a thorough surgical examination undertaken, with special focus of attention on the head and uncinat process of the pancreas. If still no tumor is found, the operation should be terminated. When results of OGTT and 72 hours fast assume NIPHS a selective arterial calcium stimulation test is indicated, since the necessary 70-80% pancreatectomy can be guided by results of the stimulated insulin gradient. Following these principles all 20 patients were cured in a mean follow-up of 7.5 years. In 2 patients (10%), however, extensive partial pancreatectomy resulted in a mild insulin dependent diabetes mellitus.

Altogether sixteen out of 20 patients (%) with sporadic endogenous pancreatic hyperinsulinemia and failed demonstration of a single tumor proved to have NIPHS. Even when an insulinoma is suspected after biochemical analysis and preoperative localization study as well as intraoperative findings failed to show a tumor (n = 11) 7 patients (%) demonstrated to have NIPHS.

**Keywords:** Insulinoma, noninsulinoma-pancreatogenic-hypoglycemia (NIPHS), nesidioblastosis, recurrent hypoglycemia, persistent and recurrent hyperinsulinism.

## INTRODUCTION

Endogenous hyperinsulinemic hypoglycemia in adults almost always is caused by insulinomas; most of them are solitary and benign.<sup>1</sup> Only very few patients with familial MEN-1 disease show multiple tumors and very seldomly hyperinsulinemic hypoglycemia can be caused by a noninsulinoma pancreatico-genous hypoglycemic syndrome (NIPHS). This compound of probably different distinct hypoglycemic disorders is characterized by spontaneous or only postprandial neuroglycopenia, sometimes negative 72 hours fast tests, negative perioperative localization studies for insulinoma, rather small elevation of pathologic insulin gradients and by a positive response to selective arterial calcium stimulation.<sup>2</sup>

The major challenge in managing insulinoma is the accurate localization prior to operation and during operation, nowadays. With the remarkable advances in preoperative localization techniques and intraoperative endoscopic ultrasound (IOUS) virtually all insulinomas can be found and even minimal invasive approaches are used successfully, today.<sup>4</sup>

For patients with NIPHS, however, not only differential diagnosis to insulinoma is difficult but also the decision of start and extent of partial pancreatectomy is still undefined.

Thus differentiation between insulinoma and NIPHS is based on a combined oral glucose tolerance test (OGTT) and standard 72 hours fast test with almost distinctive results.<sup>5</sup> Results of selective arterial calcium stimulation guides partial pancreatectomy in NIPHS.<sup>6</sup>

However, even today, incidences occur, where an insulinoma has been overseen by an experienced surgeon and where OGTT 72 hours fast was not as distinctive, as expected. We, therefore, still encounter situations, where the surgeons fails to find the expected pancreatic tumor and when the question arises, whether this is caused by a technical failure or by an unexpected NIPHS.

The aim of our study is to show our personal experience in 20 out of 125 patients with sporadic pancreatic hyperinsulinism, where a circumscribed insulinoma was not found at first abdominal exploration. We then discuss the optimal pre- and intraoperative strategy for such patients depending on the fact, whether NIPHS has been suspected or not.

## PATIENTS AND METHODS

The medical records of all adult patients receiving abdominal exploration for endogenous hyperinsulinemic hypoglycemia at the Heinrich-Heine University Hospital, Düsseldorf, Germany between 1986 and 2000, and at the Lukas Hospital, Neuss, Germany between 2001 and 2008, were reviewed. Patients with familial history of MEN-1 were excluded. Of 125 cases identified, 105 (84%) had one insulinomas found at operation, and 20 (16%) had no circumscribed tumor detected during exploration by means of careful palpation and intraoperative ultrasound.

The clinical characteristics of these 20 patients are listed in Table 1. There were 4 men and 16 women, with a mean age of

45.4 ± 14.8 years (range 18 to 76 years). The duration of symptoms before operation ranged from one month to 240 months (mean 45.4 months, median 12 months). Follow-up duration ranged from 6 to 250 months with a mean of 77 months.

Of these 20 patients, eleven (#1-9, 18 and 20) were operated on with a presumptive preoperative diagnosis of insulinoma. The other nine patients (#10-17, and 19) received operation with a presumptive preoperative diagnosis of NIPHS based on the specific biochemical findings during a combined OGTT and standard fast test. After operation, the final diagnosis was insulinoma in four (#1, 2, 6, 18 and 20) and NIPHS in sixteen. Thus seven patients (#3-5, and 7-9) who received operation with the preoperative diagnosis of insulinoma and all 9 patients with preoperative diagnosis of NIPHS were proven to have NIPHS, postoperatively.

The biochemical examination, preoperative localization study, surgical procedure, histopathology, complication and outcome of these patients are reviewed.

## RESULTS

### Biochemical Examination

The biochemical examination performed at our institution consisted of an initial OGTT followed by a standard 72 hours fast test. One hundred gram glucose, which was replaced by 75 gm since 2001, was given orally immediately preceding the fast. Blood samples were analyzed for venous blood glucose, serum insulin, C-peptide, and proinsulin. Blood samples were taken before and every 30 minutes after the glucose load for the first 3 hours and then hourly thereafter. After 6 hours the intervals were extended to 4 hours until completion of the fast within 72 hours (patient had no hypoglycemia) or until at least three consecutive and reproducible blood glucose values below 40 mg/dl were drawn within 15-30 minutes. Biochemical hypoglycemia was defined as any venous blood glucose below 40 mg/dl irrespective of clinical symptoms. Clinically relevant hypoglycemia was defined as blood glucose below 45 mg/dl in the presence of simultaneous symptoms. All of the tests were meticulously supervised by one of us (AS).

As shown in Table 1, Patients #3, 5, and 9 did not undergo an initial OGTT since the available data of the fast test performed at an outside hospital clearly showed an elevated serum insulin level in concurrent hypoglycemia. All the other patients underwent a combined OGTT followed by a standard 72 hours fast test. Patients #1-9, 18 and 20 were speculated of having insulinoma due to the documented endogenous hyperinsulinemic hypoglycemia during the fast test. Patients 1, 2, 4, 6, 8 and 20 also showed postprandial hyperinsulinemic hypoglycemia during the OGTT after the glucose loading.

NIPHS as a cause of postprandial hyperinsulinemic hypoglycemia was firstly recognized by Service et al in 1999.<sup>2</sup> After that, patients with postprandial hyperinsulinemic hypoglycemia during the OGTT and a negative fast test were suspected of suffering from NIPHS. Of worth to note are the

**Table 1:** Clinical characteristics of 20 patients with endogenous hyperinsulinemic hypoglycemia in whom an insulinoma was not detected during exploration

No.	Name	Surgical date	Age/Sex	Biochemical investigation OGTT	Fast test	Preoperative localization studies	Preoperative diagnosis	Operative procedure	Postoperative diagnosis	Reoperation
1	KE	1987.03	49/F	+	+	US-, CT-	Insulinoma	Blind distal resection + enucleation	Insulinoma (head, 15 mm)	None
2	TF	1992.10	76/F	+	+	US-, CT-	Insulinoma	Blind distal resection + enucleation	Insulinoma (head, 13 mm)	None
3	SB	1994.02	18/M	None	+	US-, CT-, EUS-, angiography-	Insulinoma	Tissue sampling	NIPHS	Left resection (90%)(1 m)
4	LH	1996.08	57/M	+	+	US-, CT-, MRI-, angiography-	Insulinoma	Tail resection	NIPHS	None
5	BE	1998.03	30/F	None	+	US-, CT-, EUS⊕, MRI-	Insulinoma	Tail resection	NIPHS	Left resection (70-80%) (1/2y)
6	OH	1999.09	46/M	+	+	US-, CT-, EUS⊕	Insulinoma	Blind distal resection	Insulinoma (tail, 10 mm)	None
7	SS	2001.10	34/F	-	+	US-, CT⊕, EUS⊕, MRI⊕	Insulinoma	Left resection (70-80%)	NIPHS	None
8	BM	2002.03	43/F	+	+	US-, EUS-	Insulinoma	Left resection (70-80%)	NIPHS	None
9	BC	2002.04	66/F	None	+	US-, CT-, EUS-, MRI-, SRS-	Insulinoma	Sampling + intra-op ASVS	NIPHS	Whipple procedure (1 m)
10	RA	2003.10	45/F	+	None	US-, CT⊕, EUS⊕, SRS-	NIPHS	Left resection (70-80%)	NIPHS	None
11	FR	2004.03	41/F	+	+	CT-	NIPHS	Left resection (70-80%)	NIPHS	None
12	BB	2004.05	45/F	+	-	ASVS+	NIPHS	Left resection (70-80%)	NIPHS	None
13	BM	2004.10	41/F	+	+	CT-	NIPHS	Left resection (70-80%)	NIPHS	None
14	RS	2005.04	29/F	+	-	ASVS+	NIPHS	Whipple procedure	NIPHS	Resection (90%) (1y)
15	SK	2005.11	74/F	+	-	CT-, EUS⊕, SRS-	NIPHS	Left resection (70-80%)	NIPHS	None
16	SA	2005.12	35/F	+	-	US-, MRI-, ASVS+	NIPHS	Left resection (70-80%)	NIPHS	None
17	JI	2006.06	40/F	+	-	CT-, EUS-, ASVS+	NIPHS	Left resection (70-80%)	NIPHS	None
18	HM	2006.10	42/F	+	+	US-, CT-, EUS-	Insulinoma	Left resection (70-80%)	Insulinoma (Head, 19 mm)	Enucleation (3 m)
19	KK	2007.07	53/M	+	-	EUS-, ASVS+	NIPHS	Left resection (70-80%)	NIPHS	None
20	BU	2009.06	52/F	+	+	CT-, EUS+, MRI-	Insulinoma	Tail resection (20-30%)	NIPHS	None

+, positive; -, negative; ⊕, false positive; US, Transabdominal ultrasonography; CT, Computed tomography; MRI, Magnetic resonance image; EUS, Endoscopic ultrasonography; SRS, Somatostatin receptor scintigraphy; ASVS, Selective arterial calcium stimulation and venous sampling; NIPHS, Noninsulinoma pancreatogenous hypoglycemia syndrome.

patients #11, and 13 with a positive fast test. In spite of the positive fast test, these two patients were categorized to NIPHS because their serum insulin level at fasting hypoglycemia is only mildly elevated (3.2 mU/l); just slightly higher than the upper limit of a normal and adequately suppressed serum insulin level (3.0 mU/l).

The 72 hours fast was not completed in patient #10 because of neuroglycopenia-induced hemiparesis 4 hours after glucose loading that initiated the fast.

### Preoperative Localization Study

The results of preoperative localization studies of these 20 patients are summarized in Table 1. In 4 patients proven to have insulinoma (#1, 2, 6, and 18), the available preoperative localization techniques including transabdominal ultrasound (US), computed tomography (CT), and endoscopic ultrasound (EUS) all failed to detect and localize that insulinoma. Furthermore, EUS of one patient (#6) showed a false lesion in the body of pancreas which was not reproducible during exploration. On the other hand, in patients proven to have NIPHS, 2 of 11 CT scan, 5 of 10 EUS, and 1 of 6 MRI demonstrated false positive pancreatic abnormalities which were interpreted preoperatively as a single insulinoma. These results appeared that the preoperative localization techniques have limited role in differentiation between insulinoma and NIPHS, and may confuse and mislead surgeons rather than clarify the individual situation.

### Selective Arterial Calcium Stimulation with Hepatic Venous Sampling (ASVS)

When NIPHS was suspected based on the data of biochemical examination, we proceed to preoperative selective arterial calcium stimulation with blood sampling from the right hepatic vein as originally described by Doppman et al.<sup>7</sup> There were five patients (#12, 14, 16, 17, and 19) with a presumptive preoperative diagnosis of NIPHS receiving this examination. Another patient (#9) received an intraoperative selective arterial calcium stimulation test at an outside hospital while no insulinoma was found during this first operation. All the selective arterial calcium stimulation tests detected the dysfunctional regions of pancreas (2 in the head and 4 in the tail, sensitivity 100%). The results of selective arterial calcium stimulation clearly guided the exact extent of pancreatic resection in patients with NIPHS.

### Surgery

Patients #1, and 2 had blind distal pancreatectomy initially after palpation and intraoperative ultrasound results failed to demonstrate an insulinoma. No circumscribed tumor was identified in the resected specimens, so a more thorough examination was repeated again with the special focus of attention on the head of the pancreas, after the entire pancreas being mobilized and exposed. Finally, the insulinoma was found in the head of the pancreas and was enucleated successfully.

Patient #6 had no detectable mass by palpation and intraoperative ultrasound during exploration although the entire pancreas was mobilized and examined. However, the head of pancreas was soft whereas the body and tail were firm and nodular which may obscure a lesion within these regions by making it neither palpable nor detectable by intraoperative ultrasound. A distal pancreatectomy was performed accordingly. Within the tail of the pancreas an insulinoma measured of 10 mm in diameter was successfully identified by pathological examination.

Patients #3 and 9 with a preoperative presumed insulinoma received only pancreatic tail sampling while no detectable insulinoma by palpation and intraoperative ultrasound at an outside hospital. The pathological examination of the resected tissues was consistent with nesidioblastosis. These two patients were then referred to our hospital and a gradient-guided pancreatic resection was performed thereafter.

Patient #4, 5, 7, 8 and 20 underwent an exploratory laparotomy for a presumed insulinoma. The entire pancreas was mobilized, palpated, and surgically explored, and no pancreatic masses were palpable. An intraoperative ultrasound demonstrated a homogenous pancreas without any abnormality suggestive of an insulinoma. In patient 20, however, the tail of the pancreas was firmer than the rest of the organ, suspecting a possible pathologic feature in the tail. We reassessed the data of biochemical examination and these data characterized these patients as cases of NIPHS or insulinoma (#20). On frozen section examination, a biopsy specimen from the tail of the pancreas was consistent with diffuse islet cell hyperplasia. Suspecting NIPHS, a limited tail or 70-80% left pancreatectomy was performed. Pathologically, the resected pancreas all showed diffuse nesidioblastosis and prominent islet hyperplasia as well as features of insulinomatosis (Figs 1A to D). No insulinoma was found grossly or microscopically. Patient #5 had a secondary operation which removed 70-80% of her pancreatic tissue 6 months later due to the recurrent episodes of neuroglycopenia following an initial limited tail resection.

Patient #10-17, and 19 underwent an operation with the preoperative diagnosis of NIPHS. In good accordance with the diagnosis, there was no detectable mass in the pancreas of patients after a thorough examination by palpation and intraoperative ultrasound. A 70-80% left pancreatectomy or Whipple procedure, guided by the results of preoperative selective arterial calcium stimulation, was performed. All of the patients were relieved of further neuroglycopenic attacks postoperatively. Only one patient (#14) experienced recurrences of hypoglycemic symptoms one year after the operation. This patient was treated again by a repeated pancreatic resection.

Patient #18 underwent an exploratory laparotomy for a presumed insulinoma. The entire pancreas was mobilized, palpated, and surgically explored, and no circumscribed mass was palpable. An intraoperative ultrasound also failed to identify any lesion suggestive of an insulinoma. With our increasing experience on the operative management of NIPHS, we assumed



this patient a case of NIPHS although the data of biochemical examination performed at an outside hospital clearly pointed toward an insulinoma. This surmise was assured when we excluded one or multiple pancreatic tumors by careful palpation and intraoperative ultrasound. Suspecting NIPHS, a left pancreatectomy was performed. Surprisingly, the neuroglycopenic episodes were not ameliorated after the operation. Postoperative reevaluation with repeated EUS finally demonstrated a 2 cm hypoechoic tumor in the uncinate process of the pancreas. This overlooked insulinoma was enucleated successfully during the secondary operation three months later.

### Pathological and Immunohistochemical Examinations

An insulinoma was confirmed by pathological and immunohistochemical examinations in the resected tissues derived from patients #1, 2, 6, and 18 (Figs 1E and F). On the other hand, there was no grossly visible or microscopic tumor identified in any of the resected specimens derived from the 16 NIPHS patients on hematoxylin- and eosin-stained sections. In each of the 16 patients with NIPHS, histological examination revealed budding of the islets from the wall of ductules, apposition of islets to ducts, and increased number and size of islets, consistent with nesidioblastosis. In patient #20 all features of insulinomatosis of the pancreatic tail were present.

In addition, the pathologic lesions appeared to be evenly distributed in some resected pancreatic tissues and more locally clustered in others.

### COMPLICATIONS

There was no mortality in these 19 patients. Postoperative complications included one delayed intra-abdominal abscess, 5 weeks after discharge from hospital, which was drained surgically (patient #3). Patient #8 was also complicated by intra-abdominal abscess which was successfully treated by antibiotics. The other two patients (#11 and 12) experienced a pancreatico-cutaneous fistula which dried off after three and six weeks of conservative treatment, respectively.

Patient #18 had complications of postoperative internal bleeding and hypovolemic shock, which necessitated a reopen surgery to check bleeding on the next day. Hematological examination of this patient discovered a factor XIII deficiency, which was treated by blood transfusion and the postoperative course was uneventful, thereafter.

### POSTOPERATIVE FUNCTIONAL STATUS

The four patients with insulinoma were all cured after removal of the tumor. Of 13 NIPHS patients receiving a 70-80% pancreatectomy, 12 (92%) remain normoglycemic and free of neuroglycopenic episodes. This was also true for the one patient with insulinomatosis (#20) and resection of only the pancreatic tail. Of these 14 patients with pancreatic tail, and 70-80% resection only one patient developed insulin-dependent

diabetes mellitus (#8). The two NIPHS patients with removal of more than 90% of their pancreas both developed diabetes mellitus (#3 and 14).

None our 20 patients reported further episodes of neuroglycopenia after a mean follow-up of 77 months.

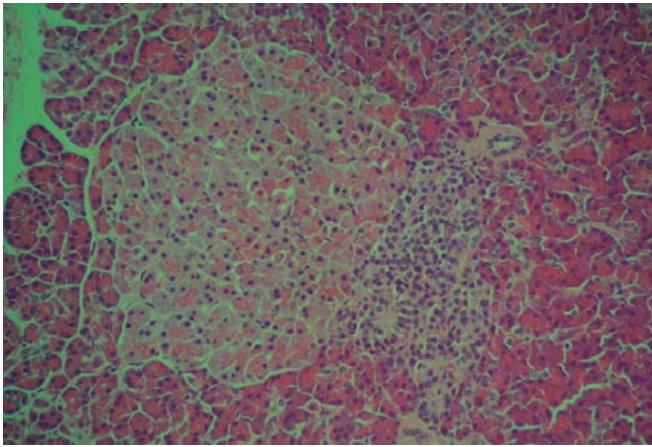
### DISCUSSION

Endogenous hyperinsulinemic hypoglycemia in adults is almost always caused by insulinomas, only rarely by noninsulinoma pancreatogenous hypoglycemic syndrome (NIPHS), a unique hypoglycemic disorder which was firstly characterized by Service and colleagues in 1999.<sup>2</sup> The clinical characteristics of this syndrome are postprandial hyperinsulinemic hypoglycemia, negative 72-hours fast, negative perioperative localization studies for insulinomas, but a positive selective arterial calcium stimulation test. No patient was found to have an insulinoma and histopathological examination disclosed the presence of islet hypertrophy and nesidioblastosis.<sup>8</sup> The incidence of NIPHS in adult hyperinsulinemic hypoglycemia is not well known but has been estimated to be 0.5% to 5.0% in large published series.<sup>9</sup> NIPHS occurred in 12.4% of patients who underwent operation for hyperinsulinemic hypoglycemia at our institution during the last two decades. This suggests that NIPHS accounts for a substantial fraction of patients with endogenous hyperinsulinemic hypoglycemia and may be more common than has been thought.<sup>10</sup>

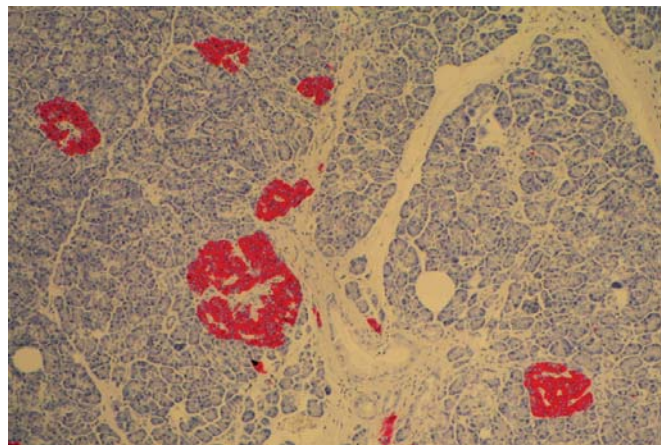
All of our 15 NIPHS patients fit the diagnostic criteria for NIPHS. All patients had onset of symptoms in adulthood. The duration of hypoglycemic symptoms was variable, ranging from two weeks to twenty years. OGTT and/or fast test confirmed the diagnosis of endogenous hyperinsulinemic hypoglycemia. Gross examination and step-sectioning techniques excluded the presence of an insulinoma in the specimens. In addition, the probability of an occult insulinoma being overlooked intraoperatively and thus remaining *in situ* is very unlikely because of the obvious postoperative increase in plasma glucose levels and palliation of symptoms.

When NIPHS is suspected before operation, we proceed to selective arterial calcium stimulation to regionalize the dysfunctional pancreatic portions. This test not only proves  $\beta$ -cell dysregulation, since the test is negative in a normal pancreas, but also differentiates between the hypersecretory portions of the head, body, and tail of the pancreas.<sup>11</sup> The results of selective arterial calcium stimulation test thus provide the guide to the extent of pancreatectomy.<sup>12</sup>

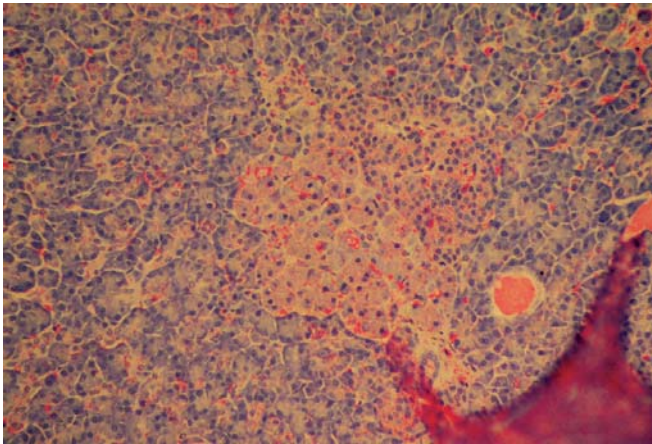
It is not surprising that the preoperative differentiation between NIPHS and insulinomas is quite difficult because of their similar presentations in biochemistry and image studies. The 10 patients with NIPHS reported by Thompson et al are characterized by postprandial hyperinsulinemic hypoglycemia and a negative fast test.<sup>8</sup> However, eight of our 15 NIPHS patients have hyperinsulinemic hypoglycemia not only during postprandial period but also during a fast test. Witteles et al also reported five cases of adult-onset nesidioblastosis whose



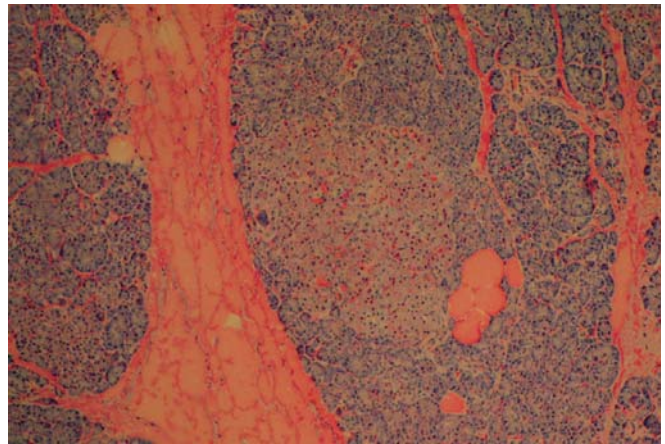
**Fig. 1A:** High power amplification in hematoxylin eosin stain



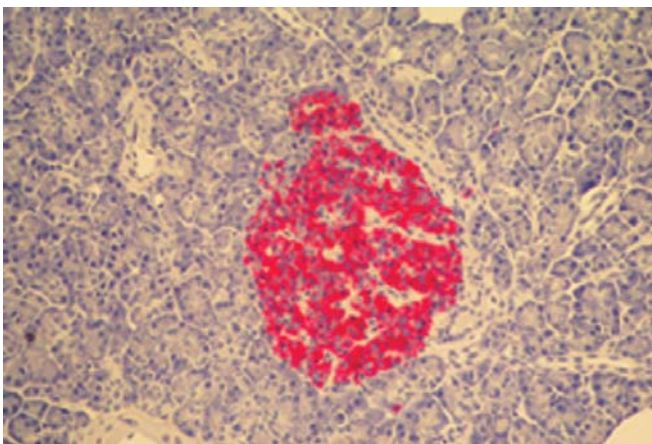
**Fig. 1B:** Normal and enlarged islets with immunohistochemical reaction to insulin



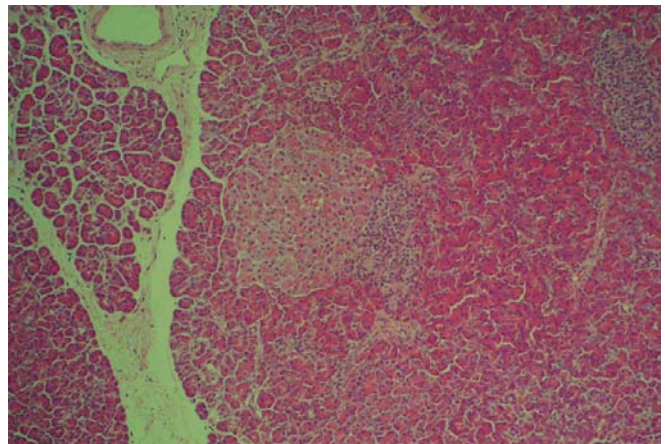
**Fig. 1C:** High enlargement of a pathologic islet with hematoxylin eosin stain



**Fig. 1D:** Pathologic islet with hematoxylin eosin stain



**Fig. 1E:** With immunohistochemical reaction to insulin



**Fig. 1F:** In hematoxylin eosin stain

**Figs 1A to F:** Pathologic and enlarged islets of Langerhans in an pancreas of a patients with NIPHS



hypoglycemic episodes occurred during fast or exercise, just as typical for patients with insulinoma.<sup>13</sup> As a result, a sole fast test does not seem to be a good discriminator between these two patient groups. Conventional image techniques are not a reliable tool, neither. As shown by this study, the available image studies including transabdominal ultrasonography, computed tomography, and endoscopic ultrasound all failed to detect the insulinoma. On the other hand, the image studies falsely demonstrated a pancreatic abnormality which was interpreted as a single insulinoma preoperatively in 4 of our 15 NIPHS patients (false positive rate, 26.7%). Most authors consequently think it impossible to differentiate NIPHS from insulinoma preoperatively.<sup>14, 15</sup>

Recently, we reported for the first time the characteristic blood glucose and serum insulin patterns obtained from a combined OGTT and standard fast test in patients with NIPHS that enabled us to predict or at least speculate NIPHS preoperatively.<sup>5</sup> The patients with NIPHS tend to have postprandial hypoglycemia which was rarely seen in patients with insulinoma. The serum insulin level during fasting hypoglycemia is only mildly elevated ( $6.8 \pm 5.4$  mU/l) and close to the upper limit of a normal and adequately suppressed serum insulin level (3.0 mU/l) in majority of patients with NIPHS, in contrast to apparently elevated serum insulin levels in most patients with insulinoma ( $29.0 \pm 26.9$  mU/l). We also found that most patients with NIPHS were able to efficiently counter-regulate their postprandial hypoglycemia back to normal glucose levels. This phenomenon was untypical for patients with insulinoma, who frequently suffer from seizures due to severe hypoglycemia and more pronounced hyperinsulinemia. These specific clinical and biochemical findings thus might point toward a diagnosis of NIPHS preoperatively rather than a pathohistological diagnosis.

Although the intraoperative ultrasound has facilitated the detection of insulinoma, the problem of overlooked tumor is still encountered, ranging from 10 to 27% of insulinomas in several series.<sup>1</sup> In contrast to previous practices, progressive blind distal pancreatectomy is no longer recommended.<sup>16</sup> As consistent with our experience, insulinomas not detected during exploration are probably not located at the tail but instead reside in the thicker, more complicated anatomic region of the pancreatic head.<sup>17</sup> Progressive blind distal resection is consequently not a logical approach. If no circumscribed tumor is found, it is our recommendation to reassess the data of biochemical examination punctiliously. If the data clearly point toward an insulinoma, the pancreas should be completely mobilized and exposed with meticulous bidigital palpation followed by intraoperative ultrasound, with the special focus of attention on the head and uncinate process of pancreas. The success rate in identification of insulinoma using this approach in 106 cases at our institution is 99%. If still no insulinoma is detected, the current consensus recommends termination of operation and repeated evaluation of patient.<sup>18</sup>

When NIPHS was favored after re-examining the data of biochemical examination, the extent of pancreatectomy should be gradient-guided based on the results of selective arterial calcium stimulation test. Although the precise mechanism responsible for hyperinsulinemic hypoglycemia in NIPHS is not well understood, it seems to be nonfocal or diffuse. The 10 NIPHS patients reported by Won and colleagues all had an insulin gradient after calcium injection in the splenic artery as well as in the superior mesenteric artery and/or gastroduodenal artery, indicating the  $\beta$ -cell hyperfunction throughout the entire pancreas.<sup>19</sup> These patients were all relieved of their symptoms by a gradient-guided partial or subtotal pancreatectomy, even in patients whose disease appeared to involve the entire pancreas. These results are consistent with ours. Thus, a 70-80% gradient-guided pancreatectomy seems to be a feasible option for the treatment of NIPHS with a lower rate of postoperative insulin-dependent diabetes mellitus that is frequently seen after 90% or 95% (near-total) pancreatic resection. For patients with an insulin gradient confined to the splenic artery distribution, a distal resection to the left of superior mesenteric vein is recommended.<sup>6</sup> If an insulin gradient is found after calcium injection in the gastroduodenal and/or superior mesenteric artery, as in our patients # 9 and 14, a pancreaticoduodenectomy is carried out.

Patient #18 had an occult insulinoma in the uncinate process of pancreas. This tumor was overlooked during the first operation, but was found by repeated EUS postoperatively. It was successfully removed during the secondary operation three months later. This case reminds us that even in experienced hand an insulinoma may still be missed. As a result, surgeons must be very cautious with considering NIPHS if the data of biochemical examination does not clearly suggest of NIPHS.

## CONCLUSION

When an insulinoma is not detected during exploration, our recommendation is to reassess the data of biochemical examination. When the data clearly point to an insulinoma, a thorough search with the special focus of attention on the head and uncinate process of pancreas should be performed. If still no tumor is found, the operation should be terminated. When NIPHS as an uncommon but important etiology of hyperinsulinemic hypoglycemia is considered after reassessing the data of biochemical examination, a 70-80% gradient-guided pancreatectomy based on the results of selective arterial calcium stimulation test is the treatment of choice.

## REFERENCES

1. Grant CS. Surgical aspects of hyperinsulinemic hypoglycemia. *Endocrinol Metab Clin North Am* Sep 1999;28(3):533-54.
2. Service FJ, Natt N, Thompson GB, Grant CS, van Heerden JA, Andrews JC, et al. Noninsulinoma pancreatogenous hypoglycemia: A novel syndrome of hyperinsulinemic hypoglycemia

- in adults independent of mutations in Kir 6.2 and SUR1 genes. *J Clin Endocrinol Metab* 1999;84:1582-89.
3. Hellman P, Goretzki PE, Simon D, Dotzenrath C, Roeher HD. Therapeutic experience of 65 cases with organic hyperinsulinism. *Langenbecks Arch Chir* 2000;385:329-36.
  4. van Heerden JA, Grant CS, Czako PF, Service FJ, Charboneau JW. Occult functioning insulinomas: Which localizing studies are indicated? *Surgery* 1992;112:1010-14.
  5. Starke A, Saddig C, Kirch B, Tschahargane C, Goretzki PE. Islet hyperplasia in adults: Challenge to preoperatively diagnose non-insulinoma pancreatogenic hypoglycemia syndrome. *World J Surg* 2006;30:670-79.
  6. Kaczirek K, Niederle B. Nesidioblastosis: An old term and a new understanding. *World J Surg* 2004;28:1227-30.
  7. Doppman JL, Miller DL, Chang R, Gorden P, Eastman RC, Norton JA. Intra-arterial calcium stimulation test for detection of insulinomas. *World J Surg* 1993;17:439-43.
  8. Thompson GB, Service FJ, Andrews JC, Lloyd RV, Natt N, van Heerden JA, et al. Noninsulinoma pancreatogenous hypoglycemia syndrome: An update in 10 surgically treated patients. *Surgery* 2000;128:937-45.
  9. Jabri AL, Bayard C. Nesidioblastosis associated with hyperinsulinemic hypoglycemia in adults: Review of the literature. *Eur J Intern Med* 2004;15:407-10.
  10. Anlauf M, Wieben D, Perren A, Sipos B, Komminoth P, et al. Persistent hyperinsulinemic hypoglycemia in 15 adults with diffuse nesidioblastosis. *Am J Surg Pathol* 2005;29:524-33.
  11. Tsujino M, Sugiyama T, Nishida K, Takada Y, Takanishi K, Ishizawa M, et al. Noninsulinoma pancreatogenous hypoglycemia syndrome: A rare case of adult-onset nesidioblastosis. *Intern Med* 2005;44:843-47.
  12. Doppman JL, Chang R, Fraker DL, Norton JA, Alexander HR, Miller DL, et al. Localization of insulinomas to regions of the pancreas by intra-arterial stimulation with calcium. *Ann Intern Med* 1995;123:269-73.
  13. Witteles RM, Straus II FH, Sugg SL, Koka MR, Costa EA, Kaplan EL. Adult-onset nesidioblastosis causing hypoglycemia: An important clinical entity and continuing treatment dilemma. *Arch Surg* 2001;136:656-63.
  14. Kaczirek K, Soleiman A, Schindl M, Passler C, Scheuba C, Prager G, et al. Nesidioblastosis in adults: A challenging cause of organic hyperinsulinism. *Eur J Clin Invest* 2003;33:488-92.
  15. Bottger T. Surgical treatment and outcome in insulinoma. *Zentralbl Chir* 2001;126:273-78.
  16. Hirshberg B, Libutti SK, Alexander HR, Bartlett DL, Cochran C, Livi A, et al. Blind distal pancreatectomy for occult insulinoma, an inadvisable procedure. *J Am Coll Surg* 2002;194:761-64.
  17. Dolan JP, Norton JA. Occult insulinoma. *Br J Surg* 2000;87:385-87.
  18. Tucker ON, Crotty PL, Conlon KC. The management of insulinoma. *Br J Surg* 2006;93:264-75.
  19. Won JG, Tseng HS, Yang AH, Tang KT, Jap TS, Lee CH, et al. Clinical features and morphological characterization of 10 patients with noninsulinoma pancreatogenous hypoglycaemia syndrome (NIPHS). *Clin Endocrinol* 2006;65:566-78.