CASE REPORT

Jaw Tumor: An Uncommon Presenting Manifestation of Primary Hyperparathyroidism

[1]Roy Phitayakorn, [2]Christopher R McHenry

[1]Department of Surgery, Massachusetts General Hospital, Harvard Medical School, Boston, MA

[2]Department of Surgery, MetroHealth Medical Center, Case Western Reserve University, Cleveland, OH

Correspondence: Roy Phitayakorn, Department of Surgery, Massachusetts General Hospital, WACC 460 E, 15 Parkman Street, Boston, MA 02114, USA, Phone: (617) 643-0544, Fax: (617) 724-2574, e-mail: rphitayakorn@partners.org

Abstract

Introduction: To report two unusual cases of primary hyperparathyroidism (HPT) that initially manifested with a " jaw tumor" and to discuss the clinical implications of a giant cell granuloma *vs* an ossifying fibroma of the jaw.

Material and methods: The history, physical examination, laboratory values and the imaging and pathologic findings are described in two patients who presented with a "jaw tumor" and were subsequently diagnosed with primary HPT. The diagnosis and management of osteitis fibrosa cystica and HPT-jaw tumor syndrome are reviewed.

Results: Patient #1 was a 70-year-old male who presented with hypercalcemia, severe jaw pain, and an enlarging mass in his mandible. Biopsy of the mass revealed a giant cell tumor and he was subsequently diagnosed with primary HPT. A sestamibi scan demonstrated a single focus of abnormal radiotracer accumulation, corresponding to a 13,470 mg parathyroid adenoma, which was resected. Postoperatively, the serum calcium normalized and the giant cell granuloma regressed spontaneously.

Patient #2 was a 36-year-old male with four incidentally discovered tumors of the mandible and maxilla, who was diagnosed with normocalcemic HPT and vitamin D deficiency. Biopsy of one of the tumors revealed an ossifying fibroma. Bilateral neck exploration revealed a 2480 mg right inferior parathyroid adenoma, which was resected. Postoperative genetic testing revealed an HRPT2 gene mutation. He subsequently underwent resection of an enlarging ossifying fibroma of the mandible with secondary reconstruction.

Conclusions: A "jaw tumor" in a patient with primary HPT may be a manifestation of osteitis fibrosa cystica or HPT-jaw tumor syndrome underscoring the importance of biopsy and genetic testing for management and follow-up.

Keywords: Hyperparathyroidism, jaw tumor syndrome, giant cell granuloma, ossifying fibroma.

INTRODUCTION

Prior to the introduction of the autoanalyzer for measurement of serum calcium, approximately 80% of patients with primary hyperparathyroidism (HPT) presented with severe manifestations of osteitis fibrosa cystica including: severe bowing of the limbs, pathologic bone fractures, significant decrease in height secondary to kyphosis, and jaw and other bone tumors.[1] These bone tumors, referred to as brown tumors or giant cell granulomas, are caused by accelerated osteoclastic and suppressed osteoblastic activity secondary to elevated parathyroid hormone levels. Since the introduction of the autoanalyzer, severe bone disease has become an uncommon manifestation of primary HPT. When patients present with bone manifestations, it is usually osteopenia and/or osteoporosis of the long bones or pelvis and subperiosteal resorption in the middle phalanges.[2]

Patients with the HPT-jaw tumor syndrome may present with bony tumors in the mandible or maxilla. The major features of this syndrome include primary HPT (~90%) that may develop in adolescence or older-aged patients, ossifying fibromas of the mandible and maxilla (~30%), renal lesions (~10%) including hamartomas, renal cysts or polycystic disease and Wilm's tumor, and rarely uterine lesions including adenosarcomas, adenofibromas, leiomyomas, adenomyosis, and endometrial hyperplasia.[3, 4] HPT-jaw tumor syndrome is caused by an inactivating mutation in the HRPT2 (Hereditary Parathyroidism Type 2) gene and is characterized by a high, but incomplete penetrance (~80%).[5,6] This gene, located on the long arm of chromosome 1 (1q31.2), consists of 17 exons and encodes for a 531-amino acid protein called parafibromin.[7] The exact function of this protein is unknown, but it is believed to be a tumor suppressor protein with proapoptotic functions.[8] Approximately 10% of adults with HPT-jaw tumor syndrome may be silent carriers.[9] HPT-jaw tumor syndrome is one of the autonomic-dominant inherited HPT syndromes that also include Multiple Endocrine Neoplasia (MEN) type 1, MEN type 2A, and familial isolated HPT. HPT-jaw tumor

syndrome is considered more aggressive than the other inherited forms of HPT in that patients have an earlier onset, more severe hypercalcemia, and a 10 to 15% incidence of parathyroid carcinoma.[7]

In this paper, two patients with primary HPT diagnosed as a result of a "jaw tumor" are described and the diagnosis and management of a brown tumor of osteitis fibrosa cystica versus an ossifying fibroma of HPT-jaw tumor syndrome are reviewed.

REPORT OF TWO CASES

A 70-year-old Ukrainian man presented to our institution in 1998 with severe left jaw pain and swelling of the left side of his face. He admitted to generalized bone and joint pain and fatigue. His past medical history was significant for nephrolithiasis. His physical examination was remarkable for a soft, tender mass of the left mandible that had been present for many years and edema of the left side of his face. Laboratory evaluation revealed a serum calcium level of 13.9 mg/dL (normal = 8.8 to 10.5 mg/dL), a serum phosphate level of 1.9 mg/dL (normal = 2.5 to 5.0 mg/dL), an intact parathyroid hormone level of 1128.0 pg/mL (normal = 11 to 72 pg/mL), a serum 25 OH-vitamin D level of 92 ng/mL (normal = 25 to 80 ng/mL), and an alkaline phosphatase level of 256 IU/L (normal = 40-200 IU/L). Computed tomographic imaging demonstrated a large mass in the patient's left mandible (Fig. 1). A biopsy of the mass revealed multinucleated giant cells consistent with a giant cell granuloma. A technetium-99m-sestamibi scan demonstrated a large focus of abnormal radiotracer accumulation posterior and inferior to the lower pole of the left lobe of the thyroid gland (Fig. 2). The patient underwent bilateral neck exploration and resection of a 13,470 mg left superior parathyroid adenoma. The remaining three parathyroid glands were identified and were normal-sized. The patient required postoperative oral calcium and vitamin supplementation for transient hypocalcemia. The final pathology demonstrated a 4.7 × 3.4 × 1.7 cm atypical parathyroid adenoma. The giant cell granuloma in the patient's left mandible regressed completely and the surrounding bone recalcified after parathyroidectomy. He remained normocalcemic over long-term follow-up. He eventually died eight years following parathyroidectomy and the cause of his death is unknown.

A 36-year-old healthy Caucasian male was incidentally found to have four large mandibular and maxillary tumors on a routine dental examination. A computed tomographic scan demonstrated four large areas of radiolucency and radiopacity involving the right and left mandible and maxilla (Fig. 3). The patient had no significant past medical or past surgical history. He admitted to nausea, fatigue, heartburn, polyuria, and polydipsia. He had a thirty pack-year smoking history and his family history was significant for his mother with hypothyroidism and a maternal aunt with hyperthyroidism. There was no family history of other endocrinopathies. His physical examination was remarkable

Fig. 1: Computed tomographic image of the mandible of Patient #1. The white arrow points to a brown tumor that is classic for osteitis fibrosa cystica in the patient's left mandible

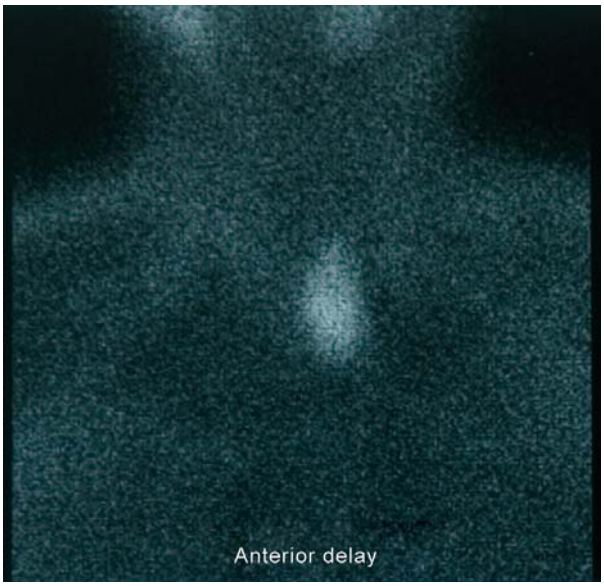

Fig. 2: 4-hour delayed anterior 99mTc-sestamibi image of Patient #1. The arrow indicates an abnormal focus of radiotracer accumulation posterior and inferior to the lower pole of the left lobe of the thyroid that corresponded to a left superior parathyroid adenoma

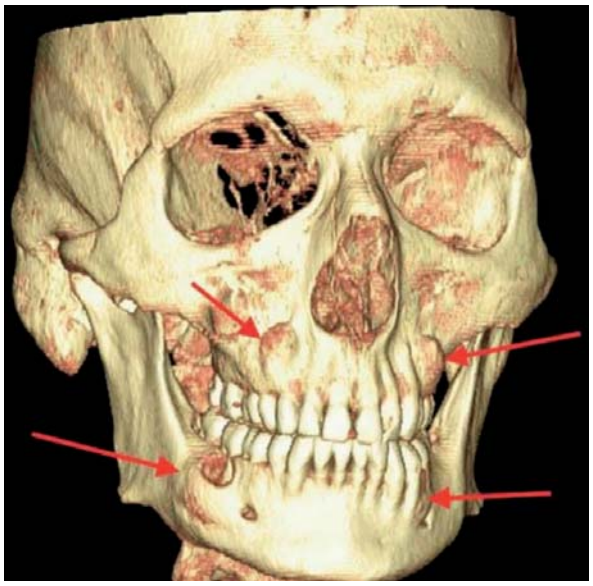

Fig. 3: A three-dimensional reconstruction of computed tomographic scans of Patient #2's mandible and maxilla. The arrows indicate four large areas of radiolucency and radiopacity involving the right and left mandible and maxilla

for multiple firm bony masses that were palpable in the maxilla and mandible bilaterally. He had no thyromegaly or palpable neck masses. Initial laboratory evaluation revealed: a serum calcium level of 9.2 mg/dL (normal = 8.4 to 10.4 mg/dL), an ionized calcium level of 1.23 mmol/L (normal = 1.10 to 1.40 mmol/L), a serum phosphate level of 2.3 mg/dL (normal = 2.5 to 4.8 mg/dL), an intact parathyroid hormone level of 177.9 pg/mL (normal = 12 to 72 pg/mL), a serum 25-OH vitamin D level of <7.0 ng/mL (normal = 10 to 60 ng/mL), and an alkaline phosphatase level of 72 IU/L (normal = 40 to 200 IU/L). The patient was started on 50,000 units of oral vitamin D therapy once a week for six weeks and then 800 units daily, thereafter. Following correction of his Vitamin D deficiency, a repeat parathyroid hormone level was 158.4 pg/mL. A biopsy of one of the jaw tumors demonstrated an ossifying fibroma. There were no multinucleated giant cells in the biopsy specimen. A technetium-99m-sestamibi scan demonstrated no foci of abnormal radiotracer accumulation. The patient underwent bilateral neck exploration and a 2480 mg right inferior parathyroid adenoma was resected. Intraoperative parathyroid hormone fell from 226.3 pg/mL immediately prior to excision to 26.0 pg/mL ten minutes after excision of the adenoma. Two of the three remaining glands were definitively identified and were normal in appearance. The final pathology demonstrated a 2.0 × 1.2/1.0 cm benign parathyroid adenoma. Postoperatively, the patient developed severe transient hypocalcemia that required oral calcium and vitamin supplementation. He underwent genetic testing and exons 1 to 7 of the HRPT2 gene were sequenced and were positive for the R9X mutation consistent with the clinical diagnosis of HPT-jaw-tumor syndrome.

Three months after parathyroidectomy, the patient developed increasing pain in his right mandible and difficulty chewing. A repeat computed tomographic scan demonstrated a sixty percent increase in tumor size of the right mandibular lesion and no change in size of the other tumors. As a result, the patient underwent resection of the right mandibular lesion with secondary reconstruction using an iliac bone graft. Final pathology was significant for variable stroma of mature fibroblasts and multiple areas of trabecular bone with ostoblastic rimming. The patient remains normocalcemic after three years of follow-up.

DISCUSSION

Brown tumors in patients with osteitis fibrosa cystica and ossifying fibromas in patients with HPT-jaw tumor syndrome manifest as a soft-tissue mass involving the maxillofacial bones. The management of these tumors can be very different as illustrated in our two case reports. Our first patient had a brown tumor isolated to his left mandible. The term "brown tumor" has been used to describe giant cell granulomas because of the characteristic reddish-brown color. These lesions are a manifestation of long-standing HPT with osteitis fibrosa cystica and are caused by prolonged excessive osteoclast and suppressed osteoblast activity due to elevated parathyroid hormone levels. An increased urinary excretion of hydroxyproline and loss of calcium into the surrounding extracellular spaces can also be demonstrated. Brown tumors can occur in any bone and are a cause of pathologic bone fractures.

Radiographically, osteitis fibrosa cystica appears as a constellation of cortical thinning of multiple bones, coarsened trabecular patterns, and mixed osteolytic and sclerotic bone that produces a salt-and-pepper appearance. Histopathologically, these tumors have a relatively vascular fibroblast-rich stroma with irregularly distributed clusters of characteristic osteoclastic giant cells.[10] Woven bone can also be seen with thin, bony trabeculae that are irregularly shaped, sized, and oriented.[11] Radiographically and histologically, brown tumors are identical to central giant cell granulomas.[12] The only distinguishing characteristic is the presence of hyperparathyroidism in patients with brown tumors. The first patient is somewhat unusual in that his primary manifestation of HPT was jaw pain. This patient

did not have a bone scan or other imaging, so it is unclear, if brown tumors were present elsewhere in other bones. Most importantly, the first case illustrates that following curative parathyroidectomy, brown tumors typically regress spontaneously over several years and no further treatment is necessary.

Our second patient also presented with jaw pain, but it was the result of an ossifying fibroma secondary to HPT-jaw tumor syndrome. The term "jaw tumor" is inaccurate as these tumors can develop in both the maxilla and mandible. Ossifying fibromas are part of a family of benign fibro-osseous lesions, which are all characterized by replacement of normal bone with a mixture of mineralized collagen and fibroblasts. Although the terminology used to describe benign fibro-osseous lesions can be confusing, there is a generally accepted classification scheme proposed by Waldron and then later modified by Brannon and Fowler (Table 1). Radiographically, ossifying fibromas are often well demarcated with smooth sclerotic borders.[13] Histopathologically, these tumors have a relatively avascular cellular fibroblast-rich stroma often with storiform pattern, mixed with retiform bone trabeculae with osteoblastic rimming, cementum-like spherules, and few or no giant cells.[14,15] Grossly, ossifying fibromas typically have a centrifugal growth pattern and easily "shells out" from the surrounding bone in either one or several large pieces. However, there is also a variant of ossifying fibroma that may demonstrate fusion of lesional bone with uninvolved nearby bone that may increase the difficulty of resection (Warnakulasuriya, Markwell, et al 1985). Interestingly, there have been several reports in the medical literature of patients with ossifying fibromas of the mandible or maxilla without evidence of HPT, which illustrates the incomplete genetic penetrance of this syndrome.[15] Ossifying fibromas typically involve only one side of either the mandible or maxilla. Multifocal progressive ossifying fibromas, such as in our second patient, are much less common.[5,16-18] Surgical resection should be considered for impaired function and disabling symptoms as in our second patient who was experiencing pain and difficulty chewing. Although ossifying fibromas are not malignant, surgical therapy should consist of a complete resection and bone reconstruction, when necessary, as tumor recurrence may occur with incomplete resection.[16,19-21]

Table 1: Classification of benign fibro-osseous lesions

I.	Osseous dysplasia
	Nonhereditary
	• Periapical
	• Focal
	• Florid
	Hereditary
	• Familial gigantiform cementoma
II.	Fibro-osseous neoplasms
	Ossifying fibroma
	Juvenile ossifying fibroma
III.	Fibrous dysplasia
	Polyostotic fibrous dysplasia with endocrinopathy (McCune–Albright form)
	Polyostotic fibrous dysplasia without endocrinopathy
	Craniofacial fibrous dysplasia

Used with permission from Brannon RB, Fowler CB. Benign fibro-osseous lesions: a review of current concepts. Adv Anat Pathol 2001;8:126-143.

The management of HPT-jaw tumor syndrome is controversial. At one time, HPT-jaw tumor syndrome was thought to be similar to other variants of familial HPT in terms of a higher incidence of multiglandular disease (45 to 75%) and persistent or recurrent hypercalcemia (20 to 50%).[22,23] As a result, operative strategies for HPT-jaw tumor syndrome consisted of subtotal parathyroidectomy or total parathyroidectomy with autotransplantation.[22,24] This aggressive approach resulted in a high incidence of permanent hypoparathyroidism (13 to 41%).[25] It has since been recognized that the patient populations from many early studies of familial HPT were comprised of clinically and genetically heterogeneous groups of individuals, many of whom had multiple endocrine neoplasia syndromes.[23] More recent studies, in patients with familial HPT and documented mutations in the HRPT2 gene, have found a predominance of single-gland disease (67 to 100%), and has led some investigators to recommend focused parathyroidectomy when supported by preoperative sestamibi and/or ultrasound imaging and intraoperative parathyroid hormone measurement.[25,26] Our patient with HPT-jaw tumor syndrome had a single large parathyroid adenoma that was the cause for his HPT. However, the negative preoperative sestamibi scan precluded a focused parathyroidectomy. Subsequent normalization of the calcium and parathyroid hormone levels postoperatively indicated definitive cure of his HPT. He has no evidence of recurrent HPT after three years of follow-up.

Patients suspected of having HPT-jaw tumor syndrome should undergo confirmatory genetic testing and should be encouraged to have their families undergo genetic testing as well. The parents, siblings and children of our second patient each have a 50% chance of carrying the HRPT2 gene mutation. The 10 to 15% risk of parathyroid cancer in

patients with HPT-jaw tumor syndrome highlights the importance of regular follow-up in patients who are positive for the HRPT2 gene mutation.[27] There is little published literature about what constitutes the optimal method or frequency of screening, but at minimum this should include an annual physical examination, serum calcium and parathyroid hormone measurement, and neck ultrasonography. The addition of routine ultrasonography is important as it can facilitate the diagnosis of recurrent disease in patients with HPT-jaw tumor syndrome while biochemical markers are still within the normal range.[28] It is important to recognize that HPT-jaw tumor syndrome is also associated with uterine and renal lesions.[3,4] Although there are no formal published screening guidelines for patients with HPT-jaw tumor syndrome, the possibility of malignant uterine or renal lesions has led some investigators to recommend annual transabdominal or transvaginal uterine ultrasonography and magnetic resonance imaging of the abdomen every five years.[3] More follow-up data will be needed to determine the true incidence of uterine and renal malignancy before formal guidelines can be created.

In summary, jaw tumors that occur as a result of osteitis fibrosa cystica or HPT-jaw tumor syndrome are an uncommon manifestation of primary HPT. The "jaw tumor" in patients with osteitis fibrosa cystica are giant cell granulomas that typically regress spontaneously. In contrast, the mandibular and/or maxillary lesions of the HPT-jaw tumor syndrome are ossifying fibromas that are unlikely to regress and should be resected when symptomatic or functionally disabling. Patients with HPT-jaw tumor syndrome can safely undergo focused parathyroidectomy, but must have close surveillance for the development of parathyroid carcinoma in the remaining parathyroid glands and periodic imaging for renal or uterine lesions due to the associated risk of renal cell carcinoma and uterine adenosarcoma.

REFERENCES

1. Strock M. Mouth in hyperparathyroidism. New England Journal of Medicine 1941;224:1019-23.
2. Rosen IB PJ. Fibroosseous tumors of the facial skeleton in association with primary hyperparathyroidism. Am J Surgery 1981;142:494-98.
3. Bradley KJ, Hobbs MR, Buley ID, et al. Uterine tumours are a phenotypic manifestation of the hyperparathyroidism-jaw tumour syndrome. J Intern Med 2005;257(1):18-26.
4. Teh BT, Farnebo F, Kristoffersson U, et al. Autosomal dominant primary hyperparathyroidism and jaw tumor syndrome associated with renal hamartomas and cystic kidney disease: Linkage to 1q21-q32 and loss of the wild type allele in renal hamartomas. J Clin Endocrinol Metab. 1996 Dec;81(12): 4204-11.
5. Jackson CE, Norum RA, Boyd SB, et al. Hereditary hyperparathyroidism and multiple ossifying jaw fibromas: A clinically and genetically distinct syndrome. Surgery 1990 Dec; 108(6):1006-12; discussion 12-13.
6. Carpten JD RC, Villablanca A, Forsberg L, et al. HRPT2, encoding parafibromin, is mutated in hyperparathyroidism-jaw tumor syndrome. Nature Genetics 2002 December;32(4):676-80.
7. Szabo J, Heath B, Hill VM, Jackson CE, Zarbo RJ, Mallette LE, et al. Hereditary hyperparathyroidism-jaw tumor syndrome: The endocrine tumor gene HRPT2 maps to chromosome 1q21-q31. Am J Hum Genet 1995Apr;56(4):944-50.
8. Lin L, Czapiga M, Nini L, et al. Nuclear localization of the parafibromin tumor suppressor protein implicated in the hyperparathyroidism-jaw tumor syndrome enhances its proapoptotic function. Mol Cancer Res 2007 Feb;5(2):183-93.
9. Simonds WF, James-Newton LA, Agarwal SK, et al. Familial isolated hyperparathyroidism: Clinical and genetic characteristics of 36 kindreds. Medicine (Baltimore). 2002 Jan;81(1):1-26.
10. Jowsey J. Bone histology and hyperparathyroidism. Clin Endocrinol Metab 1974;3:267.
11. Johnston J. Giant cell tumor of bone. The role of the giant cell in orthopedic pathology. Orthop Clin North Am 1977 Oct; 8(4):751-70.
12. Alawi F. Benign fibro-osseous diseases of the maxillofacial bones. A review and differential diagnosis. Am J Clin Pathol 2002 Dec;118 Suppl:S50-70.
13. Brannon RB, Fowler CB. Benign fibro-osseous lesions: A review of current concepts. Adv Anat Pathol 2001 May;8(3):126-43.
14. Sciubba JFJK, LB. Tumors and cysts of the jaw. Atlas of tumor pathology. Washington, DC: Armed Forces Institute of Pathology 2001.
15. Chen JD, Morrison C, Zhang C, et al. Hyperparathyroidism-jaw tumour syndrome. J Intern Med 2003 Jun;253(6):634-42.
16. Warnakulasuriya S, Markwell BD, Williams DM. Familial hyperparathyroidism associated with cementifying fibromas of the jaws in two siblings. Oral Surg Oral Med Oral Pathol 1985 Mar;59(3):269-74.
17. Inoue H, Miki H, Oshimo K, et al. Familial hyperparathyroidism associated with jaw fibroma: Case report and literature review. Clin Endocrinol (Oxf). 1995 Aug;43(2):225-9; discussion 30.
18. Cavaco BM, Barros L, Pannett AA, et al. The hyperparathyroidism-jaw tumour syndrome in a Portuguese kindred. QJM 2001 Apr;94(4):213-22.
19. Firat D, Stutzman L. Fibrous dysplasia of the bone. Review of twenty-four cases. Am J Med 1968 Mar;44(3):421-29.
20. Kennett S, Pollick H. Jaw lesions in familial hyperparathyroidism. Oral Surg Oral Med Oral Pathol 1971 Apr;31(4):502-10.
21. Dinnen JS, Greenwoood RH, Jones JH, et al. Parathyroid carcinoma in familial hyperparathyroidism. J Clin Pathol 1977 Oct;30(10):966-75.
22. Barry MK, van Heerden JA, Grant CS, et al. Is familial hyperparathyroidism a unique disease? Surgery 1997 Dec;122(6):1028-33.

23. Huang SM, Duh QY, Shaver J, et al. Familial hyperparathyroidism without multiple endocrine neoplasia. World J Surg 1997 Jan;21(1):22-8; discussion 9.
24. Marsden P, Anderson J, Doyle D, et al. Familial hyperparathyroidism. Br Med J 1971 Jul 10;3(5766):87-90.
25. Carneiro DM, Irvin GL (3rd), Inabnet WB. Limited versus radical parathyroidectomy in familial isolated primary hyperparathyroidism. Surgery 2002 Dec;132(6):1050-4; discussion 5.
26. Iacobone M, Barzon L, Porzionato A, et al. Parafibromin expression, single-gland involvement, and limited parathyroidectomy in familial isolated hyperparathyroidism. Surgery 2007 Dec;142(6):984-91; discussion -91.
27. DeLellis RA LR, Heitz PU, Heng C. World Health Organization classification of tumours pathology and genetics: Tumours of endocrine organs. . Lyon (France): IARC Press 2004.
28. Guarnieri V, Scillitani A, Muscarella LA, et al. Diagnosis of parathyroid tumors in familial isolated hyperparathyroidism with HRPT2 mutation: Implications for cancer surveillance. J Clin Endocrinol Metab 2006 Aug;91(8):2827-32.