

Tattooing as Alternative Therapy for Goiter

¹Tanmay Bharani, ¹Sagili Vijaya Bhaskar Reddy, ²Deependra Singh, ²Gyan Chand, ¹Sushil Kumar Gupta

¹Department of Endocrinology, Sanjay Gandhi Postgraduate Institute of Medical Sciences, Lucknow, Uttar Pradesh, India

²Endocrine Surgery, Sanjay Gandhi Postgraduate Institute of Medical Sciences, Lucknow, Uttar Pradesh, India

Correspondence: Sushil Kumar Gupta, Additional Professor, Department of Endocrinology, Sanjay Gandhi Postgraduate Institute of Medical Sciences, Lucknow-226014, Uttar Pradesh, India, Phone: +91-522-2494395, Fax: +91-522-2668017 e-mail: sushilgupta@saggi.ac.in, sushilguptasgpgi@gmail.com

Abstract

Goitre is an ancient art form being practiced world over for various reasons. We report a case where tattoo marking was used as a form of therapy for goitre. Tattoo therapy had failed to provide any benefit to the patient who later underwent total thyroidectomy with good post operative recovery

Keywords: Goiter, tattooing, tattoo therapy.

Goiter is known since time immemorial. Ancient Indian texts on Medicine and Surgery like “Sushrut Samhita” mention about various types of goiters and its treatment.¹

A tattoo is a marking made by inserting indelible ink into the dermis layer of the skin to change the pigment for decorative or other reasons. It comes from a Tahitian word “tatau” which means, “to make a mark”. It has been practised since ancient times for cosmetic, decorative, spiritual and identification purposes.² It has been termed as Abyssinian treatment of goiter which involves tattooing a string of beads around the neck.³

We report a male patient, 46 years of age, with long standing goiter and underwent tattooing as a part of therapy for reducing goiter size. The goiter had rapidly increased in size in last 6 months. Tattoo therapy had failed to provide any benefit to the patient. He recently developed stridor, loss of appetite and progressive weight loss.

Clinically the patient had large, firm goiter with restricted mobility (Fig. 1). Dilated vessels over upper thoracic region and lower abdomen suggested retrosternal extension with SVC syndrome (Fig. 2). No cervical lymph nodes were palpable. Biochemically he was euthyroid. Skiagram chest PA showed multiple reticulo-nodular opacities with occasional “cannon ball” lesions (Fig. 3). Contrast enhanced CT neck and upper thorax large heterogeneously enhancing gland with significant retrosternal extension and marked tracheal compression and compressing large vessels at base of neck (Fig. 4). Total thyroidectomy was performed and histopathology revealed papillary variant of follicular thyroid cancer. The patient recovered and discharged in satisfactory state.

This example gives a clue to the ignorance amongst general population regarding the gravity of the disease process and about their health seeking activities.

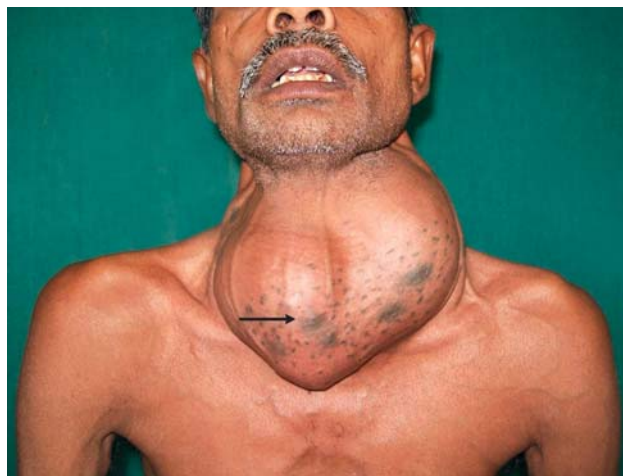

Fig. 1: Front profile of patient showing large goiter WHO grade 2 with multiple tattooing marks on goiter (arrow) and dilated veins at base of neck and upper chest

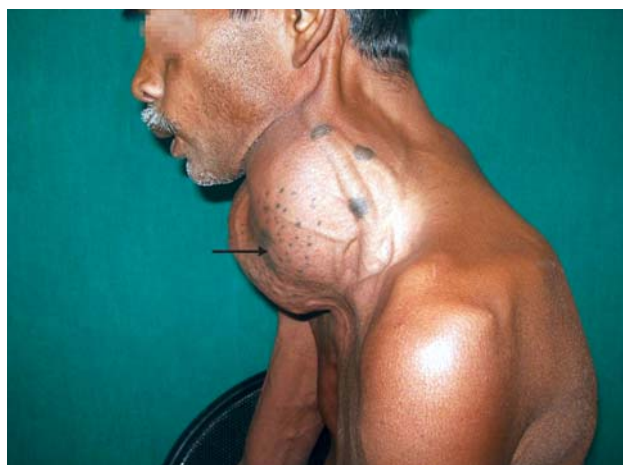

Fig. 2: Side profile of same patient (arrow showing tattoo marks)

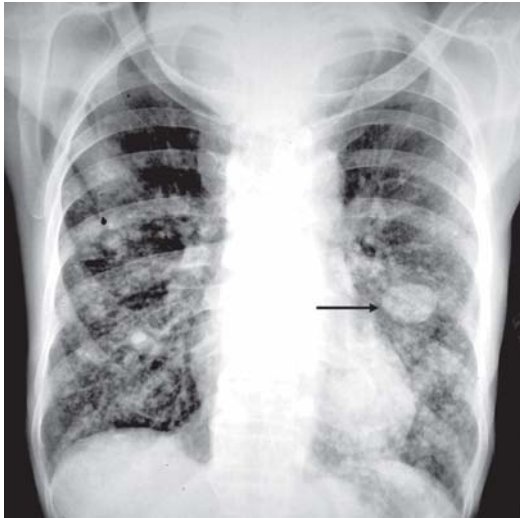


Fig. 3: Skiagram chest posterior anterior view showing diffuse nodular shadows with single large cannon ball metastasis (arrow) in lung fields

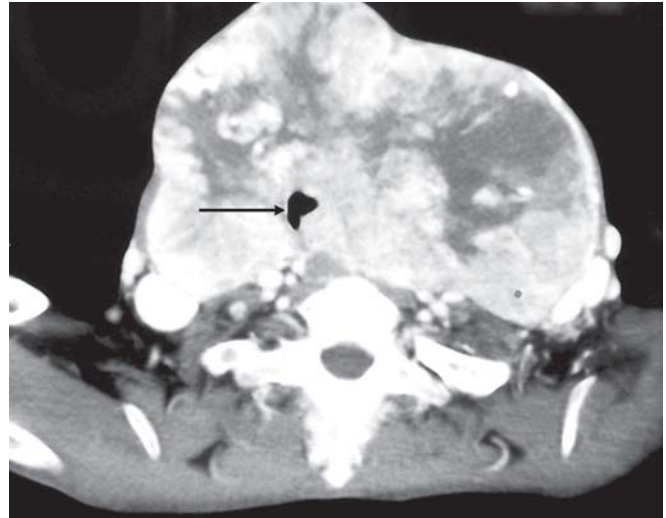


Fig. 4: Contrast enhanced computed tomogram of the neck shows large heterogeneously enhancing goiter with tracheal compression (arrow)

REFERENCES

1. Miles M Goitre. Cretinism and Iodine in South Asia: Historical Perspectives on a Continuing Scourge. *Medical History* 1998;42:47-67.
2. Wikipedia contributors, "Tattoo," Wikipedia, The Free encyclopedia, <http://en.wikipedia.org/w/index.php? Title = Tattoo & oldid = 357921898> (accessed April 26, 2010).
3. Greaves FLA. Remarks on nature and treatment of parenchymatous goitre. *BMJ* Feb 13, 1909;384-86.