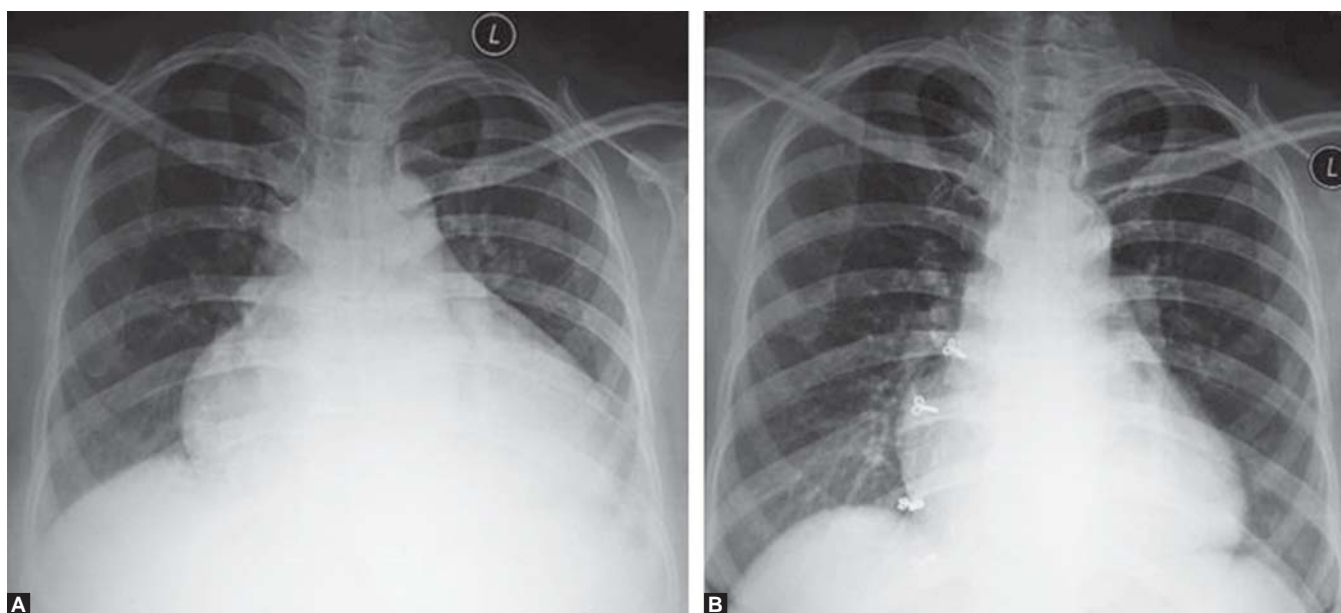


Reversion of Cardiomegaly and Cardiac Function in Hyperthyroidism

Pradeep PV, Jayashree B, Renu Kumar

Department of Endocrine Surgery, Narayana Medical College, Nellore, Andhra Pradesh, India

Correspondence: Pradeep PV, Department of Endocrine Surgery, Narayana Medical College, Nellore, Andhra Pradesh, India
e-mail: pradeepputhenveetil@gmail.com



Figs 1A and B: (A) The cardiomegaly before and (B) the reversal after treatment

We present a patient without primary heart disease in whom hyperthyroidism was accompanied by cardiomegaly with failure, which dramatically recovered after adequate treatment of hyperthyroidism. Figures 1A and B show the reversal of cardiomegaly after treatment.