

Intraoperative Monitoring of the Recurrent Laryngeal Nerve during Thyroidectomy: A Standardized Approach Part 2

Manuel C Durán Poveda, Gianlorenzo Dionigi, Antonio Sitges-Serra, Marcin Barczynski, Peter Angelos Henning Dralle, Eimear Phelan, Gregory Randolph

ABSTRACT

This is the second of two articles on intraoperative neural monitoring. The aim of part one was to provide a concise overview of intraoperative nerve monitoring in thyroid surgery and its effectiveness. Part 1 included a brief review of the surgical anatomy of the recurrent laryngeal nerve and described the surgical landmarks which can be used to identify the nerve during surgery. Part 2 will describe in detail a standardized approach to intraoperative nerve monitoring during thyroid surgery. A brief review of the nerve monitoring procedure and all its requirements will be discussed. The article concludes with the description of a troubleshooting algorithm for intraoperative loss of signal.

Keywords: Neuromonitoring, Anesthesia, Recurrent laryngeal nerve, Thyroid surgery.

How to cite this article: Poveda MCD, Dionigi G, Sitges-Serra A, Barczynski M, Angelos P, Dralle H, Phelan E, Randolph G. Intraoperative Monitoring of the Recurrent Laryngeal Nerve during Thyroidectomy: A Standardized Approach Part 2. *World J Endocr Surg* 2012;4(1):33-40.

Source of support: Nil

Conflict of interest: None declared

EQUIPMENT SET-UP, ANESTHESIA AND OPERATIVE TECHNIQUE

A standardized intraoperative nerve monitoring (IONM) technique will be described below.

Equipment Set-up

The Nerve Integrity Monitor (NIM-Response 3.0 System, Medtronic Xomed, Jacksonville, Florida) is the most widely used device for laryngeal nerve monitoring providing both audio and visual evoked waveform information when either the recurrent laryngeal or vagus nerve is stimulated. This nerve monitoring device transforms laryngeal muscle activity into audible and visual electromyographic (EMG) signals whenever the RLN or vagus nerve is stimulated intraoperatively (Fig. 1).

Since, the first contributions made in the field of nerve localization by Davies in 1979¹ and Goldstone in 1990,² many clinical advances have been made in the field of intraoperative nerve monitoring.^{3,4}

During IONM, a low pressure-cuffed silicone endotracheal tube (NIM Standard EMG Reinforced Tube, Medtronic Xomed) is used. This tube is similar to a standard

endotracheal tube but in addition, it has two integrated stainless steel contact electrodes on each side of the tube that monitor vocal cord EMG activity (Figs 2 and 3). It is imperative that these endotracheal surface electrodes make good contact with the luminal surface of the true vocal cords. Correct positioning of the endotracheal contact electrodes can be confirmed by direct laryngoscopy.

Following correct positioning of the endotracheal tube, the vocal cord electrodes and ground wires are

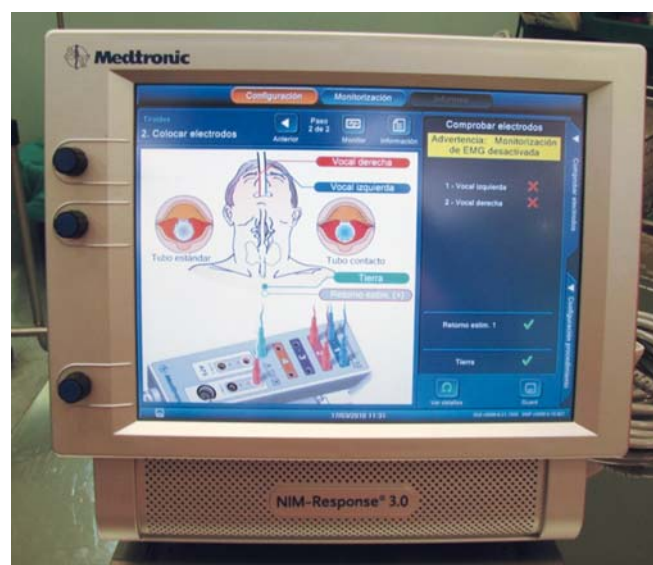

Fig. 1: Nerve integrity monitor (NIM-Response 3.0 System, Medtronic Xomed, Jacksonville, Florida) (Spanish configuration)

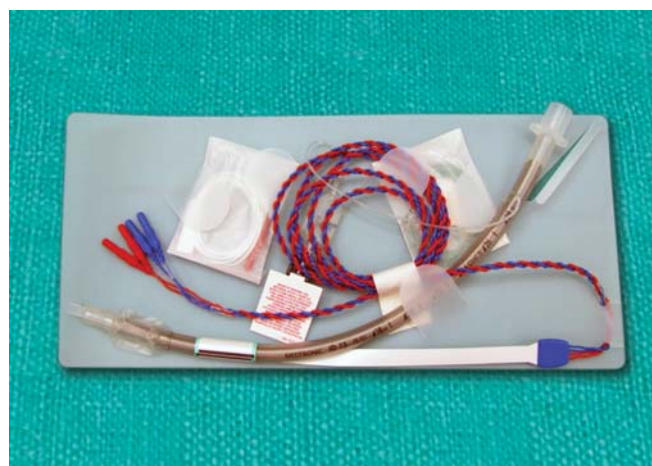


Fig. 2: Endotracheal tube (NIM standard EMG reinforced tube, Medtronic Xomed) with ground electrodes

connected to the NIM 3 monitor via a connector box. Both the recording electrodes and nerve stimulator probe require grounding electrodes (adhesive or subcutaneous) usually placed on the patient's shoulder closest to the monitor unit. Alternatively, grounding electrodes can be placed on the sternum region. The patient and electrical set-up of the endotracheal tube monitoring system is shown in Fig. 4.

The NIM 3 monitor has a pulse generator which is connected to the stimulating probe. Neural stimulation occurs via a sterile, handheld probe (Prass Standard Flush-Tip Probe, Medtronic Xomed). Stimulating probes can be monopolar or bipolar. The usefulness of both stimulating electrodes is well defined but there is no concluding data in the literature attesting the preference of one over the other so surgeon's choice is usually the norm. Monopolar stimulation can be very useful in mapping out the RLN because of a more diffuse current spread delivered in the

surgical field (occasionally associated with a false positive response) compared to bipolar stimulation where the stimulation is localized at the point of contact reducing false positive stimulation (Fig. 5). Randolph compared RLN stimulation with monopolar vs bipolar stimulation and did not find any striking differences between the two stimulating probes.⁴

Anesthesia

The anesthesiologist plays a key role in IONM, particularly with regard to the type of medications used to induce and maintain anesthesia and in the optimal placement of the endotracheal tube. It is of paramount importance to plan and discuss the role of monitoring with the anesthesiologist prior to the initiation of nerve monitoring and share all information related with the procedure as a prerequisite for the success of the event.

Nerve monitoring assesses laryngeal vocal cord EMG data through stimulation of vagal and RLN nerve. Neuromuscular blockade interferes with monitoring as it reduces the EMG amplitude and the optimal laryngeal response, making nerve monitoring less effective. Thus, after induction with a short acting neuromuscular blocking agent, neuromuscular blocking agents (NMBA) should be avoided for the rest of the case. Small doses of a nondepolarizing muscle relaxant (typically rocuronium and atracurium) are used at intubation as these agents allow normal return of basic physiological functions, such as spontaneous respiration and recovered muscle twitch activity within a few minutes. Other short-acting nondepolarizing paralytic agents (e.g. succinyl choline) can also be used in the initial phase of the general endotracheal

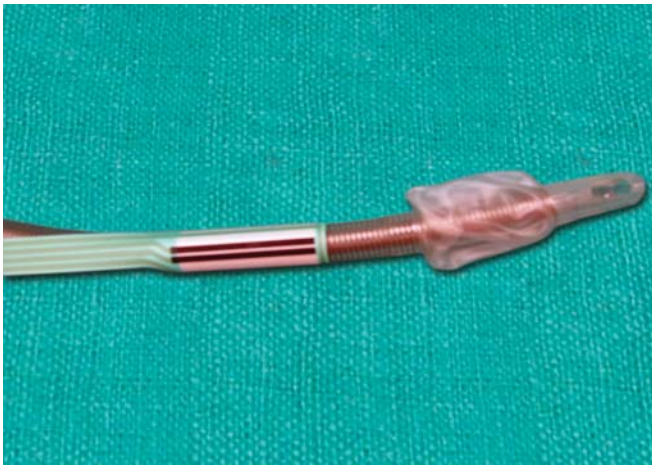

Fig. 3: Amplified image of the endotracheal tube with two integrated stainless steel contact electrodes on either side of the tube located above the endotracheal tubes cuff

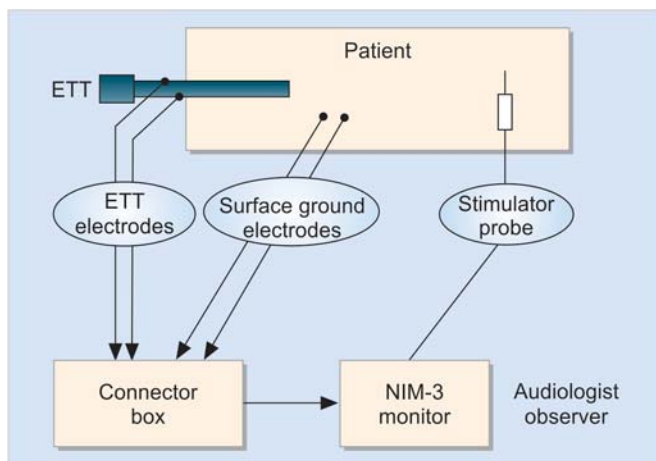


Fig. 4: IONM patient and equipment set-up. Reproduced and modified with permission from Randolph GW. Surgical anatomy of the recurrent laryngeal nerve (*Courtesy: Randolph GW (Ed). (Surgery of the thyroid and parathyroid glands. Philadelphia, PA: Saunders 2003)*




Fig. 5: Monopolar stimulator probe (Prass Standard Flush-Tip Probe, Medtronic Xomed)

anesthesia. The use of these agents allows for full relaxation and ease in intubation with good visualization and accurate tube placement.⁵

Muscle relaxation during surgery directly affects the larynx and reduces glottic motor response. Care should be taken with the use of any paralytic agents during a monitoring case (especially after induction) if one wants to have an appropriate EMG laryngeal response when stimulating the RLN.⁶ We recommend the use of a total intravenous anesthesia technique which includes propofol and opioids, such as remifentanyl, fentanyl or sufentanil following induction. Other agents including isoflurane and desflurane are also used. Of course, it is the discretion of the anesthesiologist, which esthetic agents he or she feels are clinically appropriate for the patient during a nerve monitoring case.

Operative Technique

Correct Monitoring Tube Placement

Intubation is done by the anesthesiologist in a normal fashion following the guidelines noted above. Monitoring EMG endotracheal tubes (ET) are available in sizes 6.0, 6.5, 7.0, 7.5 and 8.0. The patient should be intubated with an endotracheal tube that will facilitate good contact with the vocal cords which may be a size larger than normal. The ET tube is placed with the middle of the blue marked region (the exposed electrodes) well in contact with the true vocal cords under direct laryngoscopy. Typically, the optimal insertion depth of the ET tube coincides with the cuff positioned in the subglottis/upper trachea. This position ensures that the ET tube is in the normal position with the monitoring electrodes at the level of the vocal cords.⁴

Endotracheal tube placement errors include not only depth errors but also rotational errors. The degree of rotation (with respect to the right and left electrodes) or malposition of the endotracheal tube during intubation can lead to misleading information and is a potential cause of loss of signal during neural monitoring.

Occasionally, the ET tends to rotate during the intubation manoeuvre. This rotational error can be prevented by a counter-clockwise correction.³

In order to prevent rotation of the electrodes during intubation, a pen mark placed above the segment of exposed electrodes can help to prevent the rotation of the tube and guide in the optimal depth of the tube during intubation. Depth of ET tube insertion is measured from the right corner of the mouth to the tip of the tube before the tube is fixed.

Any depth or rotational errors should be corrected prior to commencing surgery and IONM.

Notes on Positioning the Patient and Tube Fixation

Once the patient is intubated, the patient's head and neck should change position from neutral to full extension. Special attention should be paid to hold the endotracheal tube in position. Changes in endotracheal tube position as the patient is moved from the intubated neutral position to the more fully extended position for thyroidectomy have been well documented.^{7,8} Only after the patient is fully positioned, should the anesthesiologist secure the tube in place with tape at the corner of the mouth. Comfortable access to the operative field is not incompatible with the proper positioning of the neck and the use of the monitoring ET tube.

Once the patient is positioned and the tube verified in place, the tube is taped at the level of the lips in order to avoid ET tube displacements. The ET tube is held by an articulated arm which guarantees stability throughout the case by preventing any bending or shearing as the tube exits the mouth. This articulated arm can incorporate a video camera for recording purposes (Fig. 6).

As the patient is fully positioned with the neck hyperextended and the ET tube taped in place, the following monitor settings are checked to guarantee a definitive correct tube placement before starting the operation:

- Impedance values of less than 5 k Ω and impedance imbalance of less than 1 k Ω which implies good contact between the electrodes and tissue.
- Presence of a normal baseline with waveform amplitudes typically between 30 to 70 mV. The presence of baseline

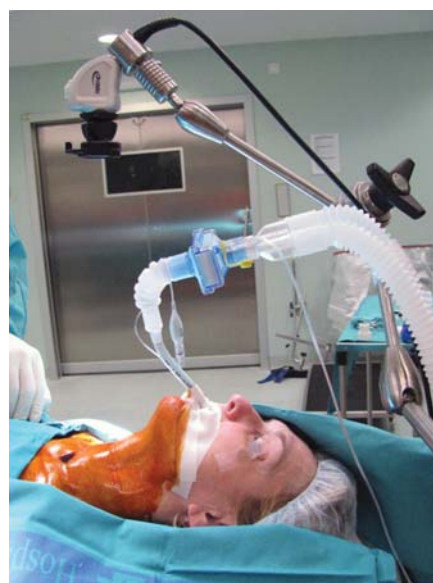

Fig. 6: Endotracheal tube support apparatus incorporating a video camera

respiratory variation when present on both channels implies good position of the endotracheal tube at the level of the vocal cords.

- Appropriate event threshold of 100 μV .
- Initial stimulation level of 1 to 2 mA.

Intraoperative Nerve Monitoring

Before nerve identification and ideally at the beginning of the case, the stimulator probe should be tested directly on either the infrahyoid or sternocleidomastoid muscle to confirm appropriate muscle twitching. Expected muscle activity should be recorded back on the monitor. This confirms that the current pulse generator and probe are working properly and confirms lack of ongoing paralytic agent.

An EMG signal is initially obtained from the vagus nerve before identification of RLN. To confirm overall system function, we visually identify the vagus nerve and stimulate it obtaining a true positive result with electromyographic registration (true electrophysiological positive response or positive EMG signal). This step (initial vagal stimulation at the beginning of the operation) is crucial to assess that the monitoring system is functioning correctly and that the normal pathway of RLN signal is elicited (a negative response is considered reliable). The ipsilateral vagus nerve is stimulated directly by a 1 to 2 cm dissection of the carotid sheath and then applying the stimulator directly on the nerve (repetitive current pulsed stimulation, 1 to 2 mA range, four pulses per second with pulse duration of 100 μs and event threshold at 100 μV).

The RLN is located and identified at the tracheoesophageal groove in proximity to the inferior thyroid artery. The nerve is mapped and stimulated obtaining an EMG signal. The nerve is initially searched for at 2 mA and fully mapped out. It is then dissected and visually confirmed. Once the nerve is visualized, the stimulation current may be turned down to 1mA. One should keep in mind that RLN extralaryngeal branching can be encountered in approximately 30 to 40% of patients, particularly at the level of Berry's ligament. Thus, it is necessary to dissect the RLN from the lower neck toward the RLN entrance into the larynx. In a case of branched RLN, each of the branches should be stimulated separately using the stimulation current of 0.4 to 0.5 mA and both EMG and laryngeal twitch response of these individual branches should be evaluated to allow for reliable assessment of motor and sensory fibers' distribution.

At the conclusion of the case the final testing of RLN and vagus nerve is performed after removal of the surgical specimen and ensuring complete hemostasis of the surgical field.

Interpretation of Signals

The most important principle of vagus and RLN monitoring is that the surgeon must not only visually identify the nerve but must also demonstrate satisfactory electrical EMG response before dividing any tissue. When using IONM a negative response when stimulating suspicious neural tissue in the surgical field should not be accepted as a true negative until a true positive has been identified.⁴ This principle will make nerve identification and dissection safer. When we use IONM of the vagus and RLN, all EMG signals should be used judiciously and interpreted cautiously.

Troubleshooting Algorithm for Loss of Signal

Loss of signal (LOS) represents a challenging situation during IONM and it occurs when the original EMG signal which was obtained from the vagus and RLN nerve cannot be elicited at any point during surgery. Loss of IONM signal is defined as low or absent EMG activity when stimulating the vagus or RLN nerve and is classified as true positive if vocal cord palsy is confirmed on postoperative laryngoscopy and false positive if no vocal cord palsy is present postoperatively.

When LOS occurs intraoperatively, a troubleshooting protocol should be followed to check the IONM equipment for technical problems. In the absence of EMG activity or a strikingly low amplitude below 100 μV when stimulating the RLN, the first procedure to be performed is to palpate the larynx by placing a finger behind the posterior plate of the cricoid to feel the posterior cricoarytenoid muscle contraction in response to RLN stimulation. If digital detection of the laryngeal twitch is present in response to RLN stimulation, then the stimulation side of the monitoring system is working properly (neural function assured) and equipment malfunction should be considered⁹ (Fig. 7).

The most frequent causes of equipment malfunction are ET tube electrode malposition, displacement of grounding electrodes or malfunction of the stimulating probe.^{4,10}

Contralateral vagal assessment also represents a useful option for troubleshooting in addition to laryngeal palpation if an ipsilateral RLN stimulation is not giving optimal electrophysiological signal. This is especially evident when bilateral procedures are planned as we can modify surgical strategy in bilateral thyroid procedures according to IONM findings as proclaimed by Goretzki et al.¹¹

If contralateral vagus stimulation does not give an adequate EMG signal, an endotracheal tube related problem (tube malposition) has to be investigated as first option. However, if the contralateral vagus nerve is currently functioning (correct endotracheal tube position), one has to consider a possible nerve injury.

If laryngeal twitch is absent when the nerve is stimulated, stimulation current is not appropriately delivered, thus a stimulation-side error is the base of the problem, therefore, the nerve stimulator and monitor should be checked. Stimulator probe function should be checked applying its tip directly on muscle to confirm a muscle twitch and the whole equipment, with special attention focused on the monitor screen, should be fully reviewed for current delivery. It is of paramount importance in the monitor problem solving algorithm to rule out the possibility of any neuromuscular blockage administered at that point.⁴ It is important to keep in mind that vagal stimulation represents the starting and ending point of IONM as confirmation of anatomical and functional integrity of the system.¹² Troubleshooting algorithm for LOS is shown in flow chart 1.

If a LOS is detected during the case, we should bear in mind that the RLN may have been injured and therefore an effort will be made considering the following aspects:

1. Identification of the injury site (location of lesion-neural mapping of the injury point).

There are two types of RLN lesions identified by IONM: The global (diffuse) type and the localized type. The point of lesion (disrupting point) can only be identified in the localized type of RLN lesion.

When there is LOS during surgery especially after complete dissection of the RLN, it means that the nerve may have been injured during manipulation. Once

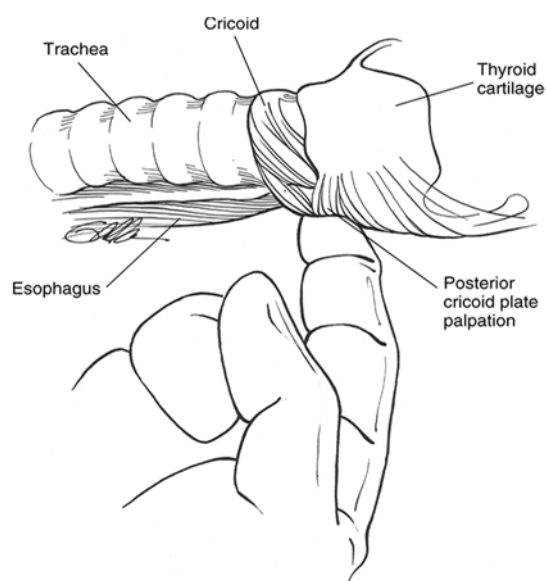
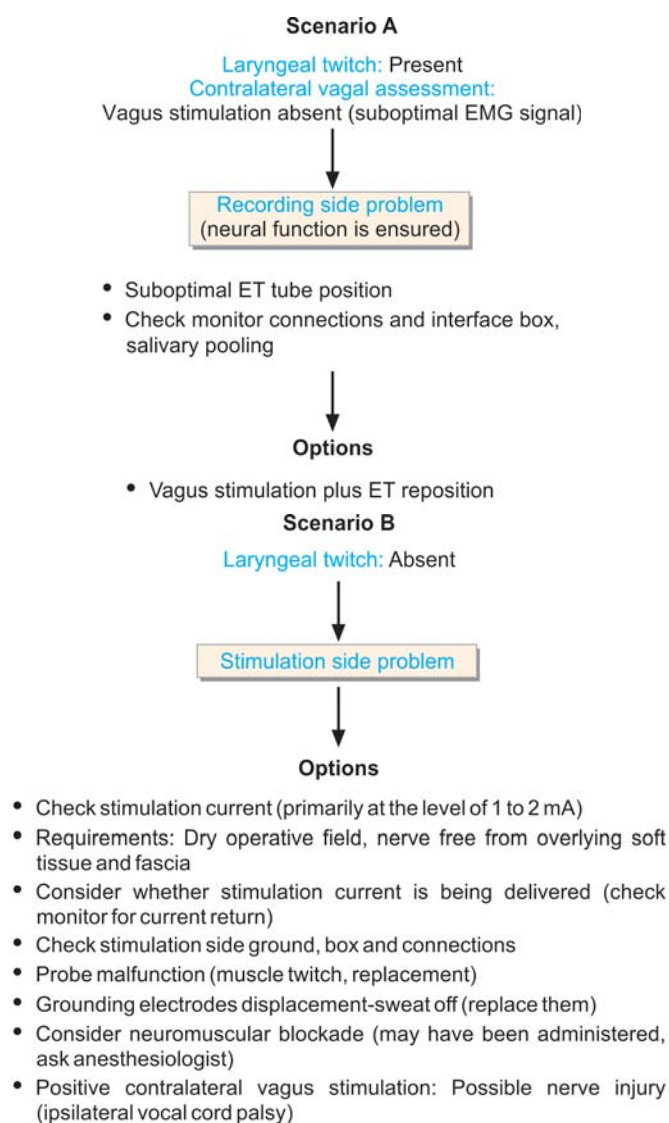


Fig. 7: Laryngeal twitch. Palpation of the posterior cricoarytenoid muscle by placing a finger behind the posterior plate of the cricoid when stimulating the RLN. Reproduced with permission from Randolph GW. Surgical anatomy of the recurrent laryngeal nerve (Courtesy: Randolph GW (Ed). (Surgery of the thyroid and parathyroid glands. Philadelphia, PA: Saunders 2003)

potential false loss of signal is ruled out, one should go back to the vagus nerve and stimulate it. If there is no signal after stimulating the vagus, it should be assumed that the nerve is injured and identification of the disrupted point of nerve conduction is essential. A careful examination of the course of the nerve should be undertaken to investigate potential causes of injury. The nerve should be stimulated from distal to proximal, stimulating the entire segment of nerve that has been dissected to see if the exact segment of signal loss can be identified. This systematic procedure of nerve stimulation allows the identification of the disrupted point and facilitates the surgeon with an analysis of the surgical procedure which helps to identify and understand the possible causes of nerve damage.

2. Intraoperative decision-making on the extent of dissection of the contralateral lobe in bilateral thyroid diseases to avoid the risk of bilateral cord palsy.



Flow Chart 1: Strategic approach to intraoperative LOS. Monitor problem solving algorithm

Loss of signal at the first side of dissection predicts ipsilateral nerve injury at least temporarily,¹¹ that is early postoperative vocal cord paralysis in 30 to 45% of the patients.¹³ In these instances, the surgeon can consider converting a one-stage bilateral exploration into a staged operation or performing a less aggressive procedure on the contralateral side (i.e. near-total or subtotal thyroidectomy). Intraoperative LOS is an unexpected surgical finding that justifies a surgeon's intraoperative decision-making as to whether or not to carry on with the surgical procedure on the contralateral side. Intraoperative LOS must ensure that the surgeon adopts a rational and good surgical decision for their patients that include the avoidance of potential bilateral nerve paralysis.¹² This change of operative strategy is in the patient's best interest and could reduce the risk of possible bilateral vocal cord palsy. However, intraoperative recovery of neural signal has been repeatedly documented and may translate short-lasting neurapraxia due to nerve compression or tension. Repeated testing may detect signal recovery and contralateral surgery can then be performed as planned.

DOCUMENTATION

Vocal cord examination is routinely performed pre-operatively and is mandatory after surgery.^{12,14,15} Postoperative laryngoscopy should be done preferably

within one week after surgery.¹⁶ During IONM, printing of the stimulation waves is a very important aspect of the procedure for correlation with patient's outcome. The comparison of all the events evidenced during IONM (intraoperative EMG) in combination with postoperative clinical examination of vocal cord function should be the basis for test definition.

We define a true negative test, according to Chan et al, as the presence of a typical vocal cord EMG response (intact IONM signal) at the end of monitoring with postoperative normal vocal cord mobility on laryngoscopy (intact laryngeal function). In contrast, if a decreased or absent signal (LOS) is evidenced at the end of operation and confirmed with ipsilateral postoperative paralysis at laryngeal examination that is defined as a true positive test.¹⁷ The standard of procedures for IONM is pointed out in Table 1.

SUMMARY

Intraoperative verification of the anatomical and functional integrity of the RLN is of paramount importance to avoid potential RLN injury and postoperative vocal cord palsy. Although neuromonitoring is a reality in surgical practice, we agree with Dionigi et al when they state that IONM method has still some limitations.¹⁸ The current little use and implications of superior laryngeal nerve monitoring due to anatomical reasons makes its use not as reliable and

Table 1: Standard procedures for IONM

Procedures for IONM
<ol style="list-style-type: none"> 1. Preoperative laryngoscopy to assess cord mobility. 2. Intubation with a short acting, nondepolarizing agent. 3. Monitoring tube placement: Notice optimal depth of insertion and tube rotation. 4. Patient positioning: Shoulder roll with head extended. 5. Definitive tube fixation: Secure tube in place and address support of tube out of mouth. Repeat laryngoscopy for visualization of the glottis after patient positioning. 6. Apply adhesive surface ground electrodes on skin (shoulder). 7. Equipment set-up monitor settings: <ul style="list-style-type: none"> • Respiratory variation of the baseline-waveforms amplitudes typically between 30 to 70 mV • Impedance values of less than 5 kΩ and impedance imbalance of less than 1 kΩ • Event threshold of 100 μV • Initial stimulation level of 1 to 2 mA 8. Neural stimulation basics: <ul style="list-style-type: none"> • Initial vagal stimulation • Mapping of the RLN • Final vagal stimulation at the completion of surgery 9. Interpretation of signals: <ul style="list-style-type: none"> • Unchanged vagal signal obtained successfully with the same stimulation level during the operation (functional integrity of the RLN) • Loss of vagal signal implies possibility of neural injury. Identification of the disrupted point, identify mechanism of injury and intraoperative decision making 10. Documentation: <ul style="list-style-type: none"> • Waveform documentation: Amplitude, latency, waveform morphology and magnitude of stimulating current measured at the beginning, during and completion of surgery for ipsilateral RLN and vagus nerve • Postoperative laryngeal examination: Vocal cord mobility

accurate as RLN IONM, the application of standardized protocols and rational use to avoid false IONM results, the knowledge of common technical, anesthesiology and anatomy pitfalls and the capacity to apply well-designed troubleshooting protocols, the need of prospective studies and research focused on electrophysiology of the RLN including the recent application of continuous monitoring of the vagus nerve in thyroid and parathyroid surgery (NIM APS Continuous Nerve Monitoring) using the automatic periodic stimulation electrode (APSTM Electrode Stimulator, Medtronic Xomed, Inc), the absence in medical literature of cost-effectiveness analysis, the use of this device in surgical procedures under local anesthesia and the perception that IONM should be restricted to difficult cases only are some of these limits. In any case, IONM should not replace clinical judgment.

Further studies are required to assess the real benefits of IONM not only in high-risk thyroid surgeries but in all surgeries where the vagus and RLN nerves are likely to be dissected.

ACKNOWLEDGMENT

This study was supported in part by a grant from the Spanish Ministry of Science and Innovation (Fondo de Investigaciones Sanitarias, PI09/90654: Evaluación Clínica de un Sistema de Monitorización Nerviosa Intraoperatoria para evitar la lesión de los nervios laríngeos en la Cirugía Tiroidea. Instituto de Salud Carlos III. Ministerio de Ciencia e Innovación. España).

REFERENCES

- Davis WE, Rea JL, Templer J. Recurrent laryngeal nerve localization using a microlaryngeal electrode. *Otolaryngol Head Neck Surg* 1979;87:330-33.
- Goldstone AC, Schettino RL. The electrode endotracheal tube: A state of the art method for monitoring recurrent laryngeal nerve integrity vocal cord muscle in the intubated patient. *Otolaryngol Head N Surg* 1990;103:249-53.
- Lu IC, Chu KS, Tsai CJ, Wu CW, Kuo WR, Chen HY, et al. Optimal depth of NIM EMG endotracheal tube for intraoperative neuromonitoring of the recurrent laryngeal nerve during thyroidectomy. *World J Surg* 2008;32:1935-39.
- Randolph GW. Surgical anatomy of the recurrent laryngeal nerve. In: Randolph GW (Ed). *Surgery of the thyroid and parathyroid glands*. Philadelphia, PA: Saunders 2003:300-42.
- Chu KS, Wu SH, Lu IC, Tsai CJ, Wu CW, Kuo WR, et al. Feasibility of intraoperative neuromonitoring during thyroid surgery after administration of nondepolarizing neuromuscular blocking agents. *World J Surg* 2009;33:1408-13.
- Marusch F, Hussock J, Haring G, Hachenberg T, Gastinger I. Influence of muscle relaxation on neuromonitoring of the recurrent laryngeal nerve during thyroid surgery. *Br J Anaesth* 2005;94:596-600.
- Yap SJ, Morris RW, Pybus DA. Alterations in endotracheal tube position during general anesthesia. *Anesth intensive care* 1994;22(5):586-88.
- Jin-Hee K, Ro YJ, Seong-Won M, Chong-Soo K, Seong-Deok K, Lee JH, Jae-Hyon B. Elongation of the trachea during neck extension in children: Implications of the safety of endotracheal tubes. *Anesth Analg* 2005;101:974-77.
- Randolph GW, Kobler JB, Wilkins J. Recurrent laryngeal nerve identification and assessment during thyroid surgery: Laryngeal palpation. *World J Surg* 2004;28:755-60.
- Tomoda C, Hirokawa Y, Uruno T, Takamura Y, Ito Y, Miya A, et al. Sensitivity and specificity of intraoperative recurrent laryngeal nerve stimulation test for predicting vocal cord palsy after thyroid surgery. *World J Surg* 2006;30:1230-33.
- Goretzki PE, Schwarz K, Brinkmann J, Wirowski B, Lammers BJ. The impact of intraoperative neuromonitoring (IONM) on surgical strategy in bilateral thyroid diseases. Is it worth effort? *World J Surg* 2010;34:1274-84.
- Dralle H, Lorenz K. Intraoperative neuromonitoring of thyroid gland operations: Surgical standards and aspects of expert assessment. *Chirurg* 2010;81:612-19.
- Thomusch O, Sekulla C, Marchens A, Neumann HJ, Timmermann W, Dralle H. Validity of intraoperative neuromonitoring signals in thyroid surgery. *Langenbecks Arch Surg* 2004;389:499-503.
- Randolph GW, Kamani D. The importance of preoperative laryngoscopy in patients undergoing thyroidectomy: Voice, vocal cord function and the preoperative detection of invasive thyroid malignancy. *Surgery* 2006;139:357-62.
- Witt RL. Recurrent laryngeal nerve electrophysiologic monitoring in thyroid surgery: The standard of care? *J Voice* 2005;19:497-500.
- Dionigi G, Boni L, Rovera F, Rausei S, Castelnuovo P, Dionigi R. Postoperative laryngoscopy in thyroid surgery: Proper timing to detect recurrent laryngeal nerve injury. *Langenbecks Arch Surg* 2010;395:327-31.
- Chan WF, Lo CY. Pitfalls of intraoperative neuromonitoring for predicting postoperative recurrent laryngeal nerve function during thyroidectomy. *World J Surg* 2006;30(5):806-12.
- Dionigi G, Barczynski M, Chiang FY, Dralle H, Duran-Poveda M, Iacobone M, et al. Why monitor the recurrent laryngeal nerve in thyroid surgery? *J Endocrinol Invest* 2010;33: 819-22.

ABOUT THE AUTHORS

Manuel C Durán Poveda

Professor, Department of Endocrine Surgery, University Hospital of Fuenlabrada Health Sciences School, King Juan Carlos University Madrid, Spain

Gianlorenzo Dionigi

Associate Professor, Department of Surgical Sciences, Endocrine Surgical Research Center, University of Insubria (Varese-Como) Varese, Italy

Antonio Sitges-Serra

Professor and Chairman, Department of Endocrine Surgery, Hospital del Mar, Barcelona, Spain

Marcin Barczynski

Associate Professor, Department of Endocrine Surgery, 3rd Chair of General Surgery, Jagiellonian University College of Medicine Krakow, Poland

Peter Angelos

Professor and Chief, Department of General Surgery and Surgical Oncology, MacLean Center for Clinical Medical Ethics, University of Chicago, Chicago, USA

Henning Dralle

Professor and Chairman, Department of General, Visceral and Vascular Surgery, Martin Luther University Halle-Wittenberg Halle, Germany

Eimear Phelan

Research Assistant, Department of Thyroid and Parathyroid Surgery Massachusetts Eye and Ear Infirmary, Harvard Medical School Boston, USA

Gregory Randolph

Associate Professor, Department of Thyroid and Parathyroid Surgery Massachusetts Eye and Ear Infirmary, Harvard Medical School Boston, USA

Corresponding Author

Manuel C Durán Poveda, Professor, Department of Endocrine Surgery University Hospital of Fuenlabrada, Health Sciences School, King Juan Carlos University, Camino del Molino nº2, 28942 Fuenlabrada Madrid, Spain, e-mail: mduran.hflr@salud.madrid.org