

Embryological Remnants of the Thyroid Gland and their Significance in Thyroidectomy

¹Ranil Fernando, ²Anuradha Rajapaksha, ³Narada Ranasinghe, ⁴Duminda Gunawardana

ABSTRACT

Thyroid gland has three main embryological remnants: pyramidal lobe, tubercle of Zuckerkandl and thyrothymic remnants. They are commonly missed or misidentified during dissection. Each of these remnants plays a critical role in thyroidectomy as they help to identify the relevant anatomy and therefore help prevent accidental damage to other structures in close proximity during dissection.

In this article, we describe the current knowledge of each of these remnants and their significance in thyroidectomy.

Conclusion: It is important that all these remnants are objectively looked for and removed during surgery in order to prevent recurrences.

Keywords: Thyroid surgery, Thyroidectomy, Goiter.

How to cite this article: Fernando R, Rajapaksha A, Ranasinghe N, Gunawardana D. Embryological Remnants of the Thyroid Gland and their Significance in Thyroidectomy. *World J Endoc Surg* 2014;6(3):110-112.

Source of support: Nil

Conflict of interest: None

INTRODUCTION

The thyroid gland is the first of the body's endocrine glands to develop, at approximately the 24th day of gestation.¹ It originates from an endodermal proliferation on the median surface of the developing pharyngeal floor in the region of the foramen cecum and descends to reach the adult position by the 7th week of gestation.

Thyroid gland has three main embryological remnants: pyramidal lobe (and other remnants of the thyroglossal tract), tubercle of Zuckerkandl and thyrothymic remnants (Fig. 1).

Each of these remnants plays a critical role in thyroidectomy. Locating these remnants helps to identify the relevant anatomy and therefore help prevent accidental damage to the vital structures in close proximity during dissection. Proper identification and excision of all remnants with the

thyroid gland will ensure a 'total' thyroidectomy is done and in addition will prevent recurrence of goiter.

Since, its first description in 925 AD attributed to Albucasis,² thyroidectomy has evolved into a safe operation despite its turbulent history.

Techniques, such as capsular dissection, autotransplantation of accidentally excised parathyroids and dissection of embryological remnants have made significant improvements to the outcome of thyroidectomy.

PYRAMIDAL LOBE AND OTHER REMNANTS OF THYROGLOSSAL TRACT

Remnants of the thyroglossal tract usually present as thyroglossal cysts or thyroglossal fistulae but may rarely present as carcinoma. Lingual thyroids occur when the descent of the thyroid gland arrests at the base of the tongue. Results of a study with over 300 thyroidectomies conducted in University Surgical Unit of NCTH Ragama³ has shown that in up to 50% of people, the inferior end of the thyroglossal ducts fails to obliterate and persists as the pyramidal lobe. Persistent thyroglossal tract and/or pyramidal lobe are causes for recurrence after thyroidectomy. Removal of these recurrences is difficult and challenging. Snook KI et al state that 'Routine dissection of the pyramidal area at least up to and beyond the laryngeal notch should be a routine part of every thyroidectomy' thus emphasizing the importance of removing remnants of thyroglossal tract if they are present.⁴

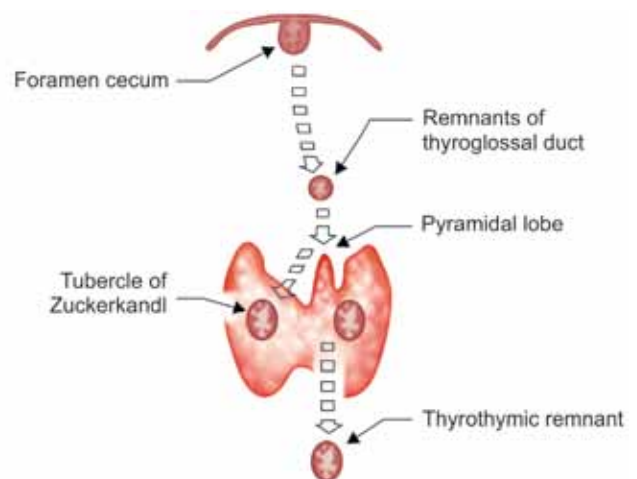


Fig. 1: Development of embryological remnants of thyroid gland

¹Professor, ^{2,3}Registrar, ⁴Senior Registrar

¹⁻⁴Department of Surgery, Professorial Surgical Unit, North Colombo Teaching Hospital, Ragama, Sri Lanka

Corresponding Author: Ranil Fernando, Professor Department of Surgery, Professorial Surgical Unit, North Colombo Teaching Hospital, Ragama, Western Sri Lanka Sri Lanka, Phone: 0714736151, e-mail: ranilfern@slnet.lk

TUBERCLE OF ZUCKERKANDL (THE FORGOTTEN TUBERCLE)

In 1902, an Austrian anatomist, Emil Zuckerkandl described a pyramidal extension of the thyroid gland and called it 'processus posterior glandulae thyroideae' which was later named as the Tubercle of Zuckerkandl in his honor.

Zuckerkandl tubercle (ZT) is a derivative of the 4th branchial pouch, the ultimobranchial body. It is located at the most posterior side of each lobe of the thyroid in close relation to the recurrent laryngeal nerve (RLN) and the superior parathyroid glands.

Zuckerkandl tubercle was forgotten for over 80 years which is the 'Era of subtotal thyroidectomy'. Identification of ZT is a helpful landmark in thyroid surgery as it will help identify the RLN due to their close relationship.⁵

New understating of tissue planes around the thyroid suggest that tubercle of Zuckerkandl and the superior parathyroid glands lie within a superficial vascular fascial layer while the RLN lies on a deeper more fibrous layer, the ligament of Berry.⁶ The tertiary branches of the inferior thyroid artery pass in the superficial vascular fascial layer antero-lateral to the RLN. This concept of two vascular fascial planes may minimize risk of damage to RLN when the tubercle of Zuckerkandl is being dissected off the thyroid bed and help to preserve blood supply to the superior parathyroid glands.

As suggested by Hisham AN et al, tubercle of Zuckerkandl is classified into grades according to its size (Table 1).⁷

Generally, tubercle of Zuckerkandl is found in 63 to 80% of patients undergoing thyroidectomy at least on one side. Pressure symptoms have been attributed to the presence of grade III tubercles, especially with very large tubercles.⁷ In a study conducted at University Surgical Unit at NCTH Ragama, it was found to be present in 94% of patients at least in one side and 64% of patients in both the sides but pressure symptoms were not significantly associated with size of the tubercle.⁸

THYROTIMIC REMNANTS/THYROTIMIC RESTS

Thyrothymic remnants develop consequently to continued descent of the developing thyroid tissue into the mediastinum beyond its lower pole.

Rests of thyroid tissue within the thyrothymic area are relatively common (50%) and are often mistaken for lymph nodes or parathyroid glands. These rests are classified according to their attachment to the inferior poles of the thyroid gland as suggested by Sackett WR et al (Fig. 2 and Table 2).⁹

Eighty percent of identified rests are attached to the thyroid proper by a pedicle of thyroid tissue or by a fibrovascular band while 20% are entirely separate.⁹ Most of these rests are small. Majority being less than 1 cm in diameter makes them at risk of being left behind; if not objectively looked for and removed during thyroidectomy. In a study conducted by University Surgical Unit NCTH Ragama, thyrothymic remnants were found in 30% of patients who underwent thyroidectomy.³

When thyrothymic rests enlarge and extend down through the thoracic inlet they constitute retrosternal goiters. Recurrences can occur after thyroidectomy, if these thyrothymic remnants are left behind. Second surgery is fraught with high risk of damaging the RLN and parathyroid glands.

Table 1: Grades of Zuckerkandl tubercles as suggested by Hisham AN et al⁷

Grades	Size (cm)
0	Unrecognizable
I	<0.5
II	0.5-1.0
III	>1.0

Table 2: Grades of thyrothymic remnants as suggested by Sackett WR et al⁹

Grades	Description
I	Protrusion of thyroid tissue
II	Attached to thyroid by a narrow pedicle of thyroid tissue
III	Attached to thyroid by a fibrovascular band
IV	Completely separate from thyroid gland

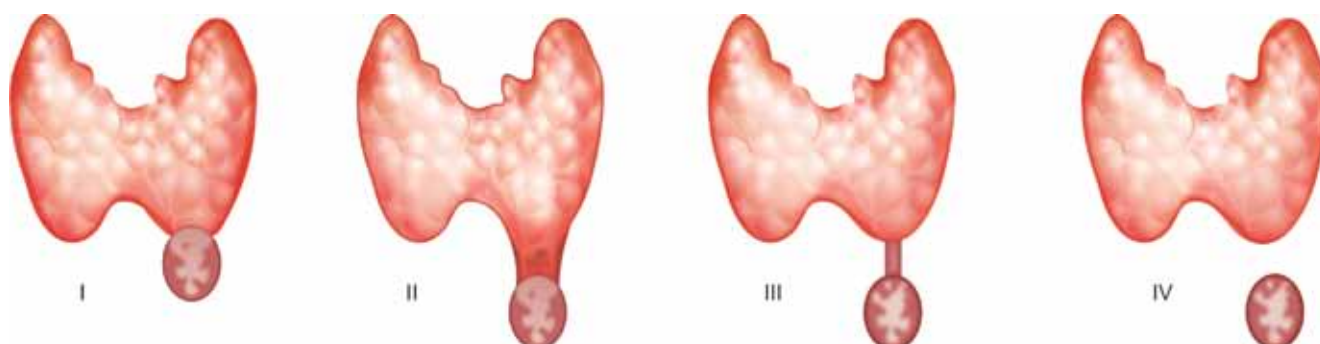


Fig. 2: Grades of thyrothymic remnants as suggested by Sackett WR et al⁹

CONCLUSION

Identification of embryological remnants is critical for safe and complete dissection in thyroidectomy. It is important to remember that the RLN and the parathyroid glands are closely related to these embryological remnants and are in danger of damage during dissection. Complete removal of the thyroid and its embryological remnants prevents recurrences. So, during thyroidectomy, it is critical that these remnants are objectively looked for and removed.

REFERENCES

1. Nussey S, Whitehead S. Endocrinology: an integrated approach. Oxford: BIOS Scientific Publishers: 2001. Chapter 3.
2. Ignjatović M. Overview of the history of thyroid surgery. *Acta Chir Jugosl* 2003;50(3):9-36.
3. Data presented at Henry Rajaratnam oration. Annual Academic Sessions of Endocrine Society of Sri Lanka-2013.
4. Snook KL, Stalberg PL, Sidhu SB, Sywak MS, Edhouse P, Delbridge L. Recurrence after total thyroidectomy for benign multinodular goiter. *World J Surg* 2007 Mar;31(3):593-598.
5. Pelizzo MR, Toniato A, Gemo G. Zuckerkandl's tuberculum: an arrow pointing to the recurrent laryngeal nerve (constant anatomical landmark). *J Am College Surg* 1998 Sep;187(3):333-336.
6. Serpell JW. New operative surgical concept of two fascial layers enveloping the recurrent laryngeal nerve. *Annals of Surgical Oncology* 2010 Jun;17(6):1628-1636.
7. Hisham AN, Aina EN. Zuckerkandl's tubercle of the thyroid gland in association with pressure symptoms: a coincidence or consequence? *Aust New Zealand J Surg* 2000 Apr;70(4):251-253.
8. Ranasinghe KPNG, Bulathsinhala BKS, Prasad IHDS, Fernando R. Incidence and morphology of the tubercle of Zuckerkandl and its important relationship in thyroid surgery. *Sri Lanka J Surg* 2013 Aug;31(S1):18-19.
9. Sackett WR, Reeve TS, Barraclough B, Delbridge L. Thyrothymic thyroid rests: incidence and relationship to the thyroid gland. *J Am College Surg* 2002 Nov;195(5):635-640.

