

Lingual Thyroid with Hyperthyroidism in a Child: A Rare Presentation

¹Kanika Rana, ²Nikhil Arora, ³Vikram Wadhwa, ⁴Eishaan Bhargava

ABSTRACT

Lingual thyroid is the most common presentation of ectopic thyroid tissue (ETT). It is a rare condition presents in about 1 in 100,000 populations, more commonly is seen in females. It is even rarer in children. It is mainly associated with euthyroid or hypothyroid status; hyperthyroidism is rarely seen. Its management varies from surgical excision to medical management. Here, we present a case of lingual thyroid presenting with hyperthyroidism and its management.

Keywords: Children, Hyperthyroidism, Lingual, Thyroid.

How to cite this article: Rana K, Arora N, Wadhwa V, Bhargava E. Lingual Thyroid with Hyperthyroidism in a Child: A Rare Presentation. *World J Endoc Surg* 2015;7(2):36-38.

Source of support: Nil

Conflict of interest: None

INTRODUCTION

The thyroid gland appears as a proliferation of endodermal tissue in the midline of the floor of the pharynx, between the first and second branchial arches. It descends in front of the hyoid bone and laryngeal cartilages, and reaches its final position in front of the trachea by 7th week.¹ Ectopic thyroid tissue (ETT) can occur anywhere in this tract of descent, lingual thyroid being the most common ectopic site of thyroid gland. It is mostly asymptomatic and commonly associated with hypothyroidism. Hyperthyroidism is rarely seen with lingual thyroid with only a few cases having been reported in literature. Here, we present a case of lingual thyroid in a child along with its management.

CASE REPORT

An 11-year-old female presented to the outpatient department (OPD) with complains of dysphagia and hoarseness for 3 months. She had associated complains of increased sweating, heat intolerance, weight loss and increased

frequency of stools. On general physical examination, the patient had a pulse rate of 110/min. She had mild proptosis and cold, moist palms. There was no associated palpable neck swelling. Oral examination revealed a fleshy mass in midline base of tongue with numerous congested vessels on the surface (Fig. 1). The mass was firm, non-tender, and moved with tongue movements. Her thyroid function tests revealed raised serum free T3 and T4 levels, and decreased levels of thyroid stimulating hormone (TSH). The results were as follows: T3-210 ng/dl, T4-15.2 ug/dl and TSH-0.01 uIU/ml against normal values of 60 to 190, 4.5 to 12.5 and 0.34 to 5.60 respectively suggesting hyperthyroidism. Contrast enhanced computed tomography (CECT) scan of the neck showed a heterogeneously enhancing mass in the base of tongue measuring 5.2 × 3.2 × 3.1 cm, causing luminal oropharyngeal narrowing (Fig. 2). Fine needle aspiration cytology (FNAC) from the swelling showed blood predominantly with few clusters of normal thyroid follicular cells, consistent with lingual thyroid. Patient underwent a ^{99m}Tc thyroid scan that revealed increased radiotracer uptake in the midline lingual region and no functioning thyroid tissue in the neck (Fig. 3). Patient was hence diagnosed as a case of lingual thyroid with hyperthyroidism. In view of lingual thyroid being the only thyroid tissue and considering the age of the patient, the patient was started on tablet carbimazole 15 mg once daily (OD) for 6 months. Three monthly follow-ups were done with thyroid function tests. Patient had a significant decrease in the size of the lingual thyroid with relief in associated symptoms after 6 months of therapy (Fig. 4). Treatment was continued till euthyroid status was attained, and a maintenance dose was continued for 1 year. No major side effects were noted with the antithyroid drug therapy. Patient has been following up for the last 1 year and is on a maintenance dose of carbimazole 5 mg OD without any evidence of an increase in size of the mass, or recurrence.

DISCUSSION

Lingual thyroid is a rare entity involving base of tongue and occurs in about 1:100000 individuals. It may or may not be associated with the presence of normal thyroid tissue in the pretracheal region. Apart from the base of tongue, ETT has also been reported in the mediastinum,

^{1,2}Senior Resident, ³Specialist, ⁴Junior Resident

¹⁻⁴Department of ENT, Maulana Azad Medical College New Delhi, India

Corresponding Author: Kanika Rana, Senior Resident Department of ENT, Maulana Azad Medical College, New Delhi India, Phone: 01125096033, e-mail: dr.rana.kanika@gmail.com



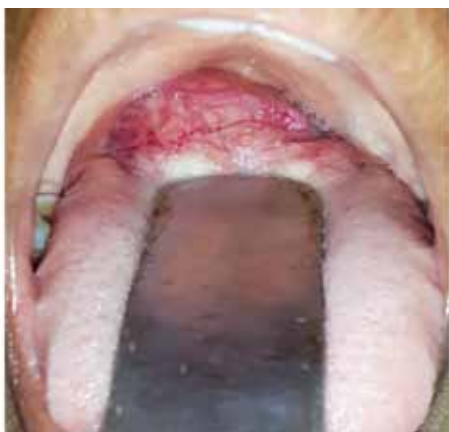

Fig. 1: A large, fleshy mass in the base of tongue with numerous congested vessels on the surface

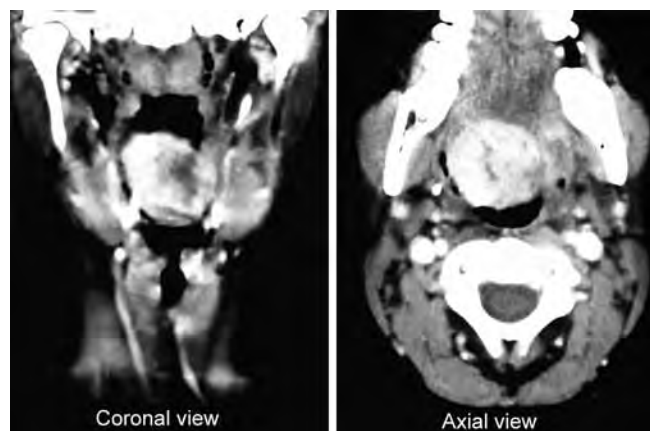


Fig. 2: Contrast enhanced computed tomography neck (coronal and axial sections) showing a large heterogeneously enhancing mass in the base of tongue region with nonvisualization of normal thyroid gland in the neck

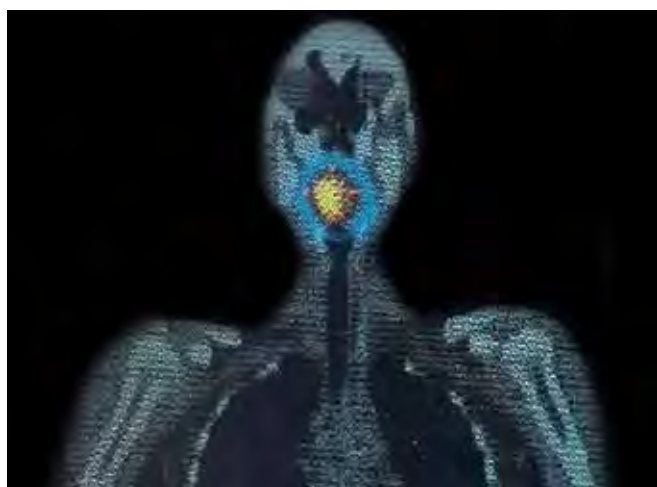


Fig. 3: ^{99m}Tc -thyroid scan showing increased radiotracer uptake in the region of base of tongue and no uptake in normal thyroid bed in pretracheal region

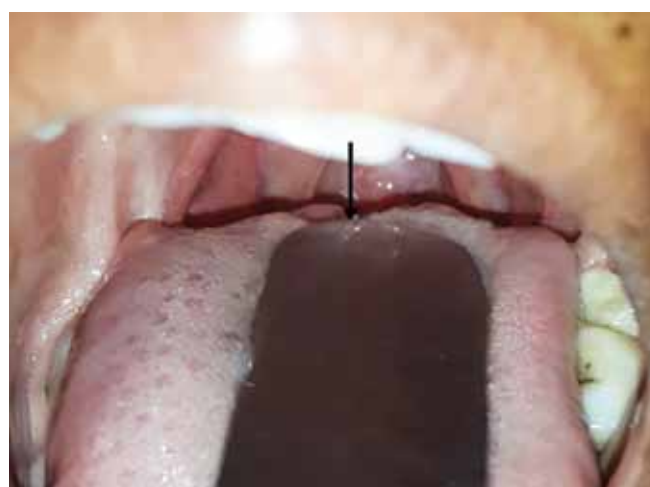

Fig. 4: Reduction in size of lingual thyroid post antithyroid drug therapy with carbimazole. Residual lingual thyroid mass postantithyroid therapy showing significant reduction in size of the mass (black arrow)

pericardial sac, heart, breast, duodenum, mesentery of the small intestine and adrenal gland.² Most cases of lingual thyroid are associated with hypothyroid or euthyroid status; only a few cases of lingual thyroid with hyperthyroidism or Graves' disease have been reported in literature.²⁻⁴ Lingual thyroid has been reported less commonly in children, and all reported cases of pediatric lingual thyroid were seen to be associated with hypothyroidism.^{5,6}

Ours is the first case report describing lingual thyroid with hyperthyroidism in a pediatric patient, and its complete management. Hyperthyroidism in children is generally treated by antithyroid drugs as the first line of management, carbimazole being the drug of choice. The response of antithyroid drugs in children has been variable, as reported in various studies. Surgery is considered the second line of management for hyperthyroidism.⁷ Radioactive ablation is not preferred in children due to an associated risk of the development of radiation

induced carcinomas. Block replacement therapy with methimazole and L-thyroxine has also been described with variable results.

Surgical excision of lingual thyroid is preferred in cases that are refractory to medical management. It is also indicated if the mass bleeds, produces obstructive symptoms, or if malignancy is suspected. Various approaches for excision of lingual thyroid include: transoral approach, transmandibular-translingual approach, lateral pharyngotomy approach and suprahyoid midline approach.⁸

CONCLUSION

Lingual thyroid with hyperthyroidism is a rare entity, and it is even rarer in children. Initial treatment aims at attaining euthyroid status for the patient using medical management. Surgical excision and radioactive ablation using iodine-131 are the other modalities for definite treatment.

REFERENCES

1. Collins P. Embryology and development. In: Williams PL, Bannister LH, Berry MM, editors. *Gray's anatomy: the anatomical basis of medicine and surgery*. 38th ed. New York: Churchill Livingstone; 1995. p. 174-199.
2. Jacob MJ, Ravina M. A rare case of lingual thyroid with hyperthyroidism: a case report and review of the literature. *Ind J Endocrinol Metab* 2012 May;16(3):441-443.
3. Abdallah-Matta MP, Dubarry PH, Pessey JJ, Caron P. Lingual thyroid and hyperthyroidism: a new case and review of the literature. *J Endocrinol Invest* 2002 Mar;25(3):264-267.
4. Kamijo K. Lingual thyroid associated with Graves' disease and Graves' ophthalmopathy. *Thyroid* 2005;15(12):1407-1408.
5. Rahbar R, et al. Lingual thyroid in children: a rare clinical entity. *Laryngoscope* 2008 Jul;118(7):1174-1179.
6. Singhal P, Sharma KR, Singhal A. Lingual thyroid in children. *J Ind Soc Pedod Prev Dent* 2011 Jul-Sep;29(3):270-272.
7. Bhadada S, Bhansali A, Velayutham P, Masoodi SR. Juvenile hyperthyroidism: an experience. *Ind Pediat* 2006 Apr;43(4):301-307.
8. Ward GE, Cantrell JR. The surgical treatment of lingual thyroid. *Ann Surg* 1954 May;139(5):536-544.

