

CASE REPORT

Carotid Body Paraganglioma: Report of Two Cases and Review of Literature

¹Rekha Matta, ²Kulamani Sahoo, ³Sunil Jagtap

ABSTRACT

We report two cases of carotid body paraganglioma – one was Shamblin Level III and the other was Shamblin Level I.

Keywords: Carotid artery, Carotid body, Paraganglioma, Shamblin Level.

How to cite this article: Matta R, Sahoo K, Jagtap S. Carotid Body Paraganglioma: Report of Two Cases and Review of Literature. *World J Endoc Surg* 2016;8(2):160-163.

Source of support: Nil

Conflict of interest: None

INTRODUCTION

Carotid body paraganglioma is a highly vascular neoplasm that develops in the adventitia of the carotid bulb. If left unoperated, it grows in size and is locally aggressive. It adheres to and encases the vessels and nerves. It can displace and even compress the trachea. Some tumors can even erode the base of the skull.

CASE REPORT

A 46-year-old woman presented with a swelling in the left side of neck of 18 years duration. The mass was in the left anterior triangle of neck, the visible part measured 6 cm longitudinally and 4 cm transversely. The upper border of the mass was not palpable as it was superior to the left horizontal ramus of the mandible. The mass was pulsatile and non-tender and could be moved transversely, but not longitudinally. There was no bruit and no other clinical findings. There was no family history of a similar problem. Contrast magnetic resonance imaging (Fig. 1) displayed a single, contrast-filled, ovoid mass

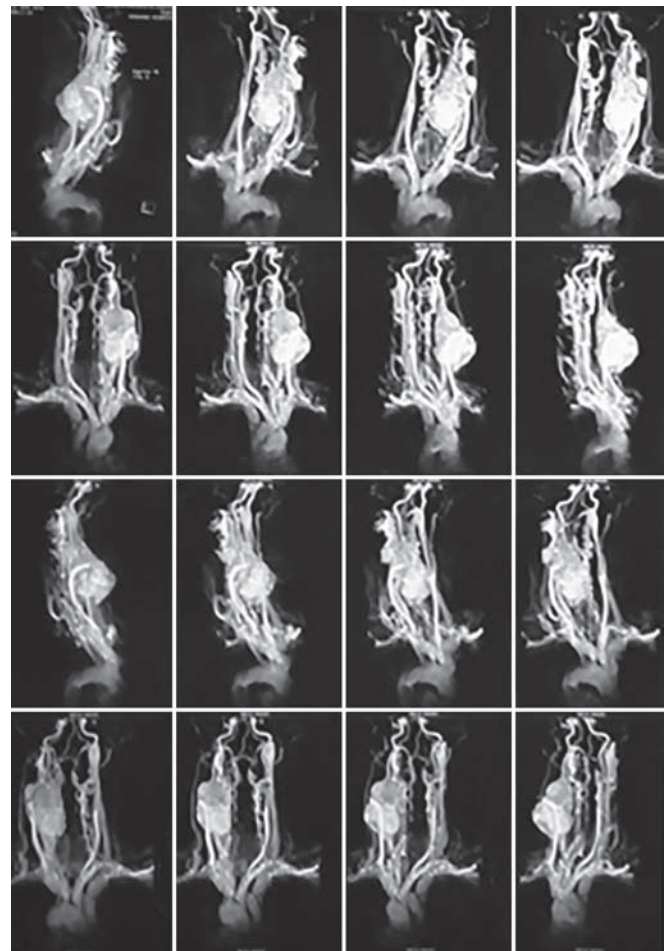


Fig. 1: Magnetic resonance angiogram displaying a highly vascular mass encasing the distal part of the left common carotid artery and the proximal part of the left ICA and the ECA

in the region of the carotid bulb obscuring the carotid artery bifurcation and causing gross deviation of trachea to the right.

The patient was taken for elective surgery (Figs 2A to D). The mass had incorporated the distal 3 cm of the left common carotid artery, the carotid bulb, and the proximal 3 cm of the left external carotid artery (ECA) and internal carotid artery (ICA). The left internal jugular vein (IJV), vagus, and hypoglossal nerves were densely adherent to the mass. Excision of the mass was done and a 4-mm polytetrafluoroethylene tube graft was interposed between the left common carotid artery and the ICA. The ECA was 1 mm in diameter and was ligated. Postoperative color Doppler (Fig. 3) demonstrated a good blood

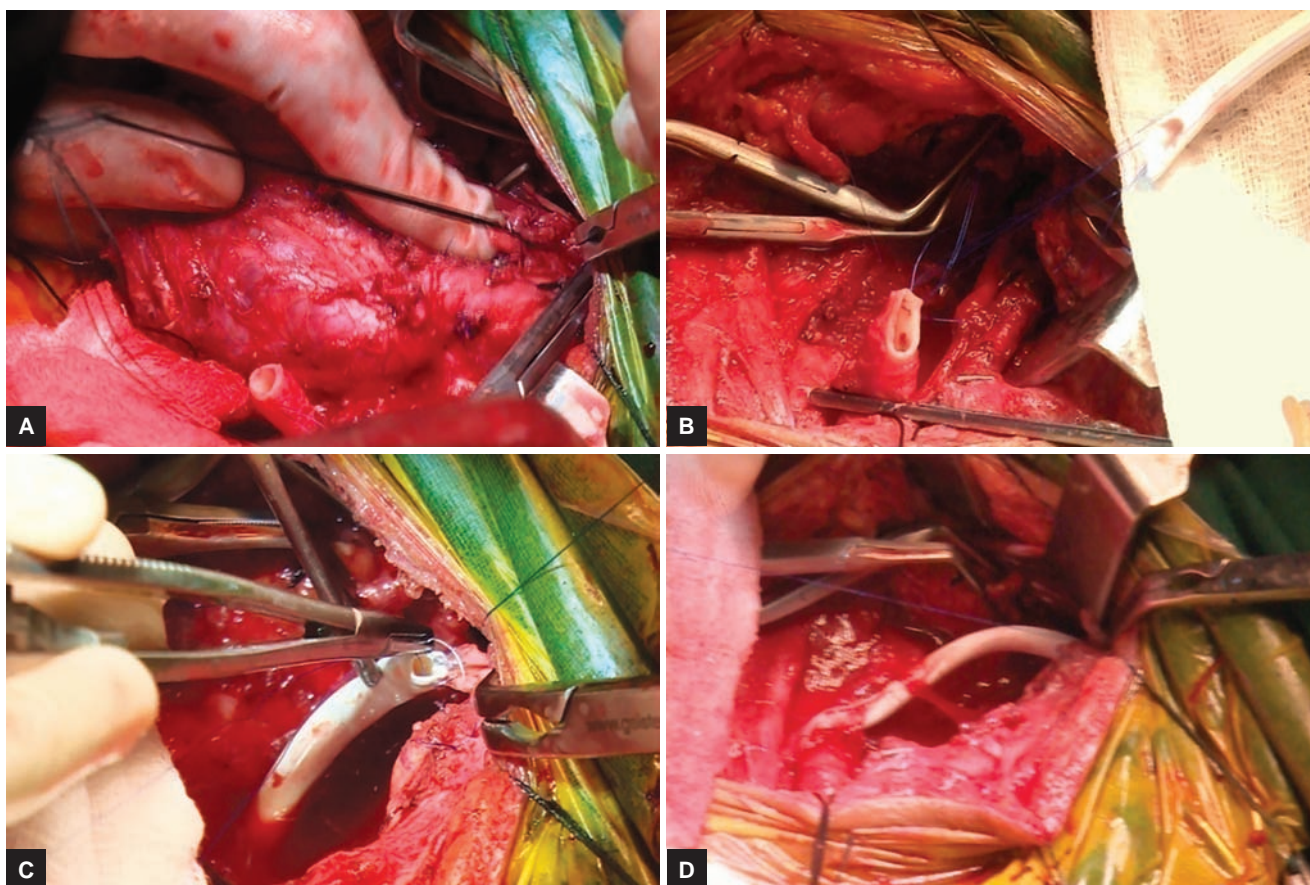
¹⁻³Professor

¹Department of Cardiovascular and Thoracic Surgery, Krishna Institute of Medical Sciences, Deemed University, Karad Maharashtra, India

²Department of Radiology, Krishna Institute of Medical Sciences Deemed University, Karad, Maharashtra, India

³Department of Pathology, Krishna Institute of Medical Sciences Deemed University, Karad, Maharashtra, India

Corresponding Author: Rekha Matta, Professor, Department of Cardiovascular and Thoracic Surgery, Krishna Institute of Medical Sciences, Deemed University, Karad, Maharashtra India, Phone: +912164241866, e-mail: rekhamatta@gmail.com



Figs 2A to D: Intraoperative photographs showing the carotid body paraganglioma disconnected from the left common carotid artery and interposition of the polytetrafluoroethylene graft between the left common carotid artery and the left ICA

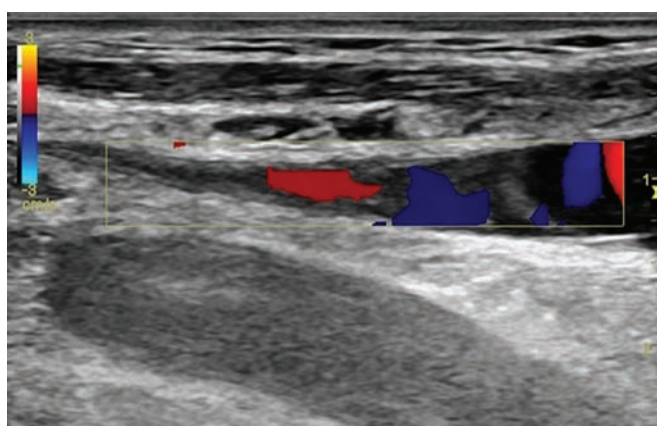


Fig. 3: Color Doppler of the left carotid artery showing adequate blood flow through the graft

flow through the graft. Histopathological examination (Figs 4 A to D) confirmed the diagnosis of carotid body paraganglioma. The patient was discharged on the sixth postoperative day without any deficit.

A 28-year-old man presented with a swelling in the left side of neck of 6 months duration. The mass was in the left anterior triangle of neck and measured 4 cm longitudinally and 3 cm transversely. The upper border of the mass was 1 cm inferior to the left horizontal ramus of the mandible. The mass was pulsatile and non-tender and could be moved transversely, but not

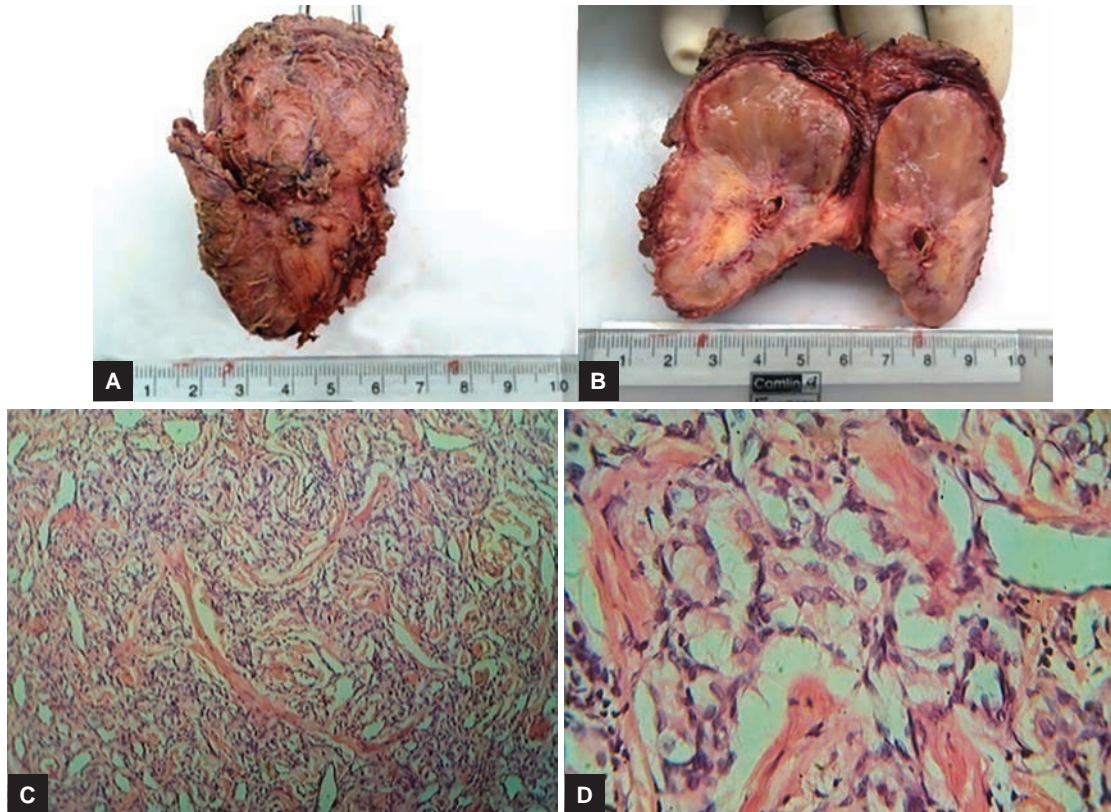
longitudinally. There was no bruit and no other clinical findings. There was no family history of a similar problem. Contrast spiral computed tomography (Fig. 5) displayed a single, contrast-filled, ovoid mass in the region of the left carotid bulb, splaying the left common carotid artery bifurcation.

Elective surgery (Figs 6 and 7) was performed and the mass excised (Fig. 8). Histopathological examination (Figs 9A to D) showed carotid body paraganglioma. The patient was discharged on the fifth postoperative day.

DISCUSSION

Carotid body paraganglioma is a rare neoplasm, although it represents 65% of head and neck paragangliomas.¹ The three distinct forms are familial (10–12%), sporadic (80–85%), and hyperplastic (2–5%, due to chronic hypoxia)²; 5% are bilateral and 5% are malignant.³ The usual presentation is an asymptomatic neck swelling of several years duration. Ten percent of cases can present with palsy of IX/X/XI/XII cranial nerves and/or Horner's syndrome. Functional tumors (secreting catecholamines) are very rare.

Duplex scan is diagnostic, but contrast magnetic resonance imaging or computed tomography is helpful



Figs 4A to D: (A) Photograph of the excised specimen with multiple ligated vascular stumps on the surface; (B) cut section of the specimen showing grey-white areas and the transverse section of the carotid artery; (C) (low power); and (D) (high power) — histopathological examination showing nests of chief cells, hyalinization and abundant vascularity suggestive of carotid body paraganglioma

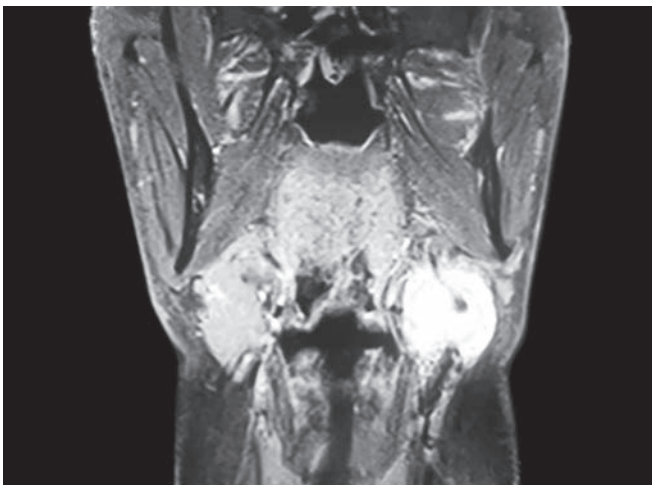


Fig. 5: Contrast spiral computed tomography scan showing single, contrast-filled, ovoid mass in the region of left carotid bulb, splaying the left common carotid artery bifurcation

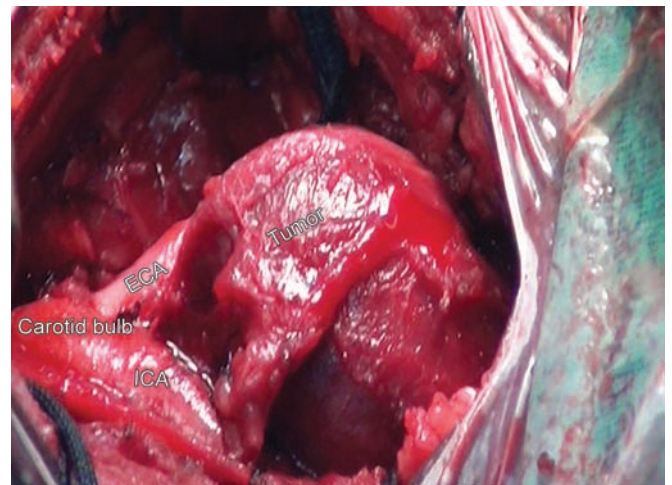

Fig. 6: Intraoperative photograph showing the tumor arising in the region of carotid bulb, splaying the left common carotid artery bifurcation

in planning surgery. Lyre sign (splaying of the carotid artery bifurcation by the densely vascular mass) is characteristic.⁴ Whole-body imaging to detect multicentricity/metastases is not routinely done. Inadvertent biopsy can cause profuse bleeding and/or cranial nerve injuries.

Surgical resection is the gold standard for treatment of carotid body paraganglioma. Shamblin's

classification is used for risk stratification. Overall, surgery is associated with 1% mortality and 33% morbidity (cranial nerve damage, stroke, Horner's syndrome, and wound hematoma).² Preoperative embolization is an adjunctive tool and can be undertaken only if feeding vessels can be subselectively catheterized and determined not to allow free reflux of contrast into the ICA.⁵

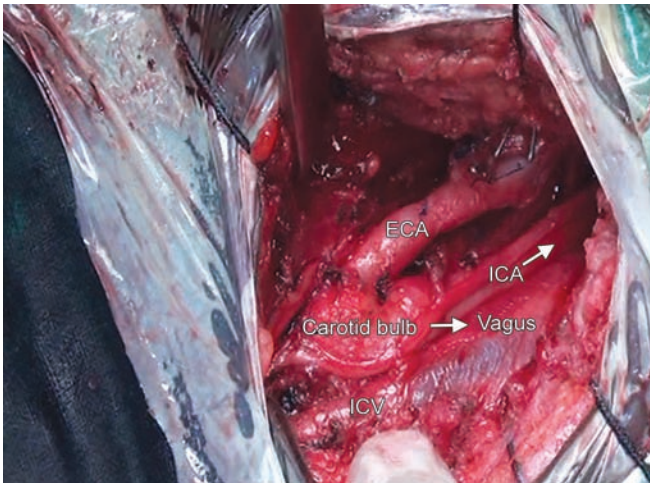


Fig. 7: Intraoperative photograph showing the carotid arteries (carotid bulb, ECA, and ICA), IJV, and vagus nerve after excision of the tumor

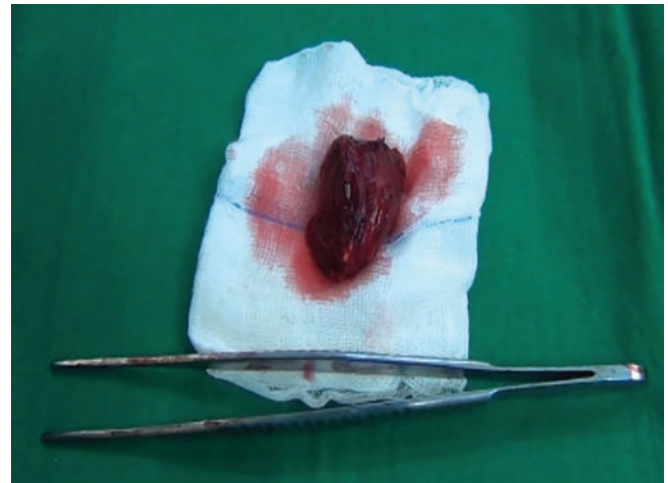
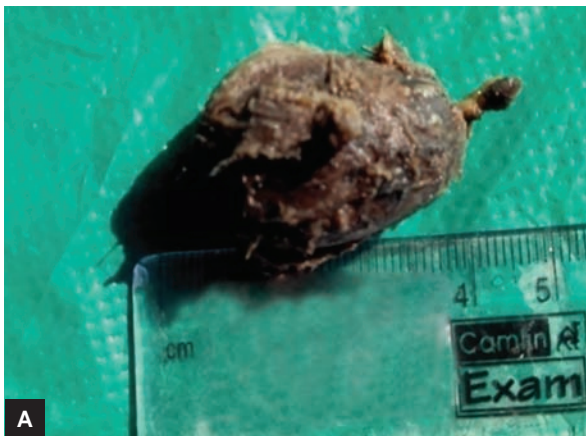
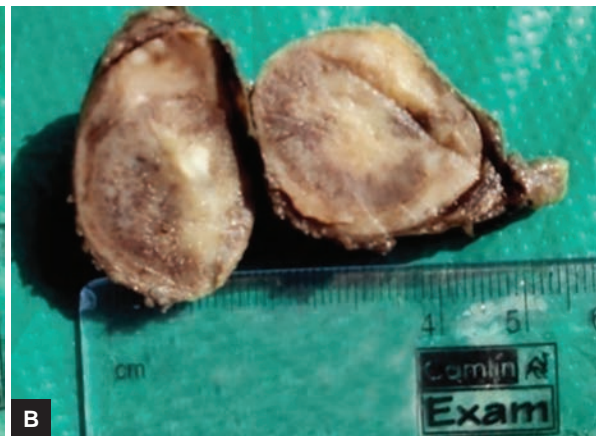


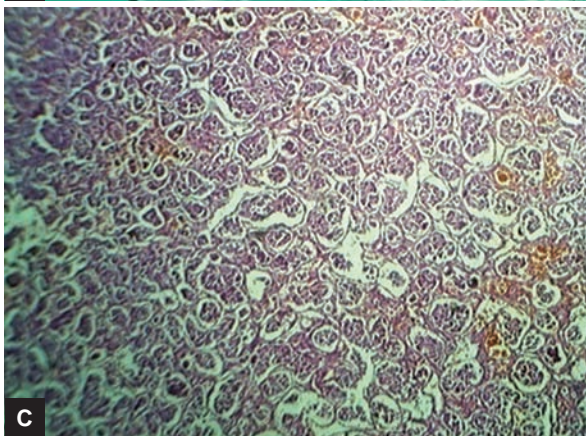
Fig. 8: Excised tumor



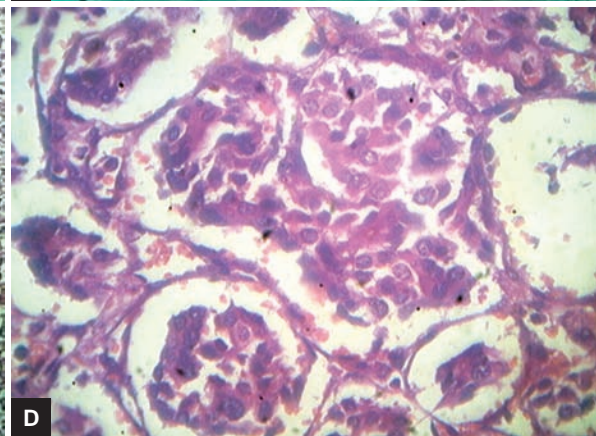
A



B



C



D

Figs 9A to D: (A) Photograph of gross specimen showing globoid mass; (B) cut section showing solid gray-brown mass with areas of hemorrhage; (C) photomicrograph showing tumor cells arranged in a nested pattern separated by fibrous septae – Zellballen pattern [hematoxylin and eosin (H&E), 100 \times]; and (D) photomicrograph showing high power view [hematoxylin and eosin (H&E), 400 \times]

REFERENCES

- Georgiadis GS, Lazarides MK, Tsalkidis A, Argyropoulou P, Giatromanolaki A. Carotid body tumor in a 13 years old child: case report and review of the literature. *J Vasc Surg* 2008 Apr; 47(4):874-880.
- Sajid MS, Hamilton G, Baker DM. A multicentric review of carotid body tumor management. *Eur J Vasc Endovasc Surg* 2007 Aug;34:127-130.
- Gardner P, Dalsing M, Weinberger E, Sawchuk A, Miyamoto R. Carotid body tumors, inheritance and a high incidence of associated cervical paragangliomas. *Am J Surg* 1996 Aug;172(2):196-199.
- Knight TT Jr, Gonzalez JA, Rary JM, Rush DS. Current concepts for the surgical management of carotid body tumor. *Am J Surg* 2006 Jan;191(1):104-110.
- Zhang TH, Jiang WL, Li YL, Li B, Yamakawa T. Perioperative approach in the surgical management of carotid body tumors. *Ann Vasc Surg* 2012 Aug;26(6):775-782.