

MINI REVIEW

Genotype–phenotype Correlation in Children with Pheochromocytoma and Paraganglioma

¹Vijaya Sarathi, ²M Sabaretnam, ³Nalini Shah

ABSTRACT

Pheochromocytoma/paraganglioma (PPGL) have been reported to have germline mutations in more than 15 genes. PPGL diagnosed during childhood have the highest heritability (up to 80%). PPGL associated genes are classified into two clusters; cluster 1 (*VHL*, *SDHx*, *EPAS1*, *PDH1*, *PDH2*, *FH*, *MDH2*) and cluster 2 (*RET*, *NF-1*, *TMEM127*, *MAX*). Cluster 1 genes associated PPGL are norepinephrine secreting whereas cluster 2 genes associated PPGL are epinephrine secreting. In children with PPGL, *VHL* mutations are the most common followed by *SDHB* and *SDHD*. Bilateral PCC are frequent in patients with *VHL* mutations whereas extra-adrenal PGL are frequent in *SDHx* mutations. *SDHB* related PPGL are frequently malignant. Genetic testing should be performed in all children with PPGL and prioritization of genetic testing based on clinical characteristics (extra-paraganglial manifestations, location and number of PPGL, biochemical phenotype and metastasis) may be cost-effective.

Keywords: Children, Genotype, Phenotype, Paraganglioma, Pheochromocytoma.

How to cite this article: Sarathi V, Sabaretnam M, Shah N. Genotype–phenotype Correlation in Children with Pheochromocytoma and Paraganglioma. *World J Endoc Surg* 2016;8(3):208-211.

Source of support: Nil

Conflict of interest: None

INTRODUCTION

Pheochromocytoma (PCC) is a tumor that arises from the catecholamine-producing chromaffin cells in the adrenal medulla. It was defined as an intra-adrenal paraganglioma (PGL) by the World Health Organization in 2004.¹ Closely related tumors that arise from

extra-adrenal sympathetic and parasympathetic ganglia are classified as extra-adrenal PGLs. Pheochromocytoma and extra-adrenal sympathetic PGLs commonly secrete catecholamines, whereas parasympathetic PGLs are usually nonfunctional. Sympathetic PGLs are usually located in the abdomen (at aortic bifurcation, para-aortic, and peri-adrenal), pelvis, and thorax, whereas parasympathetic PGLs are most commonly found in the head and neck.¹

Pheochromocytoma and paragangliomas (PPGLs) account for up to 1.7% of children with hypertension.² Although PPGL is rare, it is the most common pediatric endocrine tumor. Estimated incidence of benign PPGL in children is 0.11 per million children, whereas it is 0.02 per million children for malignant PPGL. The PPGLs in children are more likely to be hereditary, bilateral, and extra-adrenal compared with adults.³

ETIOLOGY

The PPGLs carry the highest degree of heritability (around 40%) of all human tumors. The heritability is highest (up to 80%) for PPGL diagnosed during childhood.⁴ Underlying germline mutations have been reported in more than 15 genes so far. Proteins produced by these genes belong to a wide range of functional classes including kinase receptor and signaling regulators [*RET* proto-oncogene (*RET*), neurofibromin 1 (*NF1*)]; transcription factors [such as *MYC*-associated factor X (*MAX*)]; energy metabolism components [such as succinate dehydrogenase (*SDH*) subunits *SDHA*, *SDHB*, *SDHC*, *SDHD*, and cofactor *SDHAF2*, fumarate hydratase (*FH*), prolyl hydroxylase 1 (*PHD1*), *PHD2*, and malate dehydrogenase 2]; constituents of the cellular response to hypoxia [such as von Hippel–Lindau (*VHL*) and hypoxia-inducible factor 2A (*HIF2A*; also known as *EPAS1*)]; and endosomal signaling proteins (such as transmembrane protein 127, *TMEM127*) proteins.⁵ Furthermore, somatic mutations in *NF1*, alpha thalassemia/mental retardation syndrome X-linked (*ATRX*), *VHL*, Harvey rat sarcoma viral oncogene (*HRAS*), *RET*, *MET* proto-oncogene (*MET*), *MAX*, and *HIF2A* can be detected in an additional 25 to 30% of the tumors.⁶

The PPGLs of various genetic backgrounds can be segregated by their transcription profile into two main clusters (cluster 1 and 2) that have helped to guide the

^{1,2}Associate Professor, ³Professor and Head

¹Department of Endocrinology, Vydehi Institute of Medical Sciences and Research Centre, Bengaluru, Karnataka, India

²Department of Endocrine Surgery, Sanjay Gandhi Postgraduate Institute of Medical Sciences, Lucknow, Uttar Pradesh, India

³Department of Endocrinology, Seth Gordhandas Sunderdas Medical College and King Edward Memorial Hospital, Mumbai Maharashtra, India

Corresponding Author: Vijaya Sarathi, Associate Professor Department of Endocrinology, Vydehi Institute of Medical Sciences and Research Centre, Bengaluru, Karnataka, India e-mail: drvijayasarathi@gmail.com

discovery of novel susceptibility genes. Cluster 1 is enriched with genes that are associated with the hypoxic response, and cluster 2 contains tumors that activate kinase signaling and protein translation.⁵ Cluster 1 genes include VHL, components of the SDH complex (SDHA, SDHB, SDHC, and SDHD, as well as SDHAF2), FH, PHD1, PHD2, HIF2A, and MHD2.⁵ Cluster 2, a more heterogeneous group, encompasses PPGLs with RET, NF1, TMEM127, and MAX mutations.⁵

INHERITANCE

All PPGL-related genes are inherited in an autosomal dominant manner. However, in SDHD, SDHAF2, and familial cases of MAX gene mutations, tumor development is generally described only after paternal transmission of the mutation.⁷ This finding is not because of genomic imprinting and is because of parent-of-origin effect. However, recently, three cases of PPGLs with maternal transmission have been reported in SDHD mutation carriers.⁸

AGE AT PRESENTATION

Germline mutations in VHL, SDHB, and SDHD account for a great proportion of hereditary PPGLs during childhood.⁵ In patients who present during the first decade of life, VHL mutations account for the most PPGLs, even among apparently sporadic tumors. Multiple endocrine neoplasia type 2 (MEN2)-associated PCC is usually present in late teenage or young adulthood, whereas those in NF1 present usually in mid- to late adulthood.^{5,9} However, in both syndromes, PPGL can present during childhood. SDHC-, SDHAF2-, MAX-, and TMEM127-associated PPGLs may rarely present during childhood.⁵

BIOCHEMICAL PHENOTYPE

The RET, NF1, and TMEM127-associated PPGLs are epinephrine secreting and are characterized by elevated epinephrine/metanephrine with or without elevation of norepinephrine/normetanephrine, whereas VHL-, SDHx-, FH-, and HIF2A-associated PPGLs do not produce epinephrine and are characterized by elevation of norepinephrine or its metabolite normetanephrine in plasma or urine; they display normal epinephrine and metanephrine levels. MAX-associated PPGLs could be either epinephrine producing or norepinephrine producing.⁶ Most sporadic tumors behave like cluster 2 genes and produce epinephrine. Combination of metanephrine and normetanephrine can discriminate SDHx- and VHL-related PPGLs from those associated

with RET, NF1, and TMEM127 in 99% of the cases. Elevation of plasma methoxytyramine is commonly seen in patients with SDHB and SDHD mutations and discriminates these tumors from those with VHL mutations in approximately 75% of cases.¹⁰ Elevation of plasma methoxytyramine is also a predictor of malignancy.¹¹

TUMOR LOCATION

von Hippel–Lindau-related PPGLs are most commonly adrenal PCCs followed by extra-adrenal thoracoabdominal PGLs (TAPGLs).¹² Very rarely, they are associated with parasympathetic PGL. The PPGLs in SDHB mutation carriers are usually extra-adrenal TAPGL followed by adrenal PCC and head-and-neck PGL (HNPGL).^{5,12} In SDHD, tumors are mostly HNPGL, and less common are adrenal PCC and extra-adrenal TAPGL.^{5,12} In SDHC and SDHAF2, tumors are predominantly HNPGL, though they are often thoracic PGL (SDHC).¹³ The RET, NF1, and TMEM127 tumors are mostly adrenal PCCs, whereas in MAX, tumors are predominantly adrenal and less commonly extra-adrenal TAPGL.^{14,15}

MALIGNANCY

SDHB-associated PPGLs are highly malignant (30–70%); relatively higher rates of malignancy have also been reported in PPGL associated with FH and MAX germline mutations.^{15,16} Similar associations of these genes with high rates of malignant PCC/PGL have also been reported in children.^{15,16}

CHOICE OF NUCLEAR IMAGING

In adults, it has been shown that ¹⁸F-fluoro-deoxy-glucose (FDG) positron emission tomography/computerized tomography (PET/CT) and ¹⁸F-fluoro-dopamine PET are more sensitive in detecting metastasis in SDHB mutation carriers, whereas ¹⁸F-fluoro-dihydroxyphenylalanine PET/CT is more useful to detect non SDHB metastasis.¹⁷ A recent study has also demonstrated the superiority of ⁶⁸Ga-DOTATATE PET/CT in SDHB-related metastasis over the previously mentioned functional imaging methods.¹⁸ The ¹⁸F-FDG PET/CT can differentiate SDHx-related HNPGL from sporadic ones with 80% accuracy.¹⁹ However, no such data are available in children.

Immunohistochemical Staining

Introduction of SDHB immunohistochemical (IHC) could distinguish SDHx-related PPGL (SDHB IHC negative) from nonSDHx-related PPGL with high specificity and sensitivity.²⁰ Recently, positive SDHD immunostaining

has been demonstrated in most of the SDHx-related PPGLs, and it provides additional strength to confirm the SDHx-related PPGL. Negative SDHA immunostaining suggests underlying SDHA mutations.²¹ The MAX IHC is negative in MAX mutations, and 2SC is positive in FH mutations.⁶ These immunostaining characteristics help to prioritize genetic testing among those with the norepinephrine-secreting biochemical phenotype.

PRIORITY OF GENETIC SCREENING

Prioritization of genetic testing would make it more cost-effective.¹² A simple algorithm for prioritization of genetic testing in patients with PPGL is depicted in Flow Chart 1. The first step is to identify those with syndromic presentation and perform targeted genetic testing for them. The components of PPGL-associated syndromes and their surveillance are summarized in Table 1.

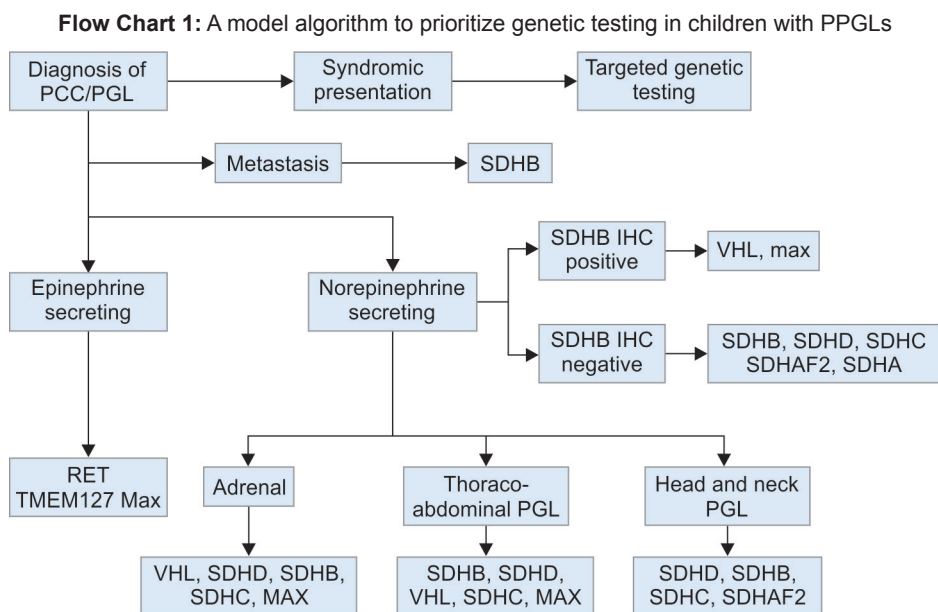


Table 1: Associated features and screening tests recommended in common syndromes associated with PPGL in children

Disease	Associated features	Recommended screening
Neurofibromatosis type 1 (NF1)	Café-au-lait spots, axillary or inguinal freckles, neurofibromas, optic nerve glioma, iris hamartomas, sphenoid bone dysplasia or long bone pseudoarthrosis, first-degree relative with NF1	Blood pressure monitoring every year Ophthalmologic examination every year Plasma-free metanephrines and/or abdominal MRI or CT scan only if hypertension
Multiple endocrine neoplasia (MEN) type 2	Medullary thyroid carcinoma Primary hyperparathyroidism cutaneous lichen amyloidosis (MEN2A) Mucosal ganglioneuromas, typical facies, Marfanoid habitus (MEN2B)	Plasma calcitonin level, USG thyroid and prophylactic thyroidectomy as soon as possible and within first year of life for MEN2B and after 3–5 years of age for MEN2A PPGL (blood pressure and plasma-free metanephrines) and PHPT (serum calcium) screening by 8 years for MEN2B, codon 630, 634 mutations, and by 20 years for other RET mutations every year
von Hippel–Lindau disease	Renal cysts and carcinoma, cerebellar hemangioblastoma, retinal angioma, pancreatic cysts, and neuroendocrine tumors	Age to start screening: 5 years Blood pressure monitoring every year Plasma-free normetanephrine level every year Ophthalmologic examination every year USG abdomen/pelvis every year CT abdomen every 2 years MRI brain and spine every 2 years
SDHx-related hereditary paragangliomas	Carney triad (GIST + pulmonary chondroma) Carney–Stratakis dyad (GIST) 3PAs (pituitary adenoma) Renal cell carcinoma (SDHB)	Age to start screening: 10 years Blood pressure monitoring every year Plasma free normetanephrine ± methoxytyramine level every year CT thorax, abdomen, pelvis every 2 or 3 years MR angiography of head and neck every 2 or 3 years

GIST: Gastrointestinal stromal tumor; MRI: Magnetic resonance imaging; PHPT: Primary hyperparathyroidism; PPGL: Pheochromocytoma and paraganglioma; USG: Ultrasound sonography test

CONCLUSION

Prevalence of germline mutations in children with PCC/PGL is very high. Genetic testing of inherited mutations associated with PPGL helps to predict the tumor behavior (location, biochemical phenotype, malignancy, response to treatment), and, hence, appropriate management. Genetic testing will also help to predict co-occurring cancers and will direct regular screening and early identification/management of these cancers in hereditary syndromes. It will also direct the screening of at-risk relatives facilitating early detection of PPGL and associated cancers in them. Hence, all children with PCC/PGL should undergo genetic testing for PCC/PGL susceptibility genes. A clinically driven prioritization of genetic testing would be more cost-effective.

REFERENCES

- Pacak K, Eisenhofer G, Ahlman H, Bornstein SR, Gimenez-Roqueplo AP, Grossman AB, Kimura N, Mannelli M, McNicol AM, Tischler AS. International Symposium on Pheochromocytoma. Pheochromocytoma: recommendations for clinical practice from the First International Symposium. October 2005. *Nat Clin Pract Endocrinol Metab* 2007 Feb;3(2):92-102.
- Wyszyńska T, Cichońska E, Wieteska-Klimczak A, Jobs K, Januszewicz P. A single pediatric center experience with 1025 children with hypertension. *Acta Paediatr* 1992 Mar;81(3):244-246.
- Havekes B, Romijn JA, Eisenhofer G, Adams K, Pacak K. Update on pediatric pheochromocytoma. *Pediatr Nephrol* 2009 May;24(5):943-950.
- Bausch B, Wellner U, Bausch D, Schiavi F, Barontini M, Sanso G, Walz MK, Peczkowska M, Weryha G, Dall'igna P, et al. Long-term prognosis of patients with pediatric pheochromocytoma. *Endocr Relat Cancer* 2013 Dec;21(1):17-25.
- Castro-Vega LJ, Lepoutre-Lussey C, Gimenez-Roqueplo AP, Favier J. Rethinking pheochromocytomas and paragangliomas from a genomic perspective. *Oncogene* 2016 Mar;35(9):1080-1089.
- Favier J, Amar L, Gimenez-Roqueplo AP. Paraganglioma and pheochromocytoma: from genetics to personalized medicine. *Nat Rev Endocrinol* 2015 Feb;11(2):101-111.
- Hoekstra AS, Devilee P, Bayley JP. Models of parent-of-origin tumorigenesis in hereditary paraganglioma. *Semin Cell Dev Biol* 2015 Jul;43:117-124.
- Bayley JP, Oldenburg RA, Nuk J, Hoekstra AS, van der Meer CA, Korpershoek E, McGillivray B, Corssmit EP, Dinjens WN, de Krijger RR, et al. Paraganglioma and pheochromocytoma upon maternal transmission of SDHD mutations. *BMC Med Genet*. 2014 Oct;15:111.
- Mishra A, Mehrotra PK, Agarwal G, Agarwal A, Mishra SK. Pediatric and adolescent pheochromocytoma: clinical presentation and outcome of surgery. *Indian Pediatr* 2014 Apr;51(4):299-302.
- Eisenhofer G, Lenders JW, Timmers H, Mannelli M, Grebe SK, Hofbauer LC, Bornstein SR, Tiebel O, Adams K, Bratslavsky G. Measurements of plasma methoxytyramine, normetanephrine, and metanephrine as discriminators of different hereditary forms of pheochromocytoma. *Clin Chem* 2011 Mar;57(3):411-420.
- Eisenhofer G, Lenders JW, Siebert G, Bornstein SR, Friberg P, Milosevic D, Mannelli M, Linehan WM, Adams K, Timmers HJ, et al. Plasma methoxytyramine: a novel biomarker of metastatic pheochromocytoma and paraganglioma in relation to established risk factors of tumour size, location and SDHB mutation status. *Eur J Cancer* 2012 Jul;48(11):1739-1749.
- Pandit R, Khadilkar K, Sarathi V, Kasaliwal R, Goroshi M, Khare S, Nair S, Raghavan V, Dalvi A, Hira P, et al. Germline mutations and genotype-phenotype correlation in Asian Indian patients with pheochromocytoma and paraganglioma. *Eur J Endocrinol* 2016 Oct;175(4):311-323.
- Else T, Marvin ML, Everett JN, Gruber SB, Arts HA, Stoffel EM, Auchus RJ, Raymond VM. The clinical phenotype of SDHC-associated hereditary paraganglioma syndrome (PGL3). *J Clin Endocrinol Metab* 2014 Aug;99(8):E1482-E1486.
- Toledo SP, Lourenço DM Jr, Sekiya T, Lucon AM, Baena ME, Castro CC, Bortolotto LA, Zerbini MC, Siqueira SA, Toledo RA, et al. Penetrance and clinical features of pheochromocytoma in a six-generation family carrying a germline TMEM127 mutation. *J Clin Endocrinol Metab* 2014 Nov;100(2):E308-E318.
- Burnichon N, Cascón A, Schiavi F, Morales NP, Comino-Méndez I, Abermil N, Inglada-Pérez L, De Cubas AA, Amar L, Barontini M, et al. MAX mutations cause hereditary and sporadic pheochromocytoma and paraganglioma. *Clin Cancer Res* 2012 May;18(10):2828-2837.
- Clark GR, Sciacovelli M, Gaude E, Walsh DM, Kirby G, Simpson MA, Trembath RC, Berg JN, Woodward ER, Kinning E, et al. Germline FH mutations presenting with pheochromocytoma. *J Clin Endocrinol Metab* 2014 Jul;99(10):E2046-E2050.
- Timmers HJ, Chen CC, Carrasquillo JA, Whatley M, Ling A, Havekes B, Eisenhofer G, Martiniova L, Adams KT, Pacak K. Comparison of 18F-fluoro-L-DOPA, 18F-fluoro-deoxyglucose, and 18F-fluorodopamine PET and 123I-MIBG scintigraphy in the localization of pheochromocytoma and paraganglioma. *J Clin Endocrinol Metab* 2009 Dec;94(12):4757-4767.
- Janssen I, Blanchet EM, Adams K, Chen CC, Millo CM, Herscovitch P, Taieb D, Kebebew E, Lehnert H, Fojo AT, et al. Superiority of [68Ga]-DOTATATE PET/CT to other functional imaging modalities in the localization of SDHB-associated metastatic pheochromocytoma and paraganglioma. *Clin Cancer Res* 2015 Sep;21(17):3888-3895.
- Blanchet EM, Gabriel S, Martucci V, Fakhry N, Chen CC, Deveze A, Millo C, Barlier A, Pertuit M, Loundou A, et al. ¹⁸F-FDG PET/CT as a predictor of hereditary head and neck paragangliomas. *Eur J Clin Invest* 2014 Mar;44(3):325-332.
- van Nederveen FH, Gaal J, Favier J, Korpershoek E, Oldenburg RA, de Bruyn EM, Sleddens HF, Derkx P, Rivière J, Dannenberg H, et al. An immunohistochemical procedure to detect patients with paraganglioma and pheochromocytoma with germline SDHB, SDHC, or SDHD gene mutations: a retrospective and prospective analysis. *Lancet Oncol* 2009 Aug;10(8):764-771.
- Menara M, Oudijk L, Badoual C, Bertherat J, Lepoutre-Lussey C, Amar L, Iturrioz X, Sibony M, Zinzindohoué F, de Krijger R, et al. SDHD immunohistochemistry: a new tool to validate SDHx mutations in pheochromocytoma/paraganglioma. *J Clin Endocrinol Metab* 2014 Nov;100(2):E287-E291.