

Behrs' Triangle: The Surgical Anatomy

Vikas Jain

ABSTRACT

Thyroidectomy is a commonly performing surgery worldwide with known complications of recurrent laryngeal nerve injury (RLN) and vocal cord paralysis. To avoid RLN palsy, various methods of RLN identification have been defined, one of which is called as defining Behrs' triangle.

Keywords: Behrs' triangle, Landmark, Thyroidectomy.

How to cite this article: Jain V. Behrs' Triangle: The Surgical Anatomy. *World J Endoc Surg* 2017;9(1):35.

Source of support: Nil

Conflict of interest: None

INTRODUCTION

Thyroidectomy is a commonly performing surgery worldwide with known complications of recurrent laryngeal nerve injury (RLN) and vocal cord paralysis.

To avoid RLN palsy, various methods of RLN identification have been defined, one of which is called as defining Behrs' triangle.

Behrs' triangle (Fig. 1) is bounded by common carotid artery as base, inferior thyroid artery superiorly and RLN as lower arm of triangle. Recognizing the boundaries of triangle posterior to thyroid after retracting the ipsilateral thyroid lobe medially, helps in avoiding injury to RLN.

Description of this triangle was first given by OH Beahr and mentioned in a very few texts. Usefulness of these landmarks is beneficial for surgical anatomy literature. Operative illustration of this surgical landmark is not yet available in online English literature.

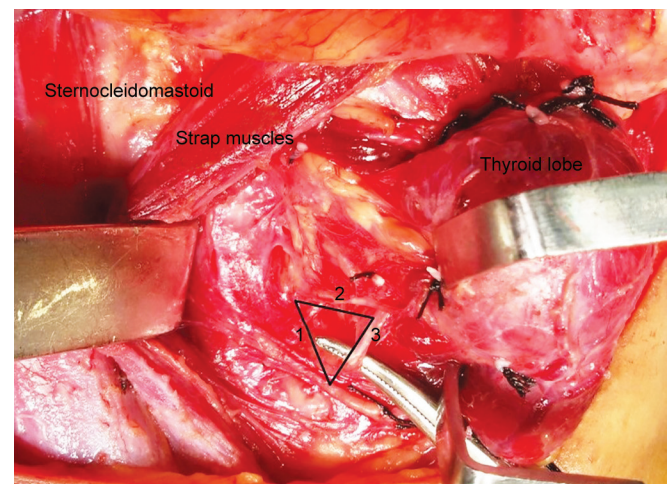


Fig. 1: Behrs' triangle: 1. Common carotid artery; 2. inferior thyroid artery; and 3. recurrent laryngeal nerve; seen after retracting the thyroid lobe medially and strap muscle laterally

Senior Registrar

Department of Surgical Oncology, Asian Cancer Center, Asian Institute of Medical Sciences, Faridabad, Haryana, India

Corresponding Author: Vikas Jain, Senior Registrar
Department of Surgical Oncology, Asian Cancer Center, Asian Institute of Medical Sciences, Faridabad, Haryana, India, Phone: +918468808583, e-mail: drvickyjain@gmail.com

