

Management of Post-thyroidectomy Scar?

¹Sabaretnam Mayilvaganan, ²Sapana Bothra, ³Panchangam R Bhargav, ⁴Aromal Chekavar, ⁵Suneel Mattoo, ⁶Mohd Rashid, ⁷Amit Agarwal

ABSTRACT

Due to cultural and social pressures, emphasis on cosmesis after thyroidectomy has become an important issue which has led to the emergence of many novel scarless in the neck procedures. However novel procedures have cost issues. Young thyroid surgeons need to be trained in producing an acceptable scar by paying attention to tissue handling and refining techniques of skin closure. As awareness increases patients will demand thyroid surgeons to deal with post thyroidectomy scar. We describe how we deal with the post thyroidectomy scar.

Keywords: Scar, Thyroidectomy, Tissue handling

How to cite this article: Mayilvaganan S, Bothra S, Bhargav PR, Chekavar A, Mattoo S, Rashid M, Agarwal A. Management of Post-thyroidectomy Scar? World J Endoc Surg 2018;10(3):176-178.

Source of support: Nil

Conflict of interest: None

INTRODUCTION

What was a condemnable procedure, persecuting surgeons doing thyroidectomy as criminals a century ago, has come off age. With advances in asepsis, anesthesia, and hemostasis, thyroidectomy has become a routine surgery. In the modern era, thyroidectomy is safe and has acceptable complication rates, and now patients are concerned about cosmesis. Performing thyroidectomy through a small incision increases the risk of complications. An incision of less than 3 cm is supposed to be associated with good cosmesis and also good quality of life; this differentiates these minimally invasive techniques from traditional techniques. To minimize or negate a scar, many novel techniques have become established (endoscopic thyroidectomy or robotic). However, these techniques have their complications and limitations. A well-performed thyroidectomy with adequate incision can result in good cosmesis with good quality of life and minimal complications.¹⁻⁴ Patient satisfaction following

thyroidectomy has independently correlated with scar length. In this article, we have tried to address the issue of management of scar following open thyroid surgery.

Wound Healing and Scar

It is divided into three main processes inflammation, proliferation and remodeling? Inflammatory phase commences with disruption in capillary blood vessels and induction of hemostatic cascade. The fibrin clot is formed which is composed of fibrin mesh and platelets. Proliferative phase begins around day 4 or 5 with the migration of fibroblasts, and by 2 to 4 weeks fibroblasts are maximally up-regulated and replace the fibrin. Wound contraction begins around day 10 to 12, but timing can be variable. Remodeling phase begins weeks after the tissue injury with decreased fibroblast count, occlusion of blood vessels and hardening of collagen fibers. Continuous production of collagen and degradation affects the wound remodeling and takes place up to 6 months post wound injury. Understanding these three phases, we can try to optimize wound healing. Modifiable factors include incision design, atraumatic handling of tissues during surgery, good hemostasis, aseptic hemostasis, and tension reduction.⁵ In scar prevention, many factors are involved, but the single most important modifiable factor is wound tension. Langer's lines and relaxed skin tension lines run parallel to the main collagen bundle in the dermis. If an improper incision is made then the chance of hypertrophic scar is high.

Blood supply is a significant factor in wound healing and areas of the skin with rich blood supply heal with favorable scars⁵ (Fig. 1).

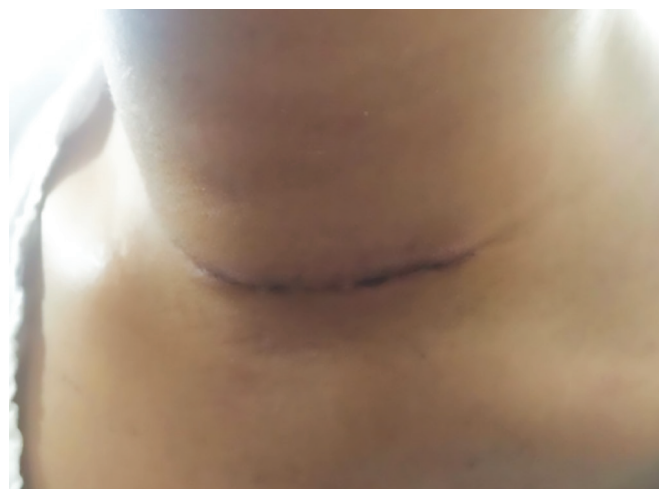

Fig. 1: A good postoperative scar

¹Assistant Professor, ^{2,4-6}Senior Resident, ³Consultant, ⁷Professor

^{1,2,4-7}Department of Endocrine Surgery, Sanjay Gandhi Postgraduate Institute of Medical Sciences, Lucknow, Uttar Pradesh, India

³Department of Endocrine Surgery, Endocare Hospital, Vijayawada, Andhra Pradesh, India

Corresponding Author: Sabaretnam Mayilvaganan, Assistant Professor, Department of Endocrine Surgery, Sanjay Gandhi Postgraduate Institute of Medical Sciences, Lucknow, Uttar Pradesh, India, e-mail: drretnam@gmail.com

Preoperative Counselling

Clinical management of scar begins with thorough counseling of the patient by the treating endocrine surgeon, and before any elective surgery patient should be aware of scar formation which can in some instances be excessive [hypertrophic or Keloid (Fig. 2)]. The patient should also be explained the need for oncological clearance in case of malignancy and the need for re-operative surgery in case of indeterminate nodules. Clinical history also includes the history of any scar tendency to injuries in the past. Even some individuals, families, communities have increased scar tendency.⁶ Especially, people with darker, thicker and sweaty skins have scar tendency and should be counseled about its possibility and also the subsequent care of scar.

Intraoperative Techniques

An adequate Kocher's incision 4 to 6 cm along the skin crease after placement of transparent film dressing (Tegaderm) can make the scar acceptable postoperatively by minimizing the skin burns from cautery. The length of the incision depends on the size of the nodule. Asepsis, Absence of tension, an accurate approximation, avoidance of raw surface and atraumatic tissue handling should be employed during the entire procedure. At the end of every wound closure, the endocrine surgeon should remember that the role of the suture is just approximation without tension; collagen and fibroblast heal the wound.⁵ If strap muscles are cut then the approximation of strap muscles with absorbable sutures either continuous or interrupted sutures followed by the approximation of platysma with interrupted or continuous absorbable sutures. When closing the transversely divided strap muscles, closure is not completed laterally, leaving a "weep hole" at each margin.⁷ The division of strap muscle can provide adequate exposure and to some extent decrease the skin

incision length. Some groups do not approximate platysma. The platysma is generally sutured with absorbable suture (Polyglactin 3-0) with small bites (0.5 cm) which results in good approximation. The recent randomized control trial of platysma closure vs. no closure concluded that there is less pain when platysma not closed with any difference in cosmesis and wound healing.⁸ Once this is done, skin can be approximated with subcuticular absorbable sutures. We then apply adhesive strips (steri-strips), and it is a personal preference of the surgeon to apply ice pack on the wound. A single gauze dressing using surgical tape (micropore plaster) is then applied which is removed on the next morning.

Postoperative Advice

The first few days we look for erythema or inflammation (Fig. 3), and we have the adhesive strip (steri-strips) in place. We clean the wound with saline to maintain its hydration. If non-absorbable sutures are placed then they should be removed at the earliest possible to minimize scar formation. We recommend the patient to have an adhesive strip (steri-strips) placed over the incision for 2 weeks to reduce tension. Then we have a protocol of moisturizing skin cream with vitamin E 1% w/w and aloe vera 10% w/w or silicone gel based ointment which has to be applied daily. One week after incision the tensile strength across the incision is 3% but becomes 20% around 3 weeks when the remodeling begins. Silicon-based cream or silicone gel sheets are believed to decrease the size of the scar by an increase in hydration, oxygen tension and local temperature.⁹ After a month we advise the patients gently massage which increases the flexibility of the scar. Massage reduces the pain explained by the gate theory and also promotes vagal activity which results in more relaxation and reduced peripheral vasoconstriction¹⁰ (Algorithm-1).

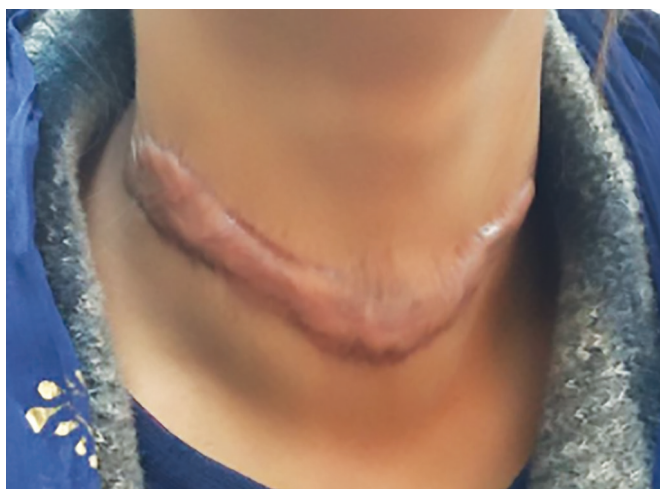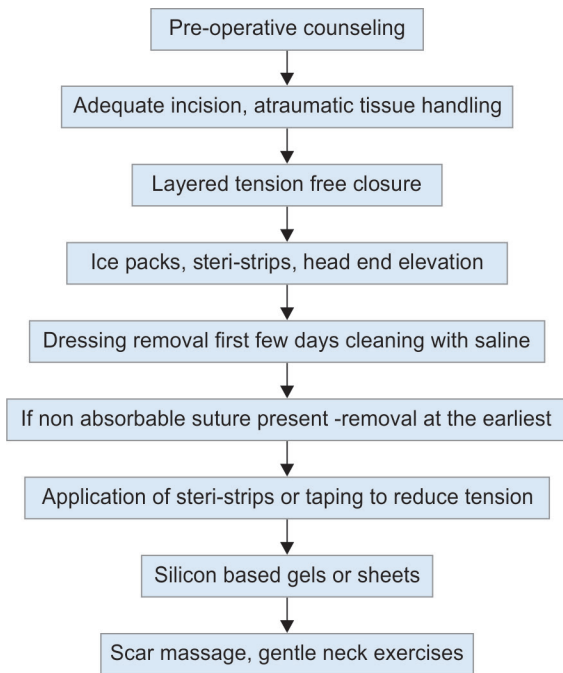


Fig. 2: Keloid after thyroidectomy

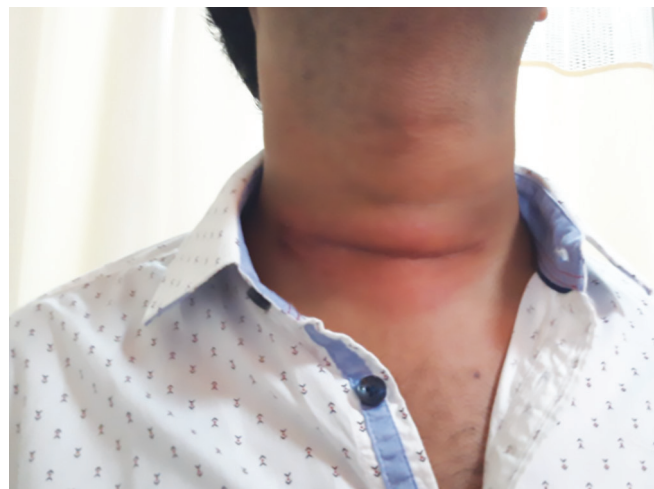

Fig. 3: Erythema postoperatively

Management of Post-thyroidectomy scar (Algorithm-1)



CONCLUSION

A well-planned surgery done by an experienced surgeon with due respect to the tissues and an aware patient can lead to good quality scar and life after thyroidectomy.

REFERENCES

1. Linos D, Economopoulos KP, Kiriakopoulos A, Linos E, Petralias A. Scar perceptions after thyroid and parathy-

- roid surgery: comparison of minimal and conventional approaches. *Surgery*. 2013 Mar 1;153(3):400-407.
2. Toll EC, Loizou P, Davis CR, Porter GC, Pothier DD. Scars and satisfaction: do smaller scars improve patient-reported outcome?. *European Archives of Oto-Rhino-Laryngology*. 2012 Jan 1;269(1):309-313.
3. Choi Y, Lee JH, Kim YH, Lee YS, Chang HS, Park CS, Roh MR. Impact of postthyroidectomy scar on the quality of life of thyroid cancer patients. *Annals of Dermatology*. 2014 Dec 1;26(6):693-699.
4. Arora A, Swords C, Garas G, Chaidas K, Prichard A, Budge J, et al. The perception of scar cosmesis following thyroid and parathyroid surgery: A prospective cohort study. *International Journal of Surgery*. 2016 Jan 1;25:38-43.
5. Son D, Harijan A. Overview of surgical scar prevention and management. *Journal of Korean medical science*. 2014 Jun 1;29(6):751-757.
6. Miller MC, Nanchahal J. Advances in the modulation of cutaneous wound healing and scarring. *BioDrugs*. 2005 Nov 1;19(6):363-381.
7. Reeve T, Thompson NW. Complications of thyroid surgery: how to avoid them, how to manage them, and observations on their possible effect on the whole patient. *World journal of surgery*. 2000 Aug 1;24(8):971-975.
8. Senne M, Zein R, Falch C, Kirschniak A, Koenigsrainer A, Müller S. Randomized clinical trial of platysma muscle suture versus no suture for wound closure after thyroid surgery. *British Journal of Surgery*. 2018 May;105(6):645-649.
9. Stavrou D, Weissman O, Winkler E, Yankelson L, Millet E, Mushin OP, Liran A, Haik J. Silicone-based scar therapy: a review of the literature. *Aesthetic plastic surgery*. 2010 Oct 1;34(5):646-651.
10. Field T, Peck M, Hernandez-Reif M, Krugman S, Burman I, Ozment-Schenck L. Postburn itching, pain, and psychological symptoms are reduced with massage therapy. *The Journal of burn care & rehabilitation*. 2000 May 1;21(3):189-193.