

# Characteristic Computed Tomography Findings in Adrenocorticotrophic Hormone-independent Macronodular Adrenal Hyperplasia: “Bunch of Grapes”

<sup>1</sup>Roma Pradhan, <sup>2</sup>Amit Agarwal, <sup>3</sup>Sushil Gupta

## ABSTRACT

Adrenocorticotrophic hormone (ACTH)- independent macronodular adrenal hyperplasia is an infrequent cause of Cushing’s syndrome and may be confused with diffuse nodular or bilateral macro nodular hyperplasia (AIMAH) resulting from chronic stimulation by ACTH in Cushing’s disease or ectopic ACTH secretion. On Computed tomography (CT) scan adrenal glands can be massively enlarged and bilateral nodules of soft tissue density measuring up to 5 cm distorting normal adrenal glands. Here we have a case of AIMAH in which CT scan revealed massively enlarged bilateral adrenal glands with multiple nodules giving an appearance of ‘bunch of grapes’.

**Keywords:** Adrenocorticotrophic hormone-independent macronodular adrenal hyperplasia, Bilateral, Micronodular and adrenal

**How to cite this article:** Pradhan R, Agarwal A, Gupta S. Characteristic Computed Tomography Findings in ACTH-independent Macronodular Adrenal Hyperplasia: “Bunch of Grapes”. *World J Endoc Surg* 2018;10(3):179-180.

**Source of support:** Nil

**Conflict of interest:** None

## INTRODUCTION

A 55-year-old gentleman presented to the OPD with complaints of headache for 4 years and was also detected to be hypertensive 2 years back. He also complained of facial puffiness and weight gain along with history suggestive of recent onset of proximal muscle weakness. The patient had a history of renal stones and Cerebrovascular accident (CVA) 2 years back. There was no history of any steroid intake or any significant family history. On examination, he had round facies with centripetal obesity, thin skin, and ecchymosis. There was evidence of dermal fungal infection. So clinically a diagnosis of Cushing’s syndrome was made. He was evaluated for hypercortisolism and his biochemical

investigations were confirmatory of ACTH independent Cushing’s syndrome: basal cortisol: 749.1 nmol/L; Low-Dose Dexamethasone-Suppression Test (LDDST): 786.4 nmol/L; HDDST: 868.3 nmol/L; ACTH ( 11:00 PM): 6.824 pg/mL. CT scan revealed massively enlarged bilateral adrenal glands with multiple nodules giving an appearance of ‘bunch of grapes’ (Fig. 1). He underwent bilateral adrenalectomy but because of comorbidities he developed multiorgan failure and succumbed. The combined adrenal gland weight was 346 gm (Fig. 2) and HPE revealed multiple yellow nodules, largest being > 3cm (Fig. 3).

This form of adrenal hyperplasia is an infrequent cause of CS. This form of adrenal hyperplasia may be confused with diffuse nodular or bilateral macronodular hyperplasia resulting from chronic stimulation by ACTH in Cushing’s disease or ectopic ACTH secretion. AIMAH can now be clearly distinguished as an entity in which ACTH becomes progressively suppressed as the primary adrenal enlargement produces sufficient cortisol excess to inhibit the HP axis.<sup>1,2</sup> It may present as an incidental radiological finding or with subclinical or overt Cockayne Syndrome (CS). On CT scan adrenal glands can be massively enlarged and bilateral nodules of soft tissue density measuring up to 5 cm distorting normal adrenal glands,<sup>3,4</sup> these hypodense nodules enhance markedly after contrast. Aberrant adrenal expression causes abnormal regulation of steroidogenesis. Treatment includes pharmacological blockade of aberrant

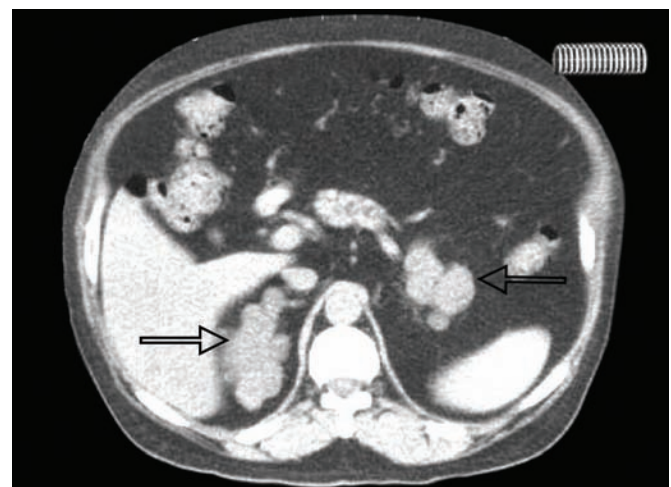


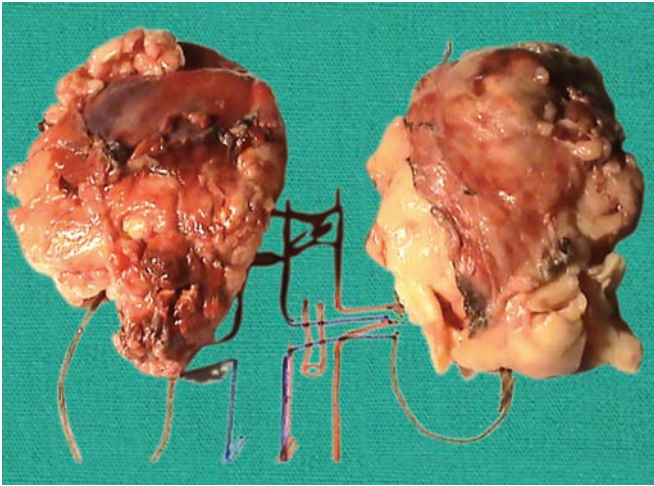
Fig 1: CT findings in AIMAH “Bunch of Grapes”

<sup>1,3</sup>Assistant Professor, <sup>2</sup>Professor

<sup>1</sup>Department of Endocrine Surgery, Dr. Ram Manohar Lohia Institute of Medical Sciences, Lucknow, Uttar Pradesh, India

<sup>2,3</sup>Department of Endocrine Surgery, Sanjay Gandhi Postgraduate Institute of Medical Sciences, Lucknow, Uttar Pradesh, India

**Corresponding Author:** Roma Pradhan, Assistant Professor, Department of Endocrine Surgery, Dr. Ram Manohar Lohia Institute of Medical Sciences, Lucknow, Uttar Pradesh, India, e-mail: drromapradhan@yahoo.com

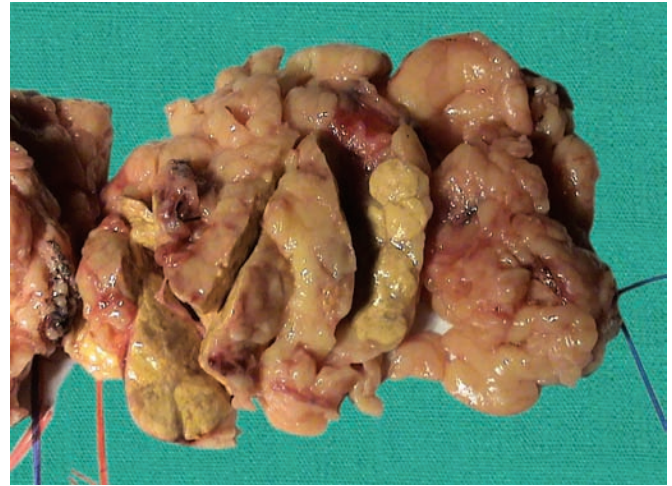


**Fig. 2:** Bilateral adrenalectomy specimen weighing 160 and 186 grams each

receptors or unilateral or bilateral adrenalectomy. Combined adrenal weight is usually >60 gm and can reach up to 200 gm per gland; this in contrast to adrenal weight in patients with ACTH dependent Cushing's disease where the glands are usually less than 30 gm.<sup>5,6</sup>

## REFERENCES

1. Lacroix A, Ní Diaye N, Tremblay J, Hamet P. Ectopic and abnormal hormone receptors in adrenal Cushing's syndrome. *Endocrine Reviews*. 2001;22(1):75-110.
2. Lieberman SA, Eccleshall TR, Feldman D. ACTH-independent massive bilateral adrenal disease (AIMBAD): a subtype of Cushing's syndrome with major diagnostic and therapeutic implications. *European Journal of Endocrinology* 1994;131: 67-73.



**Fig. 3:** Gross picture shows multiple golden yellow nodules largest measuring 3 cm

3. Doppman JL, Chrousos GP, Papanicolaou DA, Stratakis CA, Alexander HR, Nieman LK. Adrenocorticotropin-independent macronodular adrenal hyperplasia: an uncommon cause of primary adrenal hypercortisolism. *Radiology*. 2000 Sep;216(3):797-802.
4. Rockall AG, Babar SA, Sohaib SA, Isidori AM, Diaz-Cano S, Monson JP, et al. CT and MR imaging of the adrenal glands in ACTH-independent cushing syndrome. *Radiographics*. 2004 Mar;24(2):435-452.
5. Smals AG, Pieters GF, van Haelst UJ, Kloppenborg PW. Macronodular adrenocortical hyperplasia in long-standing Cushing's disease. *J ClinEndocrinolMetab* 1984;58:25-31
6. Ohashi A, Yamada Y, Sakaguchi K, Inoue T, Kubo M, Fushimi H. A natural history of adrenocorticotropin-independent bilateral adrenal macronodular hyperplasia (AIMAH) from preclinical to clinically overt Cushing's syndrome. *Endocr J* 2001;48:677-683.