

Poor Man's Intraoperative Neuromonitoring in Thyroid Surgery

Sabaretnam Mayilvaganan¹, Ashutosh Chaurasia², VVSSVAMS Mahalakshmi D³, PRK Bhargava⁴, Aromal Chekavar⁵, Amit Agarwal⁶, Asish Kannaujia⁷

ABSTRACT

In the present day, modern thyroid surgery, the endocrine surgeon, and the patient have the option of many different modalities of technology that has revolutionized thyroid surgery at the expense of increased financial burden, and insurance is not available to cover these new technologies in the developing world. We describe our "poor man's neuromonitoring" where the only thing the surgeon needs is the intent to have a conversion intermittently and this guides the knife-happy surgeon near recurrent laryngeal nerve (RLN) dissection.

Keywords: Nerve monitoring, Recurrent laryngeal nerve, Thyroidectomy.

World Journal of Endocrine Surgery (2020): 10.5005/jp-journals-10002-1300

INTRODUCTION

In the present day, modern thyroid surgery, the endocrine surgeon, and the patient have the option of many different modalities of intervention including various surgical options depending on the need of the patient the goiter characteristics, and finally surgeon's expertise. In a developing country like India, the surgeon has to judiciously use the technology, since the financial burden is a real problem and many of the patients spend money from their own pocket and very few patients have insurance covering the entire medical care.^{1,2} So, the surgeon has an ethical issue to manage all patients with the best possible care and also to take care of these issues. The option of many different gadgets like intraoperative neuromonitoring parathyroid hormone (PTH) measurement after thyroidectomy and auto/artificial fluorescence for parathyroid viability have revolutionized thyroid surgery.^{3,4}

PROCEDURE

In this context, the simple procedure of thyroidectomy under the cervical block with or without sedation can be possible in a daycare setting and has the advantage of less cost and good results when compared with thyroidectomy under general anesthesia⁵⁻⁸ if done by an experienced thyroid or endocrine surgeon in a developing country. We always have the facility of standby general anesthesia if any inadvertent issue happens.

ANESTHESIA CONSIDERATIONS

On arrival to the operation, the theater patient is counseled again regarding the procedure both by the anesthetists and by the endocrine surgeon. Intravenous access is established with an 18-G IV cannula. Standard American Society of Anesthesiologists (ASA) monitoring including electrocardiography (ECG), noninvasive blood pressure (NIBP), pulse oximetry (SpO₂), temperature, and end-tidal CO₂ (ETCO₂) using specialized nasal oxygen prongs with an inbuilt sampling line for ETCO₂ monitoring is done.

The patient is given midazolam (1–2 mg), paracetamol (1 g), and diclofenac (75 mg) intravenously before the block. The patient is put in a supine position (Figs 1 to 3). An ipsilateral shoulder on the side of

^{1,3,6}Department of Endocrine Surgery, Sanjay Gandhi Postgraduate Institute of Medical Sciences, Lucknow, Uttar Pradesh, India

^{2,7}Department of Anesthesia, Sanjay Gandhi Postgraduate Institute of Medical Sciences, Lucknow, Uttar Pradesh, India

⁴Department of Endocrine Surgery, Endocare Hospital, Vijayawada, Andhra Pradesh, India

⁵Department of Endocrine Surgery, Travancore Medicity, Kollam, Kerala, India

Corresponding Author: Asish Kannaujia, Department of Anesthesia, Sanjay Gandhi Postgraduate Institute of Medical Sciences, Lucknow, Uttar Pradesh, India, Phone: +91 (0522) 2668004-8 Ext 3200, e-mail: drashishkannaujia77@gmail.com

How to cite this article: Mayilvaganan S, Chaurasia A, Mahalakshmi DVVSSVAMS, et al. Poor Man's Intraoperative Neuromonitoring in Thyroid Surgery. *World J Endoc Surg* 2020;12(2):105–107.

Source of support: Nil

Conflict of interest: None

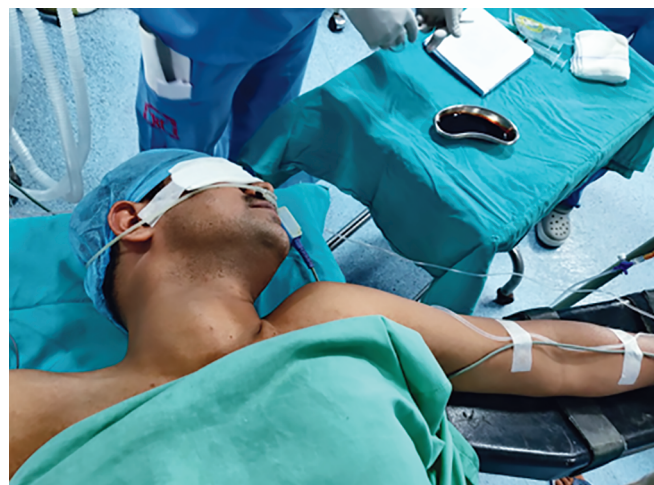

Fig. 1: Position of the patient for superficial cervical block



Fig. 2: Marking for superficial cervical block

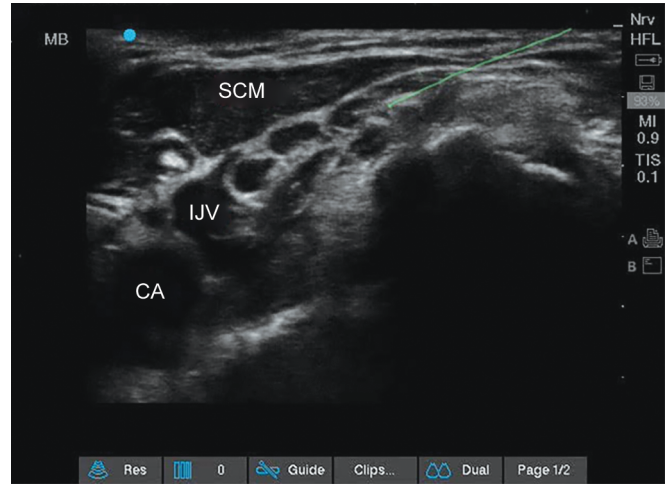


Fig. 3: Superficial cervical plexus transverse view, needle position, and path in green. CA, carotid artery; SCM, sternocleidomastoid; IJV, internal jugular vein

the block was propped up and the head turned to the contralateral side. The anterolateral part of the neck is prepared for the block and draped aseptically. A high-frequency linear ultrasound (USG) probe (5–13 MHz) is prepared by covering the probe with a sterile disposable USG cover.

An USG probe is placed transversely at the level of thyroid cartilage on the lateral neck. The sternocleidomastoid muscle is identified. The needle is inserted in-plane from lateral to medial. Superficial cervical plexus lies immediately deep to superficial fascia below the tapered edge of the sternocleidomastoid muscle. Following negative aspiration, 1–2 mL of local anesthetic is injected with a 22-G, 2.5-inch needle. The proper injection site was seen as splitting of fascia, the remaining drug is injected making it a total of 10 mL of bupivacaine 0.25% was injected. The same procedure is followed on the other side of the neck also. After giving block, we assess the effect of a block after 5 minutes by pinprick test. After a desirable effect, we start the surgery (Fig. 3).

SURGICAL PROCEDURE

We use a standard skin crease incision which is liberal to prevent excessive traction. Flaps are raised. Strap muscles are cut using harmonic shears. We use only bipolar cautery except for the flaps. This use of bipolar forceps allows safe hemostasis near a recurrent laryngeal nerve (RLN) and parathyroid glands. We just fill the field with local anesthesia after cutting the strap muscles. Poles are dealt with using Harmonic shears. We do interrupt the closure of the strap muscles and always a drain is inserted.

WHY POOR MAN'S

In this scenario in my experience of 50 thyroidectomies under a superficial cervical block, the patient during such thyroidectomy being awake can help the surgeon by speaking, thereby indirectly testing the RLN and in some cases near the dissection of RLN, patients suddenly complain of voice change or difficulty in breathing which is usually short-lived and improves dramatically with steroids. The swallowing movements can make dissection around RLN difficult and sometimes

dissection of the thyroid from the trachea. All patients postoperatively had a normal voice.

We use the term “poor man's neuromonitoring” where the only thing the surgeon needs is the intent to have a conversion intermittently and this guides the knife-happy surgeon near RLN dissection. The patients recover immediately, take an oral diet 30 minutes after surgery, and are usually discharged the next day morning. The cost incurred is roughly one-fourth of thyroidectomy done under general anesthesia and most patients are discharged early.^{9,10}

PROS

It is cheap and when done well cost-effective, pain relief postoperative is good, and also patient relatives and knife-happy surgeons are happy at the end of the procedure.

CONS

The swallowing movements can make dissection around RLN difficult and sometimes dissection of the thyroid from the trachea. The muscles may twitch and for inexperienced surgeons it is difficult to operate.

PRECAUTIONS

We advise adequate incision. Local anesthesia infiltration in layers as well. Since muscle retraction can cause pain cutting of muscles, minimum retraction. Be patient near the trachea and RLN since swallowing movements may occur. Interrupted closure of strap muscles and drain since local infiltrated in planes.

OUTCOME

All patients who were operated on under superficial cervical block on follow-up had a normal voice and no permanent hypocalcemia. Induration at the block site was present in two patients and one patient had a small hematoma at the block site which resolved spontaneously.

CONCLUSION

This poor man's neuromonitoring is safe and effective in well-selected patients in a resource constraint setting and saves valuable money for the patients.

REFERENCES

1. Balarajan Y, Selvaraj S, Subramanian SV. Health care and equity in India. *The Lancet* 2011;377(9764):505–515. DOI: 10.1016/S0140-6736(10)61894-6.
2. Reddy KS, Patel V, Jha P, et al. Lancet India group for universal healthcare. Towards achievement of universal health care in India by 2020: a call to action. *The Lancet* 2011;377(9767):760–768. DOI: 10.1016/S0140-6736(10)61960-5.
3. Chang JW, Park KW, Jung SN, et al. The most reliable time point for intact parathyroid hormone measurement to predict hypoparathyroidism after total thyroidectomy with central neck dissection to treat papillary thyroid carcinoma: a prospective cohort study. *Eur Arch Otorhinolaryngol* 2020;277(2):549–558. DOI: 10.1007/s00405-019-05693-1.
4. Ritter A, Ganly I, Wong RJ, et al. Intraoperative nerve monitoring is used routinely by a significant majority of head and neck surgeons in thyroid surgery and impacts on extent of surgery—Survey of the American Head and Neck Society. *Head Neck* 2020;42(8):1757–1764. DOI: 10.1002/hed.26093.
5. Snyder SK, Roberson CR, Cummings CC, et al. Local anesthesia with monitored anesthesia care vs general anesthesia in thyroidectomy: a randomized study. *Arch Surg* 2006;141(2):167–173. DOI: 10.1001/archsurg.141.2.167.
6. Plunkett AR, Shields C, Stojadinovic A, et al. Awake thyroidectomy under local anesthesia and dexmedetomidine infusion. *Mil Med* 2009;174(1):100–102. DOI: 10.7205/MILMED-D-01-2908.
7. Gerfo PL. Local/regional anesthesia for thyroidectomy: evaluation as an outpatient procedure. *Surgery* 1998;124(6):975–979. DOI: 10.1016/S0039-6060(98)70037-6.
8. Hochman M, Fee WE. Thyroidectomy under local anesthesia. *Arch Otolaryngology–Head Neck Surg* 1991;117(4):405–407. DOI: 10.1001/archotol.1991.01870160059009.
9. Spanknebel K, Chabot JA, DiGiorgi M, et al. Thyroidectomy using monitored local or conventional general anesthesia: an analysis of outpatient surgery, outcome and cost in 1,194 consecutive cases. *World J Surg* 2006;30(5):813–824. DOI: 10.1007/s00268-005-0384-3.
10. Inabnet WB, Shifrin A, Ahmed L, et al. Safety of same day discharge in patients undergoing sutureless thyroidectomy: a comparison of local and general anesthesia. *Thyroid* 2008;18(1):57–61. DOI: 10.1089/thy.2007.0148.