CASE REPORT

Unilateral Graves' Disease and Papillary Thyroid Carcinoma: Case Report and Review of Literature

Jaspreet Singh[1], Ankit Manglunia[2], Swayamsidha Mangaraj[3], Amitabh Jena[4]

Received on: 15 January 2022; *Accepted on:* 27 December 2022; *Published on:* 15 April 2023

Abstract

Aim: We aim to report a novel association of unilateral Graves' disease with papillary thyroid carcinoma affecting the same lobe.

Background: Graves' disease is characterized by diffuse enlargement of the thyroid gland. Unilateral Graves' disease is a rare clinical entity characterized by enlargement and hyperfunctioning of a single affected thyroid lobe.

Case description: A 29-year-old female presented with thyrotoxic symptoms for the last 1 year. The patient underwent detailed clinical, hormonal, and imaging studies, which confirmed the presence of unilateral Graves' disease. During this evaluation, she was also found to harbor papillary thyroid carcinoma in the same affected lobe. The patient underwent total thyroidectomy, followed by radioactive iodine ablation. Histopathological examination of excised tissue confirmed the presence of papillary thyroid carcinoma.

Conclusion: A diffuse goiter is one of the classical and well-characterized manifestations of Graves' disease. Unilateral Graves' disease is a rare variant of Graves' disease characterized by unilobar involvement. The exact underlying mechanism of unilateral lobar involvement is unknown.

Clinical significance: The association of papillary thyroid cancer and unilateral Graves' disease is unique and has not been described earlier. Due to its rarity, the diagnosis might be easily missed or misdiagnosed.

We have also reviewed and summarized the relevant cases of unilateral Graves' disease reported earlier in the literature.

Keywords: Graves' disease, Hyperthyroidism, Papillary thyroid carcinoma, Thyroid, Unilateral Graves' disease.

World Journal of Endocrine Surgery (2022): 10.5005/jp-journals-10002-1429

Introduction

Graves' disease is one of the commonest causes of thyrotoxicosis seen in routine clinical practice. It is characterized by hyperthyroidism, goiter, and exophthalmos. The frequency of orbitopathy in Graves' disease is 30%, whereas goiter is present in around 50% of the patients at presentation. Graves' disease is characterized by diffuse enlargement of the thyroid gland. Unilateral Graves' disease is an extremely rare entity caused due to the enlargement and hyperfunctioning of a single lobe and is seldom reported in the literature.[1] We report a unique case of a female who presented with unilateral Graves' disease with concurrent papillary thyroid carcinoma. To the best of our knowledge, no such association between unilateral Graves' disease and papillary thyroid carcinoma has been previously described in the literature.

Case Description

A 29-year-old female presented with easy fatigability, weight loss, and palpitations for the last 1 year. Apart from this, she also gave a history of heat intolerance and increased sweating. Her menstrual cycles were regular. Her past history was unremarkable, and there was no history of chronic medication intake. She had not received any head or neck irradiation in the past. There was no family history of thyroid disorder or malignancy. On physical examination, the patient was lean with a body mass index of 17.7 kg/m^2 and the presence of sinus tachycardia (pulse rate—122 beats/minute) was noted. Her blood pressure was 130/70 mm Hg. Inspection of the eyes revealed the presence of lid retraction and lid lag in both eyes (more prominent in the left eye). Fine resting tremors were demonstrated on outstretched hands. There were no signs of thyroid-associated dermopathy. Examination of the thyroid gland revealed an enlarged right lobe of the thyroid gland, which was nontender and firm in consistency. No thyroid bruit was appreciated. In addition to these findings, the left lobe of the thyroid gland was normally palpable. There was no palpable cervical lymphadenopathy.

Thyroid function test revealed elevated levels of total triiodothyronine (414 ng/mL, normal—84–201 ng/mL) and total tetraiodothyronine (24.86 mcg/dL, normal—5.1–14.1 mcg/dL) with suppressed levels of thyroid stimulating hormone (TSH) (<0.005 mIU/mL, normal—0.27–4.2 mIU/mL). Anti-TSH receptor antibody (TRAb) was positive (8.2 IU/L, normal <2 IU/L). Ultrasonography (USG) of the thyroid gland showed an enlarged

[1–3]Department of Endocrinology, Institute of Medical Sciences and SUM Hospital, Bhubaneswar, Odisha, India

[4]Department of Surgical Oncology, Institute of Medical Sciences and SUM Hospital, Bhubaneswar, Odisha, India

Corresponding Author: Swayamsidha Mangaraj, Department of Endocrinology, Institute of Medical Sciences and SUM Hospital, Bhubaneswar, Odisha, India, Phone: +91 9861431077, e-mail: drsmangaraj@gmail.com

How to cite this article: Singh J, Manglunia A, Mangaraj S, *et al.* Unilateral Graves' Disease and Papillary Thyroid Carcinoma: Case Report and Review of Literature. World J Endoc Surg 2022;14(2):51–54.

Source of support: Nil

Conflict of interest: None

Patient consent statement: The author(s) have obtained written informed consent from the patient for publication of the case report details and related images.

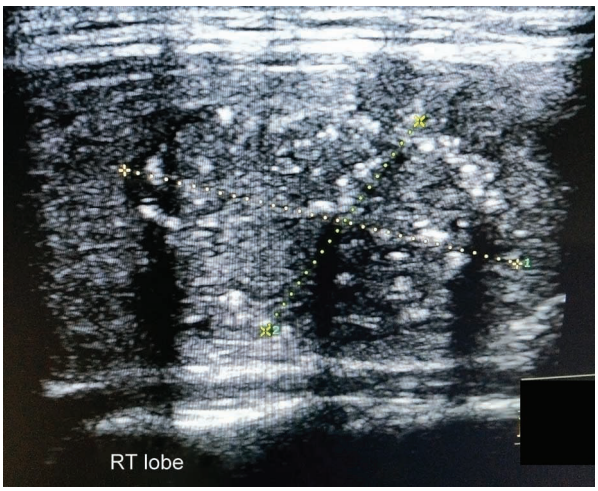

Fig. 1: USG of the thyroid gland showing a solid isoechoic nodule (2.7 × 1.7 cm) with a small cystic component along with multiple punctuate calcific foci in the right lobe

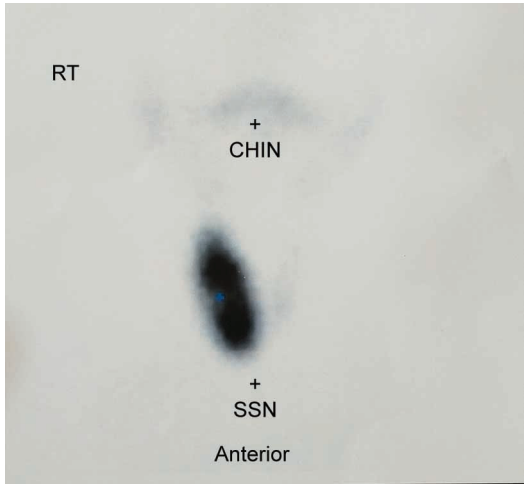

Fig. 2: Tc-99m thyroid can show increased tracer uptake in the right lobe with suppressed uptake in the left lobe. Salivary glands are also faintly visualized

right lobe of the thyroid, with a solid isoechoic nodule with a small cystic component with multiple punctuate calcific foci showing internal vascularity (Fig. 1). Left lobe was normal in size and showed normal parenchymal echotexture. No abnormal neck nodes were appreciated. USG-guided fine-needle aspiration cytology from the suspicious lesion showed features suggestive of papillary thyroid carcinoma. Technetium-99m (Tc-99m) thyroid scan showed intense tracer uptake in the right thyroid lobe with suppressed uptake in the left lobe (Fig. 2). Based on the above findings, a diagnosis of unilateral Graves' disease with concurrent papillary thyroid carcinoma involving the right lobe was made. The patient was started on antithyroid drugs (carbimazole 30 mg/day) and β-blockers for symptomatic management. After the restoration of euthyroid status, the patient underwent a total thyroidectomy. Histopathological evaluation of excised tissue confirmed the presence of papillary thyroid carcinoma (Fig. 3). After the withdrawal of thyroxine supplementation, the patient underwent a whole body radioiodine I-131 scan, which revealed uptake in the thyroid bed. Subsequently, she underwent ablation with 100 mCi of radioiodine I-131 as per the advice of nuclear medicine consultant. Following radioiodine ablation, the whole-body radioiodine I-131 scan did not reveal any neck or distant site uptake. Her serum thyroglobulin was suppressed at 0.2 ng/mL and the antithyroglobulin antibody was negative (3.2 IU/mL, normal < 60 IU/mL). The patient is now on levothyroxine suppressive therapy and is doing well.

Discussion

In Graves' disease, the circulating autoantibodies against the TSH receptor (anti-TSH receptor antibodies/TRAb) lead to uniform diffuse enlargement, as well as hyperfunctioning of bilateral lobes of the thyroid gland. Graves' disease due to the unilateral involvement of the thyroid gland is a rare clinical entity. The first description of this entity was given in 1993 by Sakata et al. when they described two cases of unilateral right-sided Graves' disease in Japanese women.[2] These patients were managed by right hemithyroidectomy. However, both these patients again became thyrotoxic due to hyperfunctioning of the left lobe of the thyroid on follow-up and were subsequently managed by the use of antithyroid drugs (methimazole). We have reviewed the literature regarding unilateral Graves' disease and summarized the findings

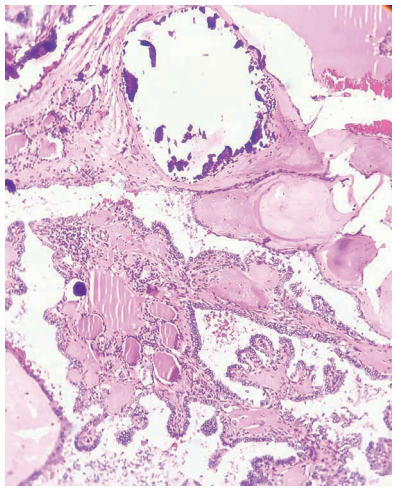

Fig. 3: Photomicrograph showing tumor cells arranged in a papillary pattern along with areas of dystrophic calcification (low-power view)

in Table 1. Among these 26 cases, right lobar involvement was seen in 17 cases, whereas the left side was involved in the rest of the nine cases.[2–11]

The exact mechanism of unilateral lobar involvement is still unknown. The pathophysiology of Graves' disease includes a complex interplay of genetic, hormonal, and environmental factors leading to an autoimmune response to thyroid antigens. The environmental factors lead to different penetrance rates of Graves' disease in genetically susceptible individuals. Several postulations have been put forth to explain the differential involvement of thyroid lobes. There could be preexisting structural or functional changes due to a prior viral inflammation in the silent lobe.[1,2,12] Moreover, the development of both lobes from different precursor cells, including separate lymphatic drainage, may have a role to play.[1,2,12] It is also a known fact that the right lobe is usually larger than the left lobe and it is more frequently affected by nodular and nonnodular pathologies.[5] Some have also hypothesized that there could be a differential expression of antigens between the lobes.[12] It has been suggested that there is evidence of functional heterogeneity in both lobes of the

Table 1: Summary of published cases of unilateral Graves' disease in the literature

	Author (year) (ref)	*Age in years/sex*	*Thyroid lobe*	*TRAb*	*USG*	*Scintigraphy*	*Treatment*	*Outcome*
1	Sakata et al. (1993)[2]	55/female	Right	Negative initially, subsequently positive	Enlarged right lobe with hypoechoic nodule	Increased diffuse uptake in the right lobe	Surgery hemithyroidectomy	Relapse in left lobe with thyrotoxic symptoms after 27 months
2	Sakata et al. (1993)[2]	61/female	Right	Negative initially, subsequently positive	Normal size homogenous lobe	Increased uptake in the right lobe	Hemithyroidectomy	Relapse in left lobe with thyrotoxic symptoms after 6 months
3	Dimai et al. (1999)[3]	31/female	Right	Positive	Enlarged thyroid lobe with no nodular alterations	Four-fold increase in the right lobe with normal uptake in the left lobe	Antithyroid medications	About 2 years later, patient became euthyroid and treatment was stopped
4	Gratz et al. (2004)[4]	33/female	Right	Positive	heterogeneously enlarged right thyroid lobe	Radioisotope uptake was increased in the right lobe	Antithyroid medications	Patient becomes euthyroid with normalization of thyroid hormones
5	Bolognesi and Rossi (2006)[5]	39/male	Right	Positive	Nonhomogenous pattern consistent with thyroiditis	Unilateral increase in thyroid right lobe	Antithyroid medications	Clinical condition along with TRAb, TSH, and free thyroid hormones normalize with treatment
6	Al Juhanni N et al. (2010)[7]	63/male	Right	Not available	The right lobe is enlargedwith a coarse texture and no nodules	Diffuseenlargement of the right lobe with an intense homogenous tracer uptake pattern	Not available	Not available
7	Chen and Green (2011)[8]	48/male	Left	Positive	Nonnodular, heterogeneous, and hypervascular left lobe	An elevated uptake with increased activity distributed uniformly throughout the left-thyroid lobe	Radioactive ablation	Complete resolution of hyperthyroid symptoms
8	Gonulalan and Cakir (2011)[9]	40/male	Right	Negative	The right lobe was enlarged and was having prominent heterogeneity as compared to the left lobe	Diffuse unilateral uptake in the right lobe with suppressed activity in the left lobe	Antithyroid drugs	Not available
9	Eklioglu et al. (2015)[10]	18/female	Right	Positive	Nonnodular heterogenous enlarged right lobe	Increased uptake in the right lobe	Antithyroid drugs	Not available
10	AY SA et al. (2016)[11]	42/female	Right	Positive	Nonhomogenous hypervascular enlarged right lobe	Unilateral uniform uptake in the right lobe	Antithyroid drugs initially planned for radioiodine ablation due to recurrent disease	After 9 months, the patient improved clinically and biochemically. After gradual discontinuation, relapse of symptoms
11	Pande et al. (2019)[1]	35/female	Left	Positive	Nonnodular, heterogeneous enlarged left lobe	Uniform uptake in the left lobe	Antithyroid drugs	After 10 months of antithyroid therapy patient went into remission
12	Manthri et al. (2019)[12]	Age range—26–70 Female—13 Male—2	Right-8 Left-7	Not available	Not available	Eight patients had increased uptake in the right lobe and seven had increased uptake in the left lobe	Antithyroid drugs in eight patients, one underwent radioiodine ablation. Six patients lost to follow-up.	Eight patients responded to antithyroid drugs. One patient became euthyroid after 1 year of radioiodine ablation.

thyroid gland, leading to differential sensitivity of each lobe to TSH or immunoglobulins.[12] The difference in the development of multinodular goiter in both lobes, as in long-standing cases of nontoxic goiter, may be partly explained by the above-suggested mechanism. Another hypothesis put forward to explain the occurrence of unilateral Graves' disease suggests that unilateral lobe involvement may be the initial step in the occurrence of Graves' disease. This may later on progress to a more diffuse form of disease involving bilateral lobes, which is the classical finding of Graves' disease. This postulation is supported by the description of the index case by Sakata et al., where the patient developed features of thyrotoxicosis after initial thyroid surgery due to hyperfunctioning of the remnant lobe.[2] Thirdly, there could be differential expression and function of iodine uptake mechanisms (like Na/I symporter) in each lobe which could lead to heterogeneous findings.[7]

It is a well-known fact that TSH acts as a stimulating factor for the growth and proliferation of differentiated thyroid carcinoma (DTC). Since TSH is suppressed in thyrotoxicosis, it was earlier presumed that thyrotoxic states should be associated with a lower incidence of thyroid cancer, in contrast to euthyroid patients.[13] However, the association of thyroid malignancy and Graves' disease is now well-reported. Papillary thyroid carcinoma represents the most common malignancy reported in association with Graves' disease.[14] DTC cells express TSH receptors in the same fashion as normal thyroid cells. By virtue of their agonistic activity to the TSH receptor, TRAb might play a role in stimulating DTC growth akin to TSH.[15] Furthermore, it has been reported that TRAb stimulates the invasiveness and angiogenesis of DTC.[14,15] A nationwide cohort study reported a 10-fold increased risk of thyroid cancer in subjects of Graves' disease in comparison to non-Graves' cohort, even after adjusting for sex, age, and comorbidities.[16] A recent meta-analysis evaluating the prognosis of DTC in subjects with Graves' disease reported that there was a significantly increased risk of multifocality/multicentricity and distant metastasis at the time of cancer diagnosis in DTC patients with Graves' disease than those subjects who had DTC without Graves' disease.[17] It has been suggested that papillary thyroid carcinoma associated with Graves' disease shows aggressive biological behavior along with an increased risk of progressive distant metastases in Graves' patients than in euthyroid subjects.[18]

Graves' disease is characterized by hyperfunctioning of bilateral lobes, which is clinically evident by symmetrical and diffuse enlargement of both lobes. Unilateral Graves' disease is a rare condition that can present with thyrotoxicosis due to unilobar involvement. This rare variant of Graves' disease might be misdiagnosed due to unawareness about this entity. Imaging studies, such as thyroid ultrasound and nuclear imaging, play a pivotal role in identifying and establishing the diagnosis. Our case exemplifies the rare association of classic papillary thyroid carcinoma in a case of unilateral Graves' disease. Knowledge about this entity among physicians and surgeons caring for such patients could lead to early recognition and optimal management.

References

1. Pande A, Aggarwal A, Wadhwa R. Unilateral Grave's disease: a rare variant. J Clin Diagn Res 2019;13(9):OD06–OD08. DOI: 10.7860/JCDR/2019/42313.13147
2. Sakata S, Fuwa Y, Goto S, et al. Two cases of Graves' disease with presentation of unilateral diffuse uptake of radioisotopes. J Endocrinol Invest 1993;16(11):903–907. DOI: 10.1007/BF03348954
3. Dimai HP, Ramschak-Schwarzer S, Lax S, et al. Hyperthyroidism of Graves' disease: evidence for only unilateral involvement of the thyroid gland in a 31-year-old female patient. J Endocrinol Invest 1999;22(3):215–219. DOI: 10.1007/BF03343545
4. Gratz S, Barth P, Arnold R, et al. Graves' disease with unilateral radioisotope uptake. Nuklearmedizin 2004;43(5):N66–N68. PMID: 15536692.
5. Bolognesi M, Rossi R. Unilateral Graves' disease. Thyroid 2006;16(5):493–495. DOI: 10.1089/thy.2006.16.493
6. Kisakol G, Cakir M, Gungor K, et al. Two cases of Grave's disease presenting with unilateral involvement of the thyroid gland. Turk Jem 2007;11:64–66.
7. Wagih S. Graves' disease affecting one thyroid lobe (unilateral Graves' disease): case report. Egyptian J Nucl Med 2010;2(1):62–65. DOI: 10.21608/egyjnm.2010.5501
8. Chen LC, Green JB. First reported case of unilateral Graves' disease in the left lobe of a bilobar thyroid gland. Thyroid 2011;21(6):683–686. DOI: 10.1089/thy.2010.0343
9. Gönülalan G, Çakır M. Graves' disease with unilateral involvement: a rare entity. Turkish Journal of Endocrinology and Metabolism 2011;15(4):128–129.
10. Eklioglu BS, Atabek ME, Akyurek N, et al. Unilateral Grave's disease in an adolescent: case report. ESPE Abstracts 2015;84:P-3-1219.
11. AY SA, Baskoy K, Urhan M, et al. A rare variant of hyperthyroidism: unilateral Grave's disease. Endocrine Abstracts 2016;41:EP386.
12. Manthri RG, Ajit N, Vaikakkara S, et al. Unilateral Graves' disease: the lesser known. Indian J Nucl Med 2019;34(2):96–98. DOI: 10.4103/ijnm.IJNM_11_19
13. Fiore E, Vitti P. Serum TSH and risk of papillary thyroid cancer in nodular thyroid disease. J Clin Endocrinol Metab 2012;97(4):1134–1145. DOI: 10.1210/jc.2011-2735
14. Fu H, Cheng L, Jin Y, et al. Thyrotoxicosis with concomitant thyroid cancer. Endocr Relat cancer 2019;26(7):R395–R413. DOI: 10.1530/ERC-19-0129
15. Preece J, Grodski S, Yeung M, et al. Thyrotoxicosis does not protect against incidental papillary thyroid cancer. Surgery 2014;156(5):1153–1156. DOI: 10.1016/j.surg.2014.04.025
16. Chen YK, Lin CL, Chang YJ, et al. Cancer risk in patients with Graves' disease: a nationwide cohort study. Thyroid 2013;23(7):879–884. DOI: 10.1089/thy.2012.0568
17. Mekraksakit P, Rattanawong P, Karnchanasorn R, et al. Prognosis of differentiated thyroid carcinoma in patients with Graves disease: a systematic review and meta-analysis. Endocr Pract 2019;25(12):1323–1337. DOI: 10.4158/EP-2019-0201
18. Boutzios G, Vasileiadis I, Zapanti E, et al. Higher incidence of tall cell variant of papillary thyroid carcinoma in Graves' disease. Thyroid 2014;24(2):347–354. DOI: 10.1089/thy.2013.0133