



# 16th Biennial Congress of Asian Association of Endocrine Surgeons

## Poster Presentations

8th to 10th March, 2018

New Delhi, India

Website: [www.asianaes.org](http://www.asianaes.org)

Chairman: Akira Miyauchi

Congress president: Saroj K Mishra, India

## Poster Podium

### Prognosis of Papillary Thyroid Carcinoma in Relation to Preoperative Subclinical Hypothyroidism

<sup>1</sup>Sang Y Kang, <sup>2</sup>Seung J Lee, <sup>3</sup>Hyun J Youn, <sup>4</sup>Sung H Jung

<sup>1-4</sup>Department of Surgery, Chonbuk National University Medical School, Jeonju, South Korea

#### AIM

It has been well known that thyroid-stimulating hormone (TSH) stimulated the growth or development of thyroid malignancy and higher serum TSH is also associated with thyroid cancer incidence and advanced tumor stage. The purpose of this study was to evaluate the association of preoperative hypothyroidism with the prognosis of papillary thyroid cancer (PTC).

#### MATERIALS AND METHODS

A total of 480 patients who underwent surgery for PTC between December 2006 and June 2009 were enrolled in this study. Among them, 66 patients had subclinical thyroiditis (group I) while 414 patients had no subclinical hypothyroidism (group II), as diagnosed in preoperative thyroid function test. The two groups' recurrence rate and association with clinicopathological features were compared.

#### RESULTS

Median age was 46.9 years (17–74 years). There were 437 female and 43 male patients respectively. Median follow-up period was 78.4 (60–104) months. There were no statistical differences between the two groups with respect to age, gender, primary tumor size, extrathyroidal extension, multifocality, lymph node metastasis, TNM stages, recurrence, and disease-free survival, despite significant difference in TSH concentrations between the two groups.

#### CONCLUSION

The results of our study suggest that subclinical hypothyroidism was not associated with tumor aggressiveness and recurrence in PTC.

### Metabolic Effects of Laparoscopic Roux-en-Y Gastric Bypass: Our Experience

<sup>1</sup>Ankush Sarwal, <sup>2</sup>Pradeep Chowbey, <sup>3</sup>Rajesh Khullar, <sup>4</sup>Anil Sharma, <sup>5</sup>Vandana Soni, <sup>6</sup>Manish Bajjal, <sup>7</sup>Rajeev K Agrawal

<sup>1-7</sup>Department of Mambs, Max Super Speciality Hospital and Sarwal Hospital, New Delhi, India

#### INTRODUCTION

Metabolic surgery is defined as the operative manipulation of a normal organ or organ system to achieve a biological result for a potential health gain. Bariatric surgery is the most effective treatment for obesity. Laparoscopic Roux-en-Y Gastric Bypass (RYGB) is a commonly used and recommended bariatric procedure. Its effects go beyond weight loss, in a high percentage of cases achieving remission of comorbidities associated with obesity, such as type II diabetes mellitus, hypertension, dyslipidemia, and reducing complications along with mortality.

## MATERIALS AND METHODS

Retrospective study at a single center was done from November 2009 to March 2017 with total duration of around 7 years.

## RESULTS

A total of 1332 patients underwent with laparoscopic RYGB during 7 years of study with a mean operative time of 127 ( $\pm$ 92) minutes. The median age of the patients was 37 (18–67) years. Average hospital stay was 3.4 days with diabetes resolution in 83%, hypertension resolution in 59% of the operated patients.

## CONCLUSION

Bariatric surgeries are now recognized as metabolic surgeries given the excellent resolution of metabolic derangements accompanying obesity. The metabolic effects and results of RYGB as described in our center and reported in literature support the advantages of RYGB surgery for metabolic comorbidities. Thus, laparoscopic RYGB surgery is safe and effective for excess body weight loss and confers excellent resolution of associated comorbidities.

## Impact of Antiplatelet Therapy and Anticoagulant on Thyroidectomy. Is There Any Risk Other Than Hemorrhage?

<sup>1</sup>KP Wong, <sup>2</sup>PC Wong, <sup>3</sup>PW Siu, <sup>4</sup>KH Yue, <sup>5</sup>BHH Lang

<sup>1-5</sup>The University of Hong Kong, Queen Mary Hospital, Hong Kong

## INTRODUCTION

Antiplatelet therapy is commonly used in patients undergoing thyroidectomy. It was perceived that risk of bleeding would be higher. However, there were limited studies reporting the incidence. It is unclear if these patients had a poor surgical outcome.

## MATERIALS AND METHODS

From January 2006 to December 2015, 3,061 patients undergoing thyroidectomy in our center were included. Demographic, clinical data and usage of antiplatelet agent were prospectively collected. Surgical outcomes were compared between patients with antiplatelet (AP group) and patient without anti-platelet therapy (non-AP group).

## RESULTS

A total of 2,496 (81.3%) patients were female and 135 (4.4%) were taking antiplatelet agent. Patients were older, male predominant, and likely to have cardiovascular disease in AP ( $p < 0.05$ ). Despite increased medical risk, rate of nonsurgical related complication was comparable between AP and non-AP group (0.7 vs 0.7%,  $p = 0.973$ ). There was no difference in neck hematoma in patients taking anti-platelet agents (0.7 vs 0.7%,  $p = 0.937$ ). On multivariate analysis, usage of antiplatelet agents was the independent risk factor for overall hypocalcemia [odds ratio (OR) 1.56,  $p = 0.041$ ] and permanent hypocalcemia (OR 2.57,  $p = 0.008$ ).

## CONCLUSION

Use of antiplatelet agents does not increased risk of post-thyroidectomy neck hematoma in experienced hands. However, there is an increased risk of hypocalcemia. For patients taking antiplatelet agents, day surgery should not be recommended and monitoring of postoperative calcium level should be mandatory.

## Video-assisted Thoracoscopic Excision of Mediastinal Ectopic Parathyroid Adenomas: Our Experience

<sup>1</sup>Rajinder Parshad, <sup>2</sup>Suhani, <sup>3</sup>Ajit S Oberoi, <sup>4</sup>Raju Sharma, <sup>5</sup>Rakesh Kumar, <sup>6</sup>Lokesh Kashyap, <sup>7</sup>Nikhil Tandon

<sup>1-7</sup>All India Institute of Medical Sciences, New Delhi, India

## INTRODUCTION

Mediastinal ectopic parathyroid adenomas (MEPAs) constitute 1 to 2% of all parathyroid adenomas. We report our experience with three patients of *intrathymic MEPA* treated successfully by video-assisted thoracoscopic approach (VATS).

## MATERIALS AND METHODS

Retrospective review of patients with MEPA undergoing VATS between January 2014 and October 2017 was done. The clinical details [history, examination, serum calcium (Ca), alkaline phosphatase (ALP), parathormone (PTH), vitamin D, ultrasonography

(USG) abdomen and neck, sestamibi & contrast-enhanced computed tomography (CECT) scan], operative technique, perioperative morbidity/mortality, and biochemical resolution of hyperparathyroidism/hypercalcemia were assessed. The results are expressed as absolute values or mean/median.

## RESULTS

Three cases of MEPA underwent VATS during the study period. Mean age was 19.3 years, with two of them being females. All were symptomatic. One patient had acute pancreatitis, two had pathological fractures, and one had kyphoscoliosis, pectus excavatum, poor lung reserves. One patient had previous cervical exploration. All had elevated serum calcium (median 11.3 mg%) and PTH (median 900 ng/mL). Ultrasonography neck was normal in all. Parathyroid scintigraphy showed increased tracer uptake in the anterior mediastinum. The CECT thorax showed retrosternal enhancing mass in the thymus. The VATS thymectomy (partial in one) with excision of parathyroid adenoma was performed. Single lung ventilation and intrapleural pressure of 8 mm Hg using low-flow CO<sub>2</sub> were used. Median operative time was 1.5 hours. On palpation, all had nodule (median size 1.5 cm). Post operatively, all had uneventful recovery, serum calcium, and PTH normalized. Histopathology revealed intrathyroidic parathyroid adenoma in all.

## CONCLUSION

Intrathyroidic MEPAs can be safely treated using VATS with minimal morbidity.

---

## The Incidence and Predictors of Thyroid Malignancy in the Background of Toxic Multinodular Goiter: The Study from an Endocrine Surgery Center in East Coast Malaysia

<sup>1</sup>AI Junaidi, <sup>2</sup>AK Norhashimah, <sup>3</sup>Imisairi Ab Hadi

<sup>1-3</sup>Department of Surgery, Raja Perempuan Zainab II, Kota Bharu, Kelantan, Malaysia

## INTRODUCTION

East coast Malaysia is known for an endemic goiter disease. The incidence of nodular goiter was around 80%; however, up to 1/5 were toxic multinodular goiter (MNG). The incidence of thyroid malignancy in toxic MNG was believed to be lower but few recent studies suggested that the incidence was increasing in trend.

## MATERIALS AND METHODS

A retrospective review on hospital electronic medical records was conducted. Patients who underwent surgery for toxic MNG from January 2007 to August 2017 were included; however, recurrent diseases and completion surgery were excluded from the study. The univariate and multivariate analyses were performed to identify predictors of malignancy.

## RESULTS

Total of 588 patients underwent thyroid surgery for MNG and 166 patients underwent for toxic MNG. Incidence of malignancy in toxic MNG was 13.8% compared with nontoxic MNG around 17.7%. The most common malignancy among toxic MNG patients were papillary thyroid carcinoma (91.3%), followed by follicular carcinoma and poorly differentiated carcinoma. The incidence was higher in female, which accounts for 91.32% and mean duration for goiter was 7.1 years. Mean age who had cancer was 46.26 years and mean size of thyroid gland was 90 mm with thyroid gland weight was around 167.7 gm.

No significant predictors of malignancy were found on statistical analysis.

## CONCLUSION

The incidence of cancer in toxic MNG (13.8%) was slightly lower compared with nontoxic goiter. No obvious predictor factors of thyroid malignancy in toxic MNG were identified. With this rate of incidental cancer, a total thyroidectomy should be the preferred surgical approach for patients with toxic MNG.

---

## Transoral Endoscopic Thyroidectomy—Vestibular Approach: First Cases of a University Hospital in Turkey

<sup>1</sup>Özer Makay, <sup>2</sup>Murat Özdemir, <sup>3</sup>Gökhan İçöz

<sup>1-3</sup>Ege University Hospital, Bornova, Izmir, Turkey

## INTRODUCTION

Transoral endoscopic thyroidectomy-vestibular approach (TOETVA), a method of endoscopic thyroidectomy using natural orifice, is a thyroidectomy technique that can be safely applied. This study aimed to present the first results of TOETVA applied in our clinic.

## MATERIALS AND METHODS

Data of seven patients who underwent lobectomy/total thyroidectomy with the TOETVA method were recorded. The patients underwent nasotracheal intubation and intermittent intraoperative nerve monitoring (IONM) was performed during thyroidectomy. After the surgery, cases were allowed to eat and drink the same day. In addition to the demographic data, types of surgery, total operation time, duration of flap dissection, amount of bleeding, reason of transition for open surgery, IONM data, complications, hospital stay, and pathology results were examined.

## RESULTS

All of the cases were female. The mean age was 39 (25–48) years. Three patients (42%) underwent lobectomy while four patients (58%) underwent total thyroidectomy. The mean operation time was 162 (115–195) minutes. The operation was completed by this endoscopic technique in six patients. One patient underwent conventional surgery for the contralateral lobe due to advanced fibrosis and technical difficulties. During IONM, no loss of signal was detected in any patient. None of the patients had any early or late hypoparathyroidism. There was no infectious complication. All of the patients were discharged on the first postoperative day. When pathology results of the patients were evaluated, thyroid papillary carcinoma was detected in all patients.

## CONCLUSION

Transoral endoscopic thyroidectomy-vestibular approach is a safe thyroidectomy technique with a long learning curve and excellent cosmetic results.

## Clinical Analysis of Risk Factors attributed to Lateral Lymph Node Metastases of Papillary Thyroid Microcarcinoma

<sup>1</sup>Qiang Zhang, <sup>2</sup>Qiyu Lu, <sup>3</sup>Xianying Meng, <sup>4</sup>Quan-Yang Duh, <sup>5</sup>Guang Chen

<sup>1</sup>Department of Thyroid Surgery, The First Hospital of Jilin University, Changchun, Jilin, People's Republic of China; Department of Surgery, University of California, San Francisco, California, USA

<sup>2,3,5</sup>Department of Thyroid Surgery, The First Hospital of Jilin University, Changchun, Jilin, People's Republic of China

<sup>4</sup>Department of Surgery, University of California, San Francisco, California, USA

## INTRODUCTION

Although most papillary thyroid microcarcinoma (mPTC) carries an excellent prognosis, it still has some severe aggressive biological behavior, such as lateral lymph metastases (LLNM) in a few patients. We aim to find the risk factors of LLNM in mPTC patients, further to help finding a proper surgical strategy for these patients.

## MATERIALS AND METHODS

Clinicopathological and genetic characteristics of 102 mPTC patients with LLNM were retrospectively analyzed, controlled with 1,129 mPTC patients without LLNM, all the data were from the patients of the First Hospital of Jilin University between May 2014 and May 2016.

## RESULTS

There existed a significant difference in gender, age, tumor size, multifocality, bilaterality, capsular invasion, extrathyroidal infiltration, lymphovascular invasion, central lymph node metastases (CLNM) between the two groups by univariate analysis, while BRAF mutation, preoperative thyroid-stimulating hormone, antithyroglobulin level, and Hashimoto diseases showed no statistic differences between the two groups. Multivariate logistic regression indicated male gender [odds ratio (OR) = 2.588], tumor size > 0.5 cm (OR = 2.586), multifocality (OR = 2.384), extrathyroidal infiltration (OR = 2.533), lymphovascular invasion (OR = 17.925), and CLNM number > 3 (OR = 8.123) were the independent risk factors of LLNM of mPTC patients.

## CONCLUSION

Papillary thyroid microcarcinoma patients with male gender, tumor size > 0.5 cm, multifocality, extrathyroidal infiltration, lymphovascular invasion, and CLNM number > 3 should be considered to have a high risk of LLNM. The BRAF mutation is not a predictor for LLNM in mPTC patients.

# Trends in Radioactive Iodine Usage in the Treatment of Differentiated Thyroid Cancer: An Analysis of Practice and Adherence to ATA Guidelines

<sup>1</sup>Y Sia, <sup>2</sup>R Dave, <sup>3</sup>D Nour, <sup>4</sup>AR Skandarajah, <sup>5</sup>JA Miller, <sup>6</sup>R Tasevski

<sup>1-6</sup>The Royal Melbourne Hospital, Parkville, Victoria, Australia

## INTRODUCTION

The 2009 American Thyroid Association (ATA) three-tiered risk stratification system provided a useful guide in determining, which differentiated thyroid cancer (DTC) patients should be considered for post-thyroidectomy radioactive iodine (RAI) ablation. We examined the use of RAI ablation at our institution in accordance with these guidelines.

## MATERIALS AND METHODS

Patients diagnosed with DTC within two 5-year periods (group I: 2002–2006 and group II: 2010–2014) were identified and risk stratified according to 2009 ATA guidelines. Radioactive iodine use and extent of surgery were compared between the two groups. Categorical variables were analyzed using Fisher's exact (2×2) and Chi-square (>2×2) tests.

## RESULTS

A total of 302 patients were included (group I = 88, group II = 214), with no significant difference in the risk groups. In group I, 54.5% of patients had total thyroidectomy compared with 64.5% in group II ( $p = 0.074$ ). Although this did not reach statistical significance, the number of both central lymph node dissection (9.1 vs 42.1%) and lateral lymph node dissection (7.0 vs 16.5%) carried out was significantly higher in group II compared with group I ( $p < 0.05$ ). Overall, fewer patients received RAI in group II compared with group I (53.3 vs 67%,  $p < 0.001$ ), most evident in the low-risk patients (27.2 vs 59.3%,  $p < 0.001$ ). In the high-risk group, the majority received RAI, with no difference between the groups.

## CONCLUSION

Since publication of the 2009 ATA guidelines, we performed more lymph node surgery and administered less RAI to our DTC patients.

# Is Fine-needle Aspiration Biopsy a Helpful Tool in Decision Making for Thyroidectomy when Dealing with $\geq 4$ cm Nodules?

<sup>1</sup>Azhar Osman, <sup>2</sup>Hussain B Mohamad, <sup>3</sup>Hatem Alwagih

<sup>1-3</sup>Hospital Sultanah Nur Zahirah, Terengganu, Malaysia

## INTRODUCTION

Debates exist regarding the usefulness of fine-needle aspiration (FNA) biopsy to rule out malignancy when surgeons face large thyroid nodules. The objective of this study was to challenge FNA utility in guiding surgical decisions when dealing with  $>4$  cm thyroid nodules.

## MATERIALS AND METHODS

All FNABs performed at Sultana Nur Zahirah Hospital between January 1, 2015 and September 30, 2017 followed by total or less than total thyroidectomy on nodules of at least 4 cm were identified. Demographic data, medical history, nodule biopsy characteristics, and surgical procedures were obtained. Fine-needle aspiration was blotted against the final histological evaluation of the operative specimens.

## RESULTS

A total of 127 patients with large thyroid nodules were retrieved. Females outnumbered males, and the mean age was approximately 45 years. The FNABs reported as malignant was 17 cases (13%), benign 66 cases (52%), inconclusive 24 cases (19%), and nondiagnostic 20 cases (16%). Postoperatively, malignancy was histopathologically diagnosed in 33/127 (26%) nodules. Sensitivity/specificity for detecting malignancy by FNA was 37 and 100% respectively. The negative predictive value (NPV) was 76%.

## CONCLUSION

As FNAB sensitivity in large nodules was 37%, NPV was high, we cannot challenge other similar studies as FNAB could be a good test to rule out malignancy in nodules  $\geq 4$  cm. This information could be quiet helpful and can help endocrine surgeons in taking the decision of whether to send patients with large nodule size straight ahead to the operating theatre, especially in high-risk patients.

## Sutureless Thyroidectomy with Electrosurgical Devices: A Tertiary Care Center Experience

<sup>1</sup>Anukriti Sood, <sup>2</sup>Karan Pao, <sup>3</sup>Kavindra Singh, <sup>4</sup>Talluri SHV Surya, <sup>5</sup>Piyush Ranjan, <sup>6</sup>Kamal Kataria, <sup>7</sup>Chitresh Kumar

<sup>1-7</sup>All India Institute of Medical Sciences, New Delhi, India and Medical Centre, Jaipur, Rajasthan, India

### INTRODUCTION

Sutureless thyroidectomy is one of the recent developments in endocrine surgery and is made possible by the use of electro-surgical devices as bipolar coagulation device (LigaSure™) and surgical diathermy bipolar forceps. Conventional suture tying requires a large number of surgical ties and is time-consuming, decreases healing, and increases foreign body reaction and wound infection.

### MATERIALS AND METHODS

We have conducted a retrospective study to analyze risks and benefits of futureless thyroidectomy in terms of operative time, safety, overall drainage volume, complications, and hospital stay. Between 2014 and 2017, 325 patients underwent futureless thyroidectomy (115 total thyroidectomy, 200 hemithyroidectomy, 10 Hartley Dunhill).

### RESULTS

Sutureless thyroidectomy was associated with less operative time and hospital stay and also found to have low drainage volume, low complications, and better outcome.

### CONCLUSION

LigaSure™ and bipolar forceps are safe, effective, and time saving alternative in a high output center like AIIMS, New Delhi compared with conventional suture ligation in achieving adequate homeostasis.

## Approach to Nonlocalizing Parathyroid Adenomas with Preoperative Ultrasonography and Scintigraphy

<sup>1</sup>Murat Özdemir, <sup>2</sup>Volkan Sayur, <sup>3</sup>Safa Vatanserver, <sup>4</sup>Ozer Makay, <sup>5</sup>Gokhan İçöz, <sup>6</sup>Mahir Akyıldız

<sup>1-6</sup>Ege University Hospital, Bornova, İzmir, Turkey

### INTRODUCTION

In this study, we aimed to identify the success of surgery performed in primer hyperparathyroidism (pHPT) patients with negative preoperative imaging methods.

### MATERIALS AND METHODS

Patients undergoing surgery because of pHPT between January 2011 and December 2016 were analyzed retrospectively. Demographic data, preoperative clinical, biochemical, radiological and scintigraphical data, type of surgery, postoperative pathological examination, additional medications required, and clinical follow-up data of patients with nonlocalizing adenoma were evaluated. We went for intraoperative parathyroid hormone (IOPTH) examination in all patients.

### RESULTS

A total of 242 patients (86% female and 14% men) underwent surgery. In 195 patients (80%) ultrasound and scintigraphy localization were identical, while in 40 (16%) ultrasound and sestamibi were incompatible with each other. In seven patients (4%) the adenoma could be localized with neither ultrasound nor sestamibi. The adenomas were located in the upper pole in two patients, lower pole in two patients, intrathyroidic in one patient, intrathyroidal in one patient and retroesophageal in one patient. The IOPTH values decreased to the normal range in all patients. There was no persistence or recurrence during follow-up of patients.

### CONCLUSION

The success of localization studies of a parathyroid adenoma is 90%. With the combined use of ultrasound and sestamibi, need for bilateral neck exploration has decreased and targeted minimally invasive parathyroid surgery has emerged. Bilateral neck exploration with a good knowledge of embryology and anatomy is highly successful in patients with negative preoperative imaging.

# Study of Relationship between the Size of Parathyroid Gland with iPTH, Serum Alkaline Phosphatase, and Duration of Dialysis in Secondary Hyperparathyroid Patient

<sup>1</sup>K Norhashimah, <sup>2</sup>AH Imisairi, <sup>3</sup>CA Mukarramah

<sup>1,2</sup>Breast and Endocrine Unit, Hospital Raja Perempuan Zainab II, Kota Bharu, Malaysia

<sup>3</sup>Department of Pathology, Hospital Raja Perempuan Zainab II, Kota Bharu, Malaysia

## INTRODUCTION

Secondary hyperparathyroidism is a common complication among patients with end-stage renal failure. The measurement of parathyroid hormone (PTH) level is the most important indicator in assessing changes in parathyroid gland activity. In patients with end stage renal failure, persistent hyperparathyroidism often leads to parathyroid hyperplasia.

## MATERIALS AND METHODS

From 2009 to 2016, a total of 88 patients undergoing total parathyroidectomy. However, only 65 were included in the study as histopathological examination identified all four glands. The serum level of intact parathyroid hormone (iPTH), alkaline phosphatase, and total calcium was measured before operation. Intraoperatively, the length and width of the gland were measured.

## RESULTS

We are looking at the correlation between the level of iPTH, total calcium, alkaline phosphatase, and duration of dialysis in predicting the size of parathyroid gland.

## DISCUSSION

We believe that the bigger the size of parathyroid gland, easier it will be for the surgeon to locate the parathyroid gland in the center without the availability of iPTH.

---

# An 8-year Review of Papillary Thyroid Cancer in Pediatric Age Group in a Noniodine Deficiency and Nonradiation Area: The Study from a Single Endocrine Surgery Center in East Coast Malaysia

<sup>1</sup>K Norhashimah, <sup>2</sup>AH Imisairi, <sup>3</sup>CA Mukarramah

<sup>1,2</sup>Breast and Endocrine Unit, Hospital Raja Perempuan Zainab II, Kota Bharu, Malaysia

<sup>3</sup>Department of Pathology, Hospital Raja Perempuan Zainab II, Kota Bharu, Malaysia

## INTRODUCTION

Thyroid cancer is a rare pathology in children and adolescent. It is responsible for 1.5 to 3% of all carcinomas in this age group.

## MATERIALS AND METHODS

Retrospective review of 32 patients who are 18 years and below at the time of diagnosis and who underwent thyroid surgery from 2009 till 2016. All of them were diagnosed papillary thyroid cancer on histopathological examination. Thyroid surgery pro forma and their old notes were reviewed for data collection. Disease-free survival was assessed using Kaplan–Meier method. Parametric analysis was performed using Chi-square test and t-test.

## RESULT

We will report the significant of age, size of tumor upon presentation, the presence of cervical nodes, and metastasis with the prognosis.

## DISCUSSION

We will discuss the prognosis and recommendation for managing papillary thyroid cancer in pediatrics age group.

## Reliability of Laryngeal Ultrasound by Endocrine Surgeon for Preoperative Vocal Cord Assessment

<sup>1</sup>Sadhana Mahamad, <sup>2</sup>S Balwinder, <sup>3</sup>B Sasikumar, <sup>4</sup>L Aynasha

<sup>1,4</sup>Breast and Endocrine Unit, Surgical Department, Hospital Putrajaya, Putrajaya, Malaysia

<sup>2,3</sup>Department of Otorhinolaryngology, Hospital Putrajaya, Putrajaya, Malaysia

### INTRODUCTION

Vocal cord assessment (VCA) prior to surgery is essential. Vocal cord palsy (VCP) is a strong predictor of malignancy and should increase surgical vigilance; hence, detection is important to clinical outcome to lessen the chance of creating a bilateral palsy. Routine direct laryngoscopic (DL) examination is the gold standard for visualizing vocal cord (VC) movement prior to the thyroid or parathyroid surgery. However, it is invasive, causes discomfort to patient, and costly. It is usually performed by otolaryngologist. Laryngeal ultrasound (LUS) is noninvasive, inexpensive, and can be done in real time. The aim of this study was to compare the efficiency of VCA through LUS performed by endocrine surgeon compared with DL.

### MATERIALS AND METHODS

This a single center prospective study done from July to November 2017; all patients were subjected to independent assessment of LUS by an endocrine surgeon<sup>1</sup> and by otolaryngologist<sup>2</sup> using DL.

### RESULTS

A total of 40 patients were included in this study. Nine patients were male and 32 female patients. Ten patients have thyroid cancer, 6 patients had hyperparathyroidism, and 24 patients had benign goiter. Vocal cord palsy was found in 3 (7.5%) out of 40. The VCP were right VCP (n: 2) and left VCP (n: 1). All three patients had thyroid cancer. The rest of 37 (92.5%) patients have normal VC movement proved by LUS and DL. The concordance rate of the two procedures is 100% with k-value 1.00, p value < 0.001.

### CONCLUSION

Surgeon performed LUS appears to be as good as DL in assessing VC movement preoperatively.

## A Retrospective Study of Incidence of Thyroid Carcinoma in Patients with Thyroiditis in a Tertiary Teaching Hospital in Chennai

<sup>1</sup>Selladurai Periyasamy, <sup>2</sup>Dhalapathy Sadacharan, <sup>3</sup>Umadevi Suresh, <sup>4</sup>Muthukumar, <sup>5</sup>Ravikumar, <sup>6</sup>Thalavai Sundarram

<sup>1-6</sup>Stanley Medical College, Chennai, Tamil Nadu, India

### INTRODUCTION

Thyroiditis is an inflammatory disorder of the thyroid gland. Incidence of chronic autoimmune thyroiditis is associated with iodine intake and iodine status of the population. In iodine-deficient region, iodine supplementation increases thyroid lymphocytic infiltration and increases the thyroid antibodies.

### MATERIALS AND METHODS

The study is a retrospective study in Madras Medical College, Chennai, in the Endocrine Surgery Department. Of a total of 1,456 patients (1,203 females and 253 males) who were admitted in our ward, about 751 patients (669 females and 82 males) underwent thyroidectomy and were included in the study. Period of study: From September 2014 to July 2017.

### RESULTS

Out of 751 patients (669 females and 82 males) who underwent surgery 179 patients (168 females and 11 males) were diagnosed as thyroiditis in histopathological examination; 83 patients (79 females and 4 males) had Hashimoto's thyroiditis, 69 patients had (64 females and 5 males), and 20 patients (18 females and 2 males) had lymphocytic thyroiditis. Seven patients all females had thyroid carcinoma (six patients had papillary thyroid carcinoma and one patient had anaplastic carcinoma).

### CONCLUSION

In our study, the incidence of thyroiditis is 23.83% and the incidence of associated thyroid carcinoma 3.91%. Four patients with nodular colloid goiter with thyroiditis progressed to papillary thyroid carcinoma. Hence patient with thyroiditis who develops nodules should be evaluated thoroughly and follow-up should be done regularly.



## Posters Day 1, March 8, 2018

### Iodine Intake Limitation after Postoperative Ablation of Differentiated Thyroid Cancer in Countries with High Iodine Intake

<sup>1</sup>Takahito Ando, <sup>2</sup>Yukie Ito, <sup>3</sup>Mirai Ido, <sup>4</sup>Yukako Mouri, <sup>5</sup>Junko Kousaka, <sup>6</sup>Kimihito Fujii, <sup>7</sup>Shogo Nakano

<sup>1-7</sup>Aichi Medical University, Aichi, Japan

#### INTRODUCTION

In 2014, outpatient radioactive iodine therapy (<sup>131</sup>I 30 mCi) after total thyroidectomy became possible in Japan. Limiting dietary iodine intake is important for effective ablation. Beginning in April 2014, our hospital reduced the duration of limited iodine intake before ablation from 2 to 1 week. We investigated whether limiting iodine intake for 1 week was appropriate in Japan, whose population is known to have chronically high iodine intake levels. We measured urinary iodine levels before and after limiting iodine intake for ablation or diagnostic scintigraphy in 19 patients (22 measurements: 20 outpatient and 2 inpatient) between April 2014 and January 2016. Limiting iodine intake in the outpatient setting was accomplished with the assistance of a dietician. Thyrogen was used in all patients and ablation or diagnostic scintigraphy was accomplished with levothyroxine. The median urinary iodine levels before and after limiting iodine intake were 247 and 63.5 µg/g Cr, respectively. The distribution of urinary iodine levels after limiting iodine intake was as follows: <50 µg/g Cr, 5 measurements; 50 to 100 µg/g Cr, 12 measurements; 100 to 150 µg/g Cr, 2 measurements; 150 to 200 µg/g Cr, 3 measurements; >200 µg/g Cr, no measurements. Sohn et al previously reported that the success rate of ablation was significantly increased by urinary iodine levels <66.2 µg/g Cr but significantly decreased by levels >250 µg/g Cr. Park et al reported that levels <100 µg/g Cr were appropriate. In our study, 14 patients had urinary iodine levels <100 µg/g Cr and none had levels >200 µg/g Cr. In Korea, where iodine intake levels are as high as they are in Japan, reducing the duration of limited iodine intake from 2 to 1 week did not significantly affect the success rate of ablations. Similarly, our results showed that decreasing the period of iodine intake limitation to 1 week, under strict guidance by a dietician, led to an adequate and appropriate reduction of iodine intake.

### Information and Communication Technology-enabled Follow-up Care for Thyroid Cancer

<sup>1</sup>BN Mohanty, <sup>2</sup>Prasanta K Pradhan, <sup>3</sup>AK Mohanty, <sup>4</sup>CR Sarangi

<sup>1,3,4</sup>Department of Endocrine Surgery, Srirama Chandra Bhanja Medical College & Hospital, Cuttack, Odisha, India

<sup>2</sup>Department of Nuclear Medicine, Sanjay Gandhi Postgraduate Institute of Medical Sciences, Lucknow, Uttar Pradesh, India

#### INTRODUCTION

Out of all cancers afflicting human body, thyroid cancer is distinctly different in view of its survival results surpassing others. Use of information and communication technology (ICT) in oncology practice has changed the outlook of cancer care. The present communication refers to an experience of ICT-enabled remote care of thyroid cancer patients after they received surgical treatment in one tertiary care health institution and subsequent adjuvant therapy in another tertiary care academic health institution located 1500 km away from the former hospital. An attempt was made in this study to find out the patient acceptability and the economics of tele-follow-up services offered to thyroid cancer patients.

#### MATERIALS AND METHODS

A total of 526 patients of thyroid cancer underwent surgery in the endocrine surgery department of SCB Medical College Hospital, Cuttack, Odisha, India during the period from 2004 to 2016. After surgery 439 of them were referred to Sanjay Gandhi PG Institute of Medical Sciences, Lucknow for subsequent nuclear medicine therapy as optimal curative treatment for them consisted of a combination of both and the later treatment facility was not available in Odisha. On return from SGPGIMS, Lucknow, these patients were followed up at Cuttack, Odisha, with both treating physicians sitting at both ends: every 6 months till rendered disease-free. Even after being declared disease free with adequate treatment, they remained on annual tele-follow-up as these cancers need life-long surveillance. Thus, repeated visits to Lucknow were avoided.

#### RESULTS

Out of 439 patients only 19 patients were lost to follow-up due to some domestic problems. Rest 420 patients regularly came to the telemedicine center of Cuttack as scheduled. An attempt was made to calculate the money saved by offering remote follow-up services. It was found that 1,342 number of visits of 420 patients could be avoided during this period. Expense toward travel cost of a patient with one attendant to Lucknow was calculated to be 129.22 USD and amount saved from avoiding 1,342 visits was found to be  $1,342 \times 129.22 = 173,414.68$  USD. Additionally patients were relieved from travel-related physical exhaustion and mental agony that could have resulted because of separation from family. Loss of several man-hours could also be avoided.

## DISCUSSION

Live discussion of disease details between medical professionals over computer interface appeared well acceptable to patients. Previsit video conference between patient and remote physician enhanced patient confidence for the scheduled visit to the remote super-specialty hospital. The ICT-enabled remote follow-up is found to be a suitable alternative to face-face follow-up. Additionally it saves time, money, and mental agony.

## CONCLUSION

Over time, continuum of care for thyroid cancer using ICT support has proved to be useful. The reasons for success of the program may be the presence treating medical experts at both ends jointly taking care of the patient for the disease problem and both communicating in the same regional language as that of the patient. The patient satisfaction indeed has resulted from integration of technology with conventional care.

## Vagus Nerve Injury during Continuous Intraoperative Nerve Monitoring for Thyroid Surgery: Assessment of Severity

<sup>1</sup>M Rohaizak, <sup>2</sup>AR Nor Faezan, <sup>3</sup>O Suraya, <sup>4</sup>AS Shahrunniza

<sup>1,4</sup>Breast and Endocrine Surgery Unit, Universiti Kebangsaan Malaysia Medical Centre, Kuala Lumpur, Malaysia

<sup>2,3</sup>Department of Surgery, University Technology MARA, Kuala Lumpur, Malaysia

## INTRODUCTION

Recurrent laryngeal nerve (RLN) injury during thyroidectomy is still one of the most important complications during thyroidectomy. Besides visual identification, intraoperative nerve monitoring was introduced to reduce the already low incidence of RLN injury. Continuous intraoperative nerve monitoring (CIONM) needs a continuous stimulation of the vagus nerve and any impending injury to the RLN will be shown by a drop in amplitude of more than 50% or increased in latency for more than 10%. Application of the automated periodic stimulation (APS) probe has been reported to cause injury not only to the vagus nerve but also the parasympathetic effect on the cardiovascular system. We prospectively evaluate these risks in a cohort of patients undergoing thyroidectomy.

## PLACE

Breast and endocrine surgery unit with high-volume academic endocrine surgery practice.

## MATERIALS AND METHODS

A prospective noncontrolled, nonrandomized study on 20 patients undergoing thyroidectomy for different diagnosis. The CIONM was performed using a commercially available nerve monitoring system, following the standard guidelines. Stimulation of the vagus nerve was performed before dissecting the vagus nerve (V1), below the point of APS probe (V2), and above the point of APS probe (V3). Demographic data were collected and outcome variables are the amplitudes of vagus stimulation (V1-V3), laryngoscope findings pre- and postoperative, intraoperative blood pressure, and pulse rate.

## RESULTS

Twenty patients were recruited but two patients were excluded as the vagus stimulation did not reach the acceptable amplitude despite all the measures. There were 18 patients included with 11 total thyroidectomies and 7 lobectomies, giving rise to 29 nerves at risk. Laryngoscope performed pre- and postoperative did not show any evidence of RLN injury. In 13 (44.8%) nerves, there was a drop in the amplitude between 1.7 and 59.5% (mean = 15.9%) but there was no evidence of vocal cord paresis or cardiovascular instability.

## CONCLUSION

Dissection of the vagus nerve for the application of APS probe does incur physical injury but this is not severe enough to be reflected as vocal cord paresis or cardiovascular instability. Careful dissection and following the standard guidelines are important steps in using intra-operative nerve monitoring for thyroidectomy.

# Clinical Analysis of Risk Factors attributed to Lateral Lymph Node Metastases of Papillary Thyroid Microcarcinoma

<sup>1</sup>Qiang Zhang, <sup>2</sup>Qiyu Lu, <sup>3</sup>Xianying Meng, <sup>4</sup>Quan-Yang Duh, <sup>5</sup>Guang Chen

<sup>1</sup>Department of Thyroid Surgery, The First Hospital of Jilin University, Changchun, Jilin, People's Republic of China; Department of Surgery University of California, San Francisco, California, USA

<sup>2,3,5</sup>Department of Thyroid Surgery, The First Hospital of Jilin University, Changchun, Jilin, People's Republic of China

<sup>4</sup>Department of Surgery, University of California, San Francisco, California, USA

## INTRODUCTION

Although most papillary thyroid microcarcinoma (mPTC) carries an excellent prognosis, it still has some severe aggressive biological behavior such as lateral lymph metastases (LLNM) in a few patients. We aim to find the risk factors of LLNM in mPTC patients, further to help finding a proper surgical strategy for these patients.

## MATERIALS AND METHODS

Clinicopathological and genetic characteristics of 102 mPTC patients with LLNM were retrospectively analyzed, controlled with 1129 mPTC patients without LLNM, all the data were from the patients of the First Hospital of Jilin University between May 2014 and May 2016.

## RESULTS

There existed a significant difference in gender, age, tumor size, multifocality, bilaterality, capsular invasion, extrathyroidal infiltration, lymphovascular invasion, central lymph node metastases (CLNM) between the two groups by univariate analysis, while BRAF mutation, preoperative thyroid-stimulating hormone, antithyroglobulin level, and Hashimoto diseases showed no statistic differences between the two groups. Multivariate logistic regression indicated male gender [odds ratio (OR) = 2.588], tumor size > 0.5 cm (OR = 2.586), multifocality (OR = 2.384), extrathyroidal infiltration (OR = 2.533), lymphovascular invasion (OR = 17.925), and CLNM number > 3 (OR = 8.123) were the independent risk factors of LLNM of mPTC patients.

## CONCLUSION

Papillary thyroid microcarcinoma patients with male gender, tumor size > 0.5 cm, multifocality, extrathyroidal infiltration, lymphovascular invasion, and CLNM number > 3 should be considered to have a high risk of LLNM. The BRAF mutation is not a predictor for LLNM in mPTC patients.

# Predictors of Hypothyroidism following Hemithyroidectomy in an Asian Cohort with High Incidence of Thyroiditis

<sup>1</sup>Ng Peng, <sup>2</sup>Cheryl HW Zhi, <sup>3</sup>Nga M En, <sup>4</sup>Tan W Boon, <sup>5</sup>Ngiam K Yuan, <sup>6</sup>Rajeev Parameswaran

<sup>1-6</sup>Division of Endocrine Surgery, National University Hospital, Singapore

## INTRODUCTION

Studies have shown that higher pre-op thyroid-stimulating hormone (TSH) values and presence of thyroiditis as predictive risk factors for hypothyroidism. The aim of the study was to assess the incidence of hypothyroidism following hemithyroidectomy in an area of high incidence of thyroiditis.

## MATERIALS AND METHODS

Retrospective analysis of a prospectively maintained database of all patients who underwent hemithyroidectomy from January 2000 to December 2013 at a tertiary institution. Patients were divided into two groups by postoperative thyroid function outcomes, into hypothyroid (n = 123) and euthyroid groups (n = 799). Factors analyzed were age, gender, race, biochemical data (pre- and postoperative TSH levels at 3, 6, 12, 24, 36, 60, and 120 months), histological data including that of thyroiditis, and duration of follow-up. Multivariate analysis was performed to identify multiple risk factors for the development of hypothyroidism.

## RESULTS

The incidence of hypothyroidism in the cohort was 123 (15%) of 952 patients, with the presence of thyroiditis in 262 patients (27%). The mean age of the cohort was 49.66 ( $\pm$ 16.17) with a female:male ratio of 3:1. About 110 (89%) of patients were symptomatic and required thyroxine replacement at a dose of  $38.42 \pm 35.61$   $\mu$ g. There was no difference in preoperative TSH levels and the presence of thyroiditis in patients who were hypothyroid versus non-hypothyroid [TSH: 2.20 vs 2.21; p = not significant

(NS)] and (thyroiditis: 15 vs 18%;  $p = \text{NS}$ ). There was no relationship between age, gender, race, histology, and the subsequent risk of hypothyroidism. The mean follow-up was for 84 months and the mean time to develop hypothyroidism was  $18.2 \pm 10.9$  months (1–132 months).

## CONCLUSION

The incidence of hypothyroidism following thyroid lobectomy was 15%. Pre-op TSH and presence of thyroiditis did not confer any risk toward the development of hypothyroidism in our cohort. Therefore, routine evaluation of thyroid antibodies is not necessary in patients undergoing thyroid lobectomy.

## Screening Rates of Thyroid Sonography in Korea: Data from Korea National Health and Nutritional Examination Survey from 2013 to 2015

<sup>1</sup>Eui T Kim, <sup>2</sup>Jun W Min, <sup>3</sup>Myungchul Chang

<sup>1-3</sup>Dankook University Hospital, Cheonan-si, South Korea

### AIM

The rapid increase of thyroid cancer in Korea is explained by the increase of early screening by thyroid sonography. The aim of this study is to investigate the changing pattern of sonographic test for thyroid cancer screening and the relationship with thyroid cancer incidence using Korea National Health and Nutrition Examination Survey (KNHANES) data.

### MATERIALS AND METHODS

Data were collected from 2013 to 2015 of KNHANES VI. Among total 22,948 participants, 14,322 subjects aged over 30 with no history of thyroid disease were included. The experience, frequency, and recent test within 1 year of screening thyroid sonography were evaluated according to the age, sex, and screening years.

### RESULTS

A total of 4,007 (26.9%) subjects experienced screening thyroid sonography. The percentage of subjects with screening sonography in the past 1 year was 44.9% in 2013, 40.0% in 2014, and 41.1% in 2015.

### CONCLUSION

This study showed that the rates of screening thyroid sonography had declined tendency after year 2013 when overdiagnosis of thyroid cancer was debated.

## Clinical Analysis of 44 Patients with Primary Hyperparathyroidism in Our Department

<sup>1</sup>Takao Mlyaguni, <sup>2</sup>Daijiro Kagawa, <sup>3</sup>Ryoko Ono

<sup>1-3</sup>Naha City Hospital, Naha, Okinawa, Japan

### INTRODUCTION

We herein review the clinicopathological features of primary hyperparathyroidism (PHPT) patients diagnosed and treated in our hospital.

### MATERIALS AND METHODS

We examined 44 PHPTs diagnosed in our department between January 2010 and June 2015. In a retrospective review, we studied results of the blood examination including serum ionized calcium and intact parathyroid hormone (PTH), preoperative diagnosis of localization, operation method, histopathological diagnosis, and results of surgery.

### RESULTS

Among the 44 cases, there were 15 males and 29 females with the median age of 63.5 years. Surgery was performed in 35 patients. The nine patients were not received surgery because of impossibility of localization diagnosis, elderly years, and poor general condition. Ultrasonography, computed tomography (CT), and <sup>99m</sup>Tc-MIBI scintigraphy were basically performed in each patient.

Sensitivity of these modalities in localization diagnosis was 69.8% in ultrasonography, 81% in <sup>99m</sup>Tc-MIBI scintigraphy, and 80% in CT. In six cases (13.6%), we cannot point out lesions in any diagnostic modalities and they are currently under surveillance. Histological examination revealed 28 parathyroid adenomas and 7 hyperplasia. The serum calcium level was normalized in all cases after surgery, but the level of intact PTH did not normalize in five cases. Recurrent laryngeal nerve palsy was not observed in any of the patients.

## CONCLUSION

Ultrasonography, CT, and <sup>99m</sup>Tc-MIBI scintigraphy were useful modalities for accurately diagnosing the localization of the parathyroid gland tumors. Intraoperative quick PTH assay is expected to help surgeons confirm biochemically, especially in cases of multiple parathyroid adenoma.

---

## The Safety and Efficacy of Surgery for Primary Hyperparathyroidism without Intraoperative Parathyroid Hormone Measurement in Japan

<sup>1</sup>Hiroki Uchida, <sup>2</sup>Yatsuka Hibi, <sup>3</sup>Chikara Kagawa, <sup>4</sup>Yumi Tomiie, <sup>5</sup>Zenichi Morise

<sup>1-5</sup>Fujita Health University, Toyoake, Aichi, Japan

## INTRODUCTION

Primary hyperparathyroidism (PHP) is a curable disease because most patients have only one adenoma and can fully recover after adenoma removal at the location determined by preoperative imaging. However, many Japanese surgeons believe that intraoperative intact PTH measurement (IOPM) is essential to the surgery. Hence, many general surgeons in Japan are unable to perform surgeries for PHP in their local hospitals and must refer the patients to urban high volume centers that have introduced IOPM, even though they are experienced in general surgery. So, we analyzed the relationship of surgical outcomes, with and without IOPM.

## MATERIALS AND METHODS

Between January 2007 and December 2016, 183 consecutive patients with PHP underwent surgery in our institution. We performed the surgery between 2007 and 2012 without IOPM, and starting from 2013 we performed the surgery with IOPM. We compared and evaluated the cure rate and surgical complications between patients who underwent unilateral neck exploration without IOPM with clear preoperative localization of the affected adenoma, and those who underwent any surgery with IOPM.

## RESULTS

There was no significant difference in cure rate between the two groups and there were no surgical complications in either group.

## CONCLUSION

In cases where preoperative imaging is able to clearly localize the affected adenoma and an experienced general or endocrine surgeon performs the surgery, there is no significant difference in overall cure rate and surgical complications with or without IOPM. Our study may encourage many general surgeons to perform the surgery without IOPM.

---

## Adrenal Cortical Carcinoma with Tumor Thrombus Extension into Left Renal Vein, Inferior Vena Cava, and Distant Left Lung Metastasis

<sup>1</sup>Mayurran Panirselvam, <sup>2</sup>Suraya Othman, <sup>3</sup>Nor FA Rashid, <sup>4</sup>Shahrin NA Suhaimi, <sup>5</sup>Rohaizak Muhammad

<sup>1-5</sup>Department of Surgery, Universiti Kebangsaan Malaysia Medical Centre, Malaysia

## INTRODUCTION

Adrenal cortical carcinoma (ACC) is a rare and aggressive malignancy of the adrenal cortex. Management often requires a multidisciplinary approach. Complete surgical resection is potentially curative treatment for stages I to III disease; however, managing a metastatic ACC remains a challenge for most. We describe a case of ACC with locally extensive and distant metastasis in which we performed open left adrenalectomy, inferior vena cava thrombectomy, splenectomy, and left lung metastasectomy followed by adjuvant mitotane therapy.

## Does Stress affect Thyroid Function in Patients Who underwent Thyroidectomy?

<sup>1</sup>Inhwa Lee, <sup>2</sup>Hyeung K Kim, <sup>3</sup>Jeonghun Lee, <sup>4</sup>Euy Y Soh

<sup>1-4</sup>Department of Thyroid Endocrinology Surgery, Ajou University Medical Center, Ajou University School of Medicine, Suwon, South Korea

### INTRODUCTION

There are some patients with abnormal thyroid function due to stress during follow-up. However, it is controversial whether stress affects thyroid function. Therefore, we investigated whether stress affects thyroid function in patients who undergone thyroidectomy.

### MATERIALS AND METHODS

Twenty-eight patients who underwent thyroidectomy from July 2007 to January 2016 were enrolled. The male to female ratio was 3:25 and the mean age was 48 years (min 29, max 72) at operation. Five patients underwent lobectomy. The mean follow-up period was 49 months (min 8, max 93). Statistical analysis was performed using paired t-test, and PROC MIXED with SAS 9.4.

### RESULTS

Eight patients (28.5%) had subclinical hypothyroidism and 14 patients (50%) had hypothyroidism above thyroid-stimulating hormone (TSH) > 10  $\mu$ IU/mL. When the patients were under stress, free thyroxine (T4) decreased and TSH increased, even though each patient took the same dose of synthroid ( $p < 0.001$ ). When we performed PROC MIXED to investigate the effect of stress on TSH considering the effect of free T4 on TSH, TSH increased significantly in the patients under stress ( $p < 0.001$ ).

### CONCLUSION

Stress may cause the hypothyroidism in patients who underwent thyroidectomy. Therefore, appropriate treatment and counseling will be needed for the patients at outpatient's clinic.

## Lymph Node Ratio can be a Prognostic Factor of Papillary Thyroid Cancer Patients Who underwent Total Thyroidectomy and Central Lymph Node Dissection

<sup>1</sup>Jung H Yoon, <sup>2</sup>Shin J Kang, <sup>3</sup>Young J Ryu, <sup>4</sup>Min H Park, <sup>5</sup>Jin S Cho

<sup>1-5</sup>Chonnam National University Hwasun Hospital and Medical School, Gwangju, South Korea

### INTRODUCTION

Lymph node (LN) status has significant effect on recurrent in papillary thyroid cancer (PTC). The aim of this study is to analyze clinicopathological factors of PTC patients who underwent total thyroidectomy with more than six LN dissection in central compartment and evaluate factors relevant to disease-free survival.

### MATERIALS AND METHODS

We collected medical records of 406 patients who underwent total thyroidectomy with bilateral central LN dissection retrospectively between January 2003 and December 2007. Median follow-up was 107 months.

### RESULTS

Of 406 patients, 28 patients had recurrence during follow-up period (3 patients in N0, 25 patients in N1a). Optimal cut-off value of lymph node ratio (LNR) in N1a patients was 0.55. The patients with LNR > 0.55 tend to have male gender, large tumor size, and advance T stage. Of 198 N1a patients, male gender, LNR > 0.55, lymphovascular invasion, and advance T stage had worse disease-free survival in univariate analysis. In multivariate analysis, LNR > 0.55 was independent significant predictive factor (hazard ratio, 4.279; 95% confidence interval, 1.639–11.170;  $p = 0.003$ ).

### CONCLUSION

Lymph node ratio 0.55 is a significant predictive factor associated with recurrence in patients who underwent total thyroidectomy with at least resected six LNs in central compartment. Therefore, N1a PTC patients with LNR > 0.55 need careful monitoring during follow-up.

# Acute Suppurative Thyroiditis

<sup>1</sup>Neha Gupta, <sup>2</sup>Manish Kaushal

<sup>1,2</sup>Mahatma Gandhi Memorial Medical College, Indore, Madhya Pradesh, India

## INTRODUCTION

Acute suppurative thyroiditis is an uncommonly encountered condition, the differential diagnosis for a painful thyroiditis is limited, with subacute and chronic thyroiditis being the most often encountered processes. A review of the literature over the past 100 years has revealed only 224 cases, majority reported in children with predisposing factors such as pyriform fistulae or thyroglossal ducts. Preexisting thyroid diseases, including longstanding goiter and thyroid malignancies, are known predisposing factors. Acute suppurative thyroiditis with abscess formation, although rare, is a formidable clinical scenario with morbid complications included septicemia, osteomyelitis, and septic thrombophlebitis. Early biopsies and culture are needed for prompt antimicrobial therapy whereas surgical drainage is required for large abscess. We report a series of eleven cases with 10 euthyroid and one hypothyroid status on initial presentation with clinical features of acute suppurative thyroiditis in a period of 7 years.

## MATERIALS AND METHODS

We examined the medical records of all thyroiditis cases between January 1, 2012 and December 31, 2016 reported as thyroiditis where diagnosis of acute suppurative thyroiditis was made in eleven cases. All cases were managed surgically.

## RESULTS

Thyroid abscesses and acute suppurative thyroiditis are uncommon, representing only 0.1 to 0.7% of surgically treated thyroid pathologies. More commonly encountered in children than adults, they are associated with poorly indicative clinical symptoms, making the diagnosis difficult.

## CONCLUSION

It is a very rare disease, and one where the clinical symptoms and signs are frequently misleading. On the contrary, prompt diagnosis is crucial for successful treatment.

---

# Thyroid Isthmusectomy: Experience at a Tertiary Care Center

<sup>1</sup>Talluri SHV Surya, <sup>2</sup>Chitresh K Sharma, <sup>3</sup>Karan Pao, <sup>4</sup>Kavindra Singh

<sup>1-4</sup>All India Institute of Medical Sciences, New Delhi, India

## INTRODUCTION

Isthmusectomy of thyroid gland involves resection of isthmus with a cuff of tissue from both lobes, leaving the tracheoesophageal grooves unexposed. This prevents the risk of damage to the recurrent laryngeal nerves and parathyroid glands on both sides. The present standard of care for thyroid nodules confined to isthmus or pyramidal lobe is hemi-thyroidectomy, this procedure carries the risk of damage to recurrent laryngeal nerve, parathyroid glands of one side, and few patients may require calcium and thyroxine supplementation in postoperative period.

## AIMS AND OBJECTIVES

We aim to propose that thyroid isthmusectomy is a safe and adequate surgical procedure for thyroid nodules confined to isthmus.

## MATERIALS AND METHODS

In a retrospective analysis of hospital records in the Department of Surgical Disciplines, All India Institute of Medical Sciences, New Delhi, India, from Jan 2013 to Nov 2017, a total of 325 patients underwent thyroid surgery after detailed clinical, radiological, pathological workup. Of them, 45 patients presented with a solitary nodule in the thyroid isthmus with benign/indeterminate cytology on fine needle aspiration. Thirty-six of these patients underwent hemi-thyroidectomy and nine underwent isthmusectomy.

## RESULTS

None of these 45 patients had immediate postoperative complications, voice change. No recurrences were seen in follow-up records. About 10 out of 36 patients who underwent hemi-thyroidectomy required thyroxine supplementation in the postoperative period but no patients of isthmusectomy needed supplementation. No patients had voice change postoperatively.

## CONCLUSION

Isthmusectomy is a safe, efficacious, and adequate procedure for benign or indeterminate thyroid nodules limited to isthmus and pyramidal lobe, which allows treatment, pathological diagnosis, and long-term management of these lesions.

## Traumatic Pneumothroid

<sup>1</sup>Angelika F Na, <sup>2</sup>Timothy J Chittleborough, <sup>3</sup>Julie A Miller

<sup>1,2</sup>Department of General Surgery, The Royal Melbourne Hospital, Melbourne, Australia

<sup>3</sup>Department of General Surgery, The Royal Melbourne Hospital, Melbourne, Australia; Department of Surgery, University of Melbourne, Melbourne Australia

## INTRODUCTION

Given the multitude of organ systems traversing the neck, blunt or penetrating trauma can result in injuries to numerous vital structures. The thyroid gland is a well-vascularized organ situated anteriorly in the neck. Despite its vulnerable location, it rarely suffers traumatic injury.

## CASE REPORT

We report the case of a 37-year-old male with self-inflicted left neck and abdominal stab wounds. On presentation, there was no active bleeding, hematoma, dysphonia, or crepitus. Computed tomography revealed gas within the thyroid gland "pneumothroid," suggesting an airway injury. At neck exploration, the knife had traversed the left internal jugular vein and the left lobe of the thyroid, entering the tracheoesophageal groove, and the posterior wall of the trachea. The left recurrent laryngeal nerve and the left parathyroid glands were intact. A segmental resection of the upper pole was performed for hemostasis and exposure. A small posterior midline tracheal laceration was identified and repaired primarily. Trauma laparotomy revealed hemoperitoneum from transection of the right inferior epigastric artery, with no visceral injury identified.

## DISCUSSION

To our knowledge this is the first report in the English literature describing surgical management of traumatic pneumothroid with associated tracheal and internal jugular vein injury. Although isolated thyroid injury is rare, clinicians must be able to rapidly assess and treat direct airway injury or secondary compression from thyroid hematoma. The presence of pneumothroid in penetrating trauma should raise suspicion of tracheal injury and surgical exploration should be considered.

## Dynamic Risk Stratification correlates with Changes in Neutrophil-to-lymphocyte Ratio following Treatment of Differentiated Thyroid Cancer

<sup>1</sup>Shih-Ping Cheng, <sup>2</sup>Chien-Liang Liu, <sup>3</sup>Jie-Jen Lee, <sup>4</sup>Ming-Nan Chien, <sup>5</sup>Tsang-Pai Liu, <sup>6</sup>Po-Sheng Yang, <sup>7</sup>Chun-Chuan Lee

<sup>1-7</sup>MacKay Memorial Hospital, Taipei, Taiwan

## INTRODUCTION

The peripheral blood neutrophil-to-lymphocyte ratio (NLR) is an inflammatory marker that is associated with patient outcome in various types of malignancy. We and others have shown that baseline NLR is a prognostic indicator for identifying patients with high-risk thyroid cancer. In the present study, we hypothesize that posttreatment changes in NLR might have a predictive value for the clinical response to therapy.

## MATERIALS AND METHODS

This retrospective cohort study included patients who had available NLR data both preoperatively and during follow-up. Response to therapy was determined according to the dynamic risk stratification system proposed in the 2015 American Thyroid Association (ATA) guidelines.

## RESULTS

A total of 151 patients who had thyroidectomy for differentiated thyroid cancer and 87 patients who underwent thyroidectomy for benign thyroid lesions were included in the analysis. The preoperative and postoperative median NLR values of the benign group were 1.93 and 1.95, respectively. Among patients with differentiated thyroid cancer, the median NLR values decreased from 1.96 to 1.78 after surgery ( $p = 0.037$ ). In the subgroup analysis, significant changes were observed in tumor-node-metastasis (TNM) stage 1, ATA low risk of recurrence, and patients who had an excellent response. The difference in perioperative NLR values was correlated with the ATA initial risk of recurrence scheme ( $p = 0.017$ ) and response to therapy status ( $p < 0.001$ ) but not the TNM classification ( $p = 0.098$ ).



## CONCLUSION

Excellent response to therapy corresponds with a decrease in NLR irrespective of initial tumor stage or ATA risk of recurrence.

---

## Recurrent Papillary Thyroid Cancer with Nodular Fasciitis-like Stroma and CTNNB1 Mutations

<sup>1</sup>Liang Zhou, <sup>2</sup>Liu Hong Shi

<sup>1,2</sup>Sir Run Run Shaw Hospital, Zhejiang University, Hangzhou, Zhejiang, People's Republic of China

## INTRODUCTION

Papillary thyroid cancer with nodular fasciitis-like stroma has dual clinicopathological features and behaves more aggressive with CTNNB1 mutations. Herein we report a recurrent papillary thyroid cancer with nodular fasciitis-like stroma and CTNNB1 mutations, which has not been reported before and needs to adopt a novel therapeutic maneuver.

## MATERIALS AND METHODS

A 48-year-old female encountered a recurrent desmoid tumor 6 months after her initial operation for papillary thyroid cancer with nodular fasciitis-like stroma and was reoperated 2 years later. Both the primary and recurrent tumors exhibited extensive local invasion and harbored CTNNB1 mutations.

## RESULT

The patient now is free of disease for 6 months after the second operation without adjacent therapy.

## CONCLUSION

CTNNB1 mutations should be sought in the distinctive lesion. If it was present, the lesion should be renamed to reflect the aggressive nature. Therapeutically, a complete surgical resection should be performed, otherwise a radiotherapy should be taken into account.

---

## Learning Curve for Endoscopic Thyroidectomy using the Video-assisted Neck Surgery Method

<sup>1</sup>Ryuta Nagaoka, <sup>2</sup>Iwao Sugitani, <sup>3</sup>Marie Sanada, <sup>4</sup>Tomoo Jikuzono, <sup>5</sup>Ritsuko Okamura, <sup>6</sup>Takehito Igarashi, <sup>7</sup>Haruki Akasu  
<sup>8</sup>Kazuo Shimizu

<sup>1-8</sup>Nippon Medical School, Tokyo, Japan

## INTRODUCTION

Video-assisted neck surgery (VANS) has been reported for resection of the thyroid and parathyroid glands. This method offers cosmetic benefits for patients, so it is expected to become popular. However, how many operations are required for beginners to gain proficiency with VANS techniques remains unclear.

## MATERIALS AND METHODS

A surgeon started using VANS for thyroid resection in May 2016, treating 20 cases by September 2017. He used a subclavian approach and a gasless (skin-raising) technique. When the first operation was performed, the surgeon was 31 years old and had worked as a surgeon for 4 years.

## RESULTS

Hemithyroidectomy was performed in all 20 cases. In cases of malignancy, central neck dissection was added. Postoperative diagnoses were benign thyroid tumor (n = 7), papillary thyroid carcinoma (n = 12), and follicular thyroid carcinoma (n = 1). Mean operating time was 126.9 min (85–174 min), reaching a plateau after ten cases. Postoperative recurrent laryngeal nerve paralysis was observed in five cases (one permanent and four transient). Comparing the first 10 cases with the last 10 cases, mean operating time reduced (from 137.7 to 111.7 min, p = 0.008), but mean blood loss (from 14.0 to 19.3 mL, p = 0.56) and frequency of postoperative recurrent laryngeal nerve paralysis (from 20 to 30%, p = 0.63) were unchanged.

## CONCLUSION

At least 10 operations appear necessary for VANS beginners to acquire proficiency in the VANS technique. More experience is then needed to improve safety and accuracy.

---

## Endoscopic Surgery Indication for Benign Thyroid Tumor

<sup>1</sup>Manabu Iwate, <sup>2</sup>Satoshi Suzuki, <sup>3</sup>Hiroshi Mizunuma, <sup>4</sup>Izumi Nakamura, <sup>5</sup>Toshihiko Fukushima, <sup>6</sup>Keiichi Nakano  
<sup>7</sup>Yoshiko Matsumoto, <sup>8</sup>Shinichi Suzuki

<sup>1-8</sup>Department of Thyroid and Endocrinology, Fukushima Medical University, Fukushima, Japan

## INTRODUCTION

The incidence of thyroid tumor in young people is increasing, and a cosmetic approach plays an important role in thyroid operation. We adopted the axillar-areolar approach to endoscopic thyroid surgery (AAA-ETS) for benign thyroid tumors in 1999 and have been using this approach since. We showed the clinicopathological data for endoscopic surgery indication for benign tumor.

## RESULTS

A total of 42 thyroid disease patients underwent AAA-ETS at Fukushima Medical University between January 2007 and December 2016. The inclusion criteria for AAA-ETS were a benign tumor <4 cm in diameter. The mean age was 32.6±10.4 years (16–57 years), and the mean tumor size was 32.9 ± 9.6 mm (10.7–55 mm). The final pathological diagnoses of the tumors were follicular adenoma (n = 25), adenomatous goiter (n=13), papillary carcinoma (follicular variant) (n = 2), and Basedow's disease (n = 2). The papillary carcinoma cases had been diagnosed as benign tumors prior to AAA-ETS. Transient vocal cord paresis occurred in 0 (0%) patients after AAA-ETS. Intraoperative nerve monitoring for reducing the incidence of recurrent laryngeal nerve injury was performed in 15 patients.

## CONCLUSION

AAA-ETS is a safe treatment for thyroid benign tumors for thyroid.

---

## Papillary Carcinoma within a Thyroglossal Cyst: Preoperative Diagnosis using Ultrasound and Management Options

<sup>1</sup>RM Singaporewalla, <sup>2</sup>Adele Ng, <sup>3</sup>Tan Man Hon

<sup>1-3</sup>Department of Surgery, Khoo Teck Puat Hospital, Singapore

## INTRODUCTION

Papillary carcinoma within a thyroglossal cyst is very rare (1%) and most cases are detected at postoperative histology. We present a case of thyroglossal cyst where a suspicious lesion was detected preoperatively on ultrasound and targeted cytology conducted. The management options are also discussed.

## CASE REPORT

A 60-year-old male presented with a painless midline neck lump for 6 months. Examination confirmed a 3 × 4 cm thyroglossal duct cyst. His mother had a history of thyroid cancer. Clinician performed ultrasound of the thyroid gland was unremarkable and evaluation of the cyst revealed an irregular solid 8 mm focus attached to the roof with speckled calcification within. This TIRADS 4B (Thyroid Imaging Reporting and Data System) was reported as suspicious of papillary thyroid cancer (Bethesda V) on guided cytology. Staging ultrasound of the rest of the neck did not reveal any suspicious neck nodes.

## RESULTS

The patient was counseled for Sistrunk Procedure and possible central neck node clearance. Frozen section of prelaryngeal lymph nodes was negative for malignancy. An uneventful removal of the cyst and central hyoid bone was performed taking care not to rupture the cyst wall. Final histology confirmed a 8 mm papillary thyroid microcarcinoma confined to the cyst wall. He is on yearly follow-up.

## CONCLUSION

Although thyroglossal duct cysts are easily diagnosed clinically, a preoperative evaluation of the cyst and the entire thyroid gland is mandatory to detect suspicious solid lesions within the cyst or the gland that may affect the final surgical management.

---

## Bilateral Axillary and Breast Approach Thyroidectomy: First Cases of a University Hospital in Turkey

<sup>1</sup>Murat Özdemir, <sup>2</sup>Ozer Makay, <sup>3</sup>Gökhan İçöz, <sup>4</sup>Mahir Akyıldız

<sup>1-4</sup>Ege University Hospital, Bornova, Izmir, Turkey

## INTRODUCTION

Bilateral axillary and breast approach (BABA) thyroidectomy, performed by placing trocars in both axilla and areola, is a remote access thyroidectomy technique that can be safely applied. This study aimed to present the first results of BABA thyroidectomy applied in Turkey.

## MATERIALS AND METHODS

Data of eight patients who underwent lobectomy/total thyroidectomy with the BABA thyroidectomy method were recorded. Intraoperative nerve monitoring (IONM) was performed during thyroidectomy. In addition to the demographic data, types of surgery, total operation time, duration of flap dissection, amount of bleeding, reason of transition for open surgery, IONM data, complications, hospital stay, and pathology results were examined.

## RESULTS

Seven patients were female and 1 patient was male. The mean age was 43 (32–60) years. Three patients (37%) underwent lobectomy, while five patients (63%) underwent total thyroidectomy. The mean operation time was 216 minutes (150–240). The operation was completed endoscopically in seven patients. The male patient underwent conversion to conventional surgery due to anatomic difficulties. During IONM, no loss of signal was detected in any patient. None of the patients had an early or late hypoparathyroidism. All of the patients were discharged on the first postoperative day. When pathology results of the patients were evaluated, thyroid papillary carcinoma was detected in six patients, nodular disease in two patients.

## CONCLUSION

Bilateral axillary and breast approach is a safe and remote access thyroidectomy technique with a long learning curve and excellent cosmetic results.

---

## Tumor in Disguise: A Case Report from an Endocrine Surgery Center in East Coast Malaysia

<sup>1</sup>K Norhashimah, <sup>2</sup>WH HanifAzizi, <sup>3</sup>M Khairul Mustaqim, <sup>4</sup>AH Imisairi, <sup>5</sup>AA Nor Aizan

<sup>1-4</sup>Breast and Endocrine Surgical Unit, Hospital Raja Perempuan Zainab II, Kota Bharu, Malaysia

<sup>5</sup>Department of Pathology, Hospital Raja Perempuan Zainab II, Kota Bharu, Malaysia

## INTRODUCTION

Trachea tumors are rare entities, in which the incidence of primary trachea tumors is less than 0.2 per 100,000 persons per year. Adenoid cystic carcinoma (ACC) accounts for approximately two-thirds of primary neoplasm of the airway. Adenoid cystic carcinoma usually presents with cough, hemoptysis, and dyspnea, sometimes mistaken as asthma. There are only few case reports regarding trachea adenoid cystic carcinoma with thyroid invasion.

## CASE REPORT

A 56-year-old lady presenting with progressive painless neck swelling for 3 years associated with symptoms of hyperthyroidism. Clinically the patient has a 5 × 4 cm right-sided neck swelling and biochemically she was in hyperthyroid state. Initial fine needle aspiration cytology reveals follicular neoplasm (Thy IV). Preoperative indirect laryngoscopy was normal and computed tomography (CT) imaging of the neck shows ill-defined enhancing lesion at paratracheal region with possible exophytic lesion arising from the isthmus or right thyroid lobe with extension into right paratracheal region. There were multiple small nodules with calcification within the visualized right and left thyroid lobes. Instead of total thyroidectomy, debulking thyroid surgery

was done and the tumor was shaved from the trachea with intention for radioiodine ablation later. The histopathology examination reveals metastatic adenoid cystic carcinoma and repeated CT scan of neck, thorax, and abdomen correlated with histopathological findings showed that the primary tumor was from trachea. She was then referred to oncologist for radiotherapy.

## DISCUSSION

We discuss about the difficulty in managing this rare disease.

## Chyle Leak after a Simple Hemithyroidectomy: An Extremely Rare Situation

<sup>1</sup>Adi S Muhammed, <sup>2</sup>Shahrin N Suhaimi, <sup>3</sup>Suraya Othman, <sup>4</sup>Nor FA Rashid, <sup>5</sup>Rohaizak Muhammad

<sup>1,2,5</sup>Department of Surgery, UKM Medical Centre, Hospital Canselor Tuanku Muhriz, Malaysia

<sup>3,4</sup>Department of Surgery, Universiti Teknologi MARA, Malaysia

## INTRODUCTION

Chyle leak is a well-known complication that can occur after a thyroidectomy with neck dissection; however, it rarely occurs after thyroidectomy alone. Here, we report a case and the management of a chyle leak following a left hemithyroidectomy for a benign solitary thyroid nodule. The patient was treated both conservatively and successfully. Based on the literature search, this is only the second reported case of a chyle leak after a simple hemithyroidectomy without any central or lateral neck dissection.

## A Spontaneously Ruptured Pheochromocytoma mistaken for Acute Myocardial Infarction

<sup>1</sup>Osman Toktas, <sup>2</sup>Abdussamet Batur, <sup>3</sup>Recep Eryilmaz, <sup>4</sup>Abduselam Özdemir, <sup>5</sup>Tolga Kalaycı

<sup>1-5</sup>Medical Faculty of Yuzuncuyıl University, Van, Turkey

## INTRODUCTION

Ruptured pheochromocytoma is an unusual condition, with mortality rate reaching 31 to 50%. Its varied presentations frequently delay the diagnosis, and occasionally, there are catastrophic outcomes. We describe a case of ruptured pheochromocytoma that was initially mistaken for acute myocardial infarction. On abdominal computed tomography, a hemorrhagic mass lesion surrounding the kidney in the region of the right adrenal gland was observed, but its origin could not clearly be distinguished. On laparotomy, a ruptured and hemorrhagic adrenal mass with common necrotic areas was seen, and this was excised successfully. After surgery, the patient experienced a sudden drop in blood pressure. In the postoperative period in the intensive care unit, cardiac arrest occurred third time, which was the effect of too much preoperative blood loss. Despite all interventions, the patient could not be saved. The histological evaluation of the mass showed that it was pheochromocytoma. Surgery combined with early diagnosis and appropriate preoperative treatment may be life saving, but it is not easy to consider this rare cause in a hemorrhagic emergency case, such as this one. We think that this phenomenon is reminiscent of the adage that an "acute abdomen is filled with surprises."

## Postoperative Outcomes and Prognosis of Papillary Thyroid Carcinoma Patients with Invasion into the Recurrent Laryngeal Nerve or Trachea preserved by Shaving Procedure

<sup>1</sup>Chikara Kagawa, <sup>2</sup>Yumi Sakai, <sup>3</sup>Hiroki Uchida, <sup>4</sup>Yatsuka Hibi

<sup>1-4</sup>Fujita Health University, Toyoake, Aichi, Japan

## INTRODUCTION

The prognosis of papillary thyroid carcinoma (PTC) patients is commonly good. However, there are some cases with invasion into the recurrent laryngeal nerve or trachea. To preserve the function of recurrent laryngeal nerve or to avoid resection of trachea, if the invasion was thin and the remnant of carcinoma tissue is microscopically, we chose the shaving procedure rather than radical surgery for keeping quality of life after operation.

## MATERIALS AND METHODS

From April 2005 to June 2016, the number of the initial total thyroidectomy in our institution is 390 cases, of which had the invasion into recurrent laryngeal nerve or trachea is 54 cases. Of 54 cases, radical resection cases are 33 cases and shaving cases are 21 cases (female 17 cases and male 4 cases; mean patient age was 51 years). In this study, we analyzed these 21 cases retrospectively.

## RESULTS

Only one patient died due to poorly differentiated thyroid carcinoma 16 months after the initial operation. The other 20 patients were alive and have no recurrent at site of remnant region during the follow-up period (average of follow-up time is 40.6 months). Ten cases (47.6%) have no complication after operation. Three patients (14.3%) revealed the long lasting paralysis of vocal code. One case revealed the laryngeal edema and one case had Horner's syndrome after operation.

## CONCLUSION

If the carcinoma invasion into recurrent laryngeal nerve or trachea was thin, the shaving procedure is one of the options to avoid complications, and it can follow up safety not inferior to radical procedure.

---

## Pattern of Subclinical Dysthyroidism in a Post-thyroidectomy Cohort: Implications for Supplementary Treatment

<sup>1</sup>Ronald Kintu-Luwaga, <sup>2</sup>Anjali Mishra

<sup>1,2</sup>Mulago National Referral Hospital, Kampala, Uganda

### INTRODUCTION

The disorder in thyroid function is called dysthyroidism. Despite adequate supplementation post-thyroidectomy patients can experience dysthyroidism. This study aimed to assess the prevalence of sub-clinical dysthyroidism following thyroid surgery.

### MATERIALS AND METHODS

This study was conducted at Mulago Hospital, a National Referral Hospital of Uganda and the Teaching Hospital for Makerere University-College of Health Sciences. About 40 patients were consecutively recruited following various types of thyroidectomy and followed up at 6 and 12 months. Any preoperative dysthyroidism was corrected before surgery, so all patients were euthyroid at surgery. At 12 months serum thyroid stimulating hormone, thyroxine (T<sub>4</sub>), and triiodothyronine were measured.

### RESULTS

The mean age was 44.3 years (M:F= 1: 12.3). About 20% of the patients had medical co-morbidities. The types of surgery performed were sub-total thyroidectomy (55%), near total thyroidectomy (25%), and total thyroidectomy (20%). The incidence of postoperative dysthyroidism was 52.5%. About 29.4% of patients undergoing sub-total thyroidectomy had dysthyroidism. Almost all patients (90%) who were on T<sub>4</sub> supplement still had dysthyroidism (p = 0.017). The type of resection done had the greatest significance (p = <0.0001), the majority of those who underwent total or near total thyroidectomy ended up with dysthyroidism, despite being on T<sub>4</sub> supplementation soon after surgery. Other factors associated with dysthyroidism albeit nonsignificantly were presence of preoperative hyperthyroidism, age < 40 years, and female gender.

### CONCLUSION

Early biochemical testing is important to identify early dysthyroidism, and inadequate correction of the hypo- and hyperthyroidism. This can be solved by more frequent follow-up and appropriate dose adjustment.

---

## The Superiority of Continuous *en-bloc* Resection to Piecemeal Resection in Papillary Thyroid Carcinoma

<sup>1</sup>Su Chang, <sup>2</sup>Wang Guimin

<sup>1</sup>The First Hospital of Jilin University, Changchun, Jilin, People's Republic of China

### OBJECTIVE

To estimate whether the new surgery method, "continuous *en-bloc* resection" is superior to piecemeal resection or not for papillary thyroid carcinoma (PTC) in thyroidectomy.

### MATERIALS AND METHODS

The consecutively enrolled 40 patients with PTC underwent piecemeal central lymph node dissection (CLND) after ipsilateral lobectomy plus isthmusectomy (piecemeal resection group). The other consecutively enrolled 60 patients with PTC underwent continuous *en-bloc* resection, which means ipsilateral lobectomy, isthmusectomy, and CLND were conducted together. The operation length, the number of dissected central lymph nodes, and postoperative complications were compared.

---

## RESULTS

No differences were found in the age, gender, operation length, number of dissected central lymph nodes, permanent laryngeal nerve injury, and permanent hypocalcemia between the two groups, all  $p > 0.05$ . However, the rates of transient hypoparathyroidism and transient hoarseness in *en-bloc* resection group were both lower than the piecemeal resection group ( $p = 0.048$  and  $p = 0.041$ , respectively).

## CONCLUSION

“Continuous *en-bloc* resection” is superior to the common piecemeal resection in PTC and it can be the potential dominating thyroidectomy method for patients with PTC in future.

## Use of Laryngeal Mask Airway for Total Thyroidectomy: An Alternative to Intubation

<sup>1</sup>HMP Herath, <sup>2</sup>Samantha Shilpage, <sup>3</sup>TH Pathirana, <sup>4</sup>Nalinda Munesinghe, <sup>5</sup>PMS Samarathunga, <sup>6</sup>Ranil Fernando

<sup>1-6</sup>University Surgical Unit-North Colombo Teaching Hospital, Ragama, Sri Lanka

## INTRODUCTION

Laryngeal mask airway (LMA) provides a less complicated method of ventilating patients during surgery under general anesthesia. Muscle relaxation is not indicated in LMA ventilation. Total thyroidectomy falls under the category where muscle relaxation is not an absolute necessity. Problems following endotracheal intubation (throat irritation), especially in neck surgery, can complicate management in the postoperative period.

## MATERIALS AND METHODS

Experience of five patients who underwent thyroidectomy with LMA is described. Four patients required LMA due to difficulty with intubation. One patient had multinodular goiter complicated by myasthenia gravis and could not be given relaxation. All patients had benign multinodular goiter.

## RESULTS

A conventional total thyroidectomy was performed using nerve encountering, parathyroid preserving, and capsular dissection technique. The duration from induction to full recovery was approximately 2 hours. Retraction of the strap muscles and access to thyroid gland was not a problem without muscle relaxants. The only difficulty was the need to reposition the LMA, which was displaced due to manipulation of the thyroid gland and trachea. All patients recovered and we discharged on postoperative day 1. Throat irritation which is a common side effect following endotracheal intubation was not complained of. None of the patients had hoarseness of voice and difficulty of breathing postoperatively.

## CONCLUSION

Laryngeal mask airway is a viable alternative to endotracheal intubation. A controlled trial is planned to address this issue.

## Great Vessel Invasion by Differentiated Thyroid Cancer: Management and Outcomes

<sup>1</sup>Goonj Johri, <sup>2</sup>Gyan Chand, <sup>3</sup>Anjali Mishra, <sup>4</sup>Amit Agarwal, <sup>5</sup>Gaurav Agarwal, <sup>6</sup>AK Verma, <sup>7</sup>SK Mishra

<sup>1-7</sup>Department of Endocrine Surgery, Sanjay Gandhi Postgraduate Institute of Medical Sciences, Lucknow, Uttar Pradesh, India

## INTRODUCTION

Past few decades have witnessed a rise in the incidence of locally invasive thyroid cancer (6–13%). Invasion of great veins is rare, indicates aggressive disease behavior, and poor outcome. Radical surgery followed by high-dose radioiodine ablative therapy (RAI) with or without external beam radiotherapy (EBRT) and thyroid-stimulating hormone (TSH) suppression is essential for management.

## MATERIALS AND METHODS

We reviewed our institutional database of patients with differentiated thyroid cancer (DTC) operated between 2004 and 2014. Previously untreated patients with local invasion of internal jugular (IJV), brachiocephalic, or superior vena cava detected preoperatively, intraoperatively, or on final histopathology were identified. Clinicopathological profiles, operative findings including structures involved, extent of resection, adjuvant therapy details, and outcomes on follow-up were studied.

## RESULTS

A total of 751 patients of DTC were identified; 81(10.9%) had locally invasive disease, 12 patients required IJV resection (11 at primary surgery and 1 for recurrence) due to extensive tumor thrombus/infiltration/encasement of vessel, and three patients, only R2 resection was possible due to subclavian vein infiltration. About 72.8% had simultaneous invasion of multiple structures like strap muscles, aerodigestive tract, and recurrent laryngeal nerve; 4/12 (30%) final histopathology showed IJV invasion. All patients received thyroxine suppression. Two patients were lost to follow-up. One patient had negative scan; 9/12 received high-dose ablation. One patient was referred for EBRT. Longest follow-up was 72 months and one patient died within 7 months of diagnosis.

## CONCLUSION

Differentiated thyroid cancer invading into great veins, although a marker of aggressive disease, radical resection, and adjuvant treatment with RAI, EBRT, and TSH suppression, offers good long-term outcome in nonmetastatic patients.

---

## Predicting Factor for Bilaterality in PTC with Tumor Size <4 cm in Malaysia vs Japanese and ATA Guidelines

<sup>1</sup>B Suhairil, <sup>2</sup>MY Nur Jannah, <sup>3</sup>Mahamad Sadhana

<sup>1</sup>Department of Surgery, Putrajaya Hospital, Putrajaya, Malaysia

## INTRODUCTION

Total thyroidectomy is the common practice for proven papillary thyroid carcinoma (PTC) either by fine-needle aspiration cytology with or without ultrasonography-guided biopsy. However, in the 2015 ATA guidelines and Revisiting Japan Guideline 2014, either lobectomy or total thyroidectomy was recommended for thyroid cancer <4 cm without extrathyroidal extension (ETE) and lymph node (LN) metastasis. We aim to investigate the determinance of bilaterality in PTC patients with tumor size <4 cm.

## MATERIALS AND METHODS

Our study retrospectively reviewed 53 PTC patients who underwent total thyroidectomy with or without MRND between 2006 and 2016 in our center with the tumor size <4 cm.

## RESULTS

Histopathological examination of nine patients (16.9%; 6 males and 3 females) revealed involvement of the isthmus and contralateral thyroid lobes in PTC patients with tumor size <4 cm with the predictive factors (sex, extrathyroidal involvement, and LN metastasis).

## CONCLUSION

Male sex, presence of ETE, and LN metastasis are the predictive factors of bilaterality involvement in PTC <4 cm, thus total thyroidectomy will be a better option. Further close monitoring of patients is needed if patients only undergo lobectomy or hemithyroidectomy to detect malignancies in the contralateral lobe especially those with predictive factors.

---

## Ten-year Follow-up of Patients Who underwent Surgery for Papillary Thyroid Microcarcinoma

<sup>1</sup>Soo Y Kim, <sup>2</sup>Hojin Chang, <sup>3</sup>Seok-Mo Kim, <sup>4</sup>Bup-Woo Kim, <sup>5</sup>Chi Y Lim, <sup>6</sup>Yong S Lee, <sup>7</sup>Hang-Seok Chang, <sup>8</sup>Cheong S Park

<sup>1-4,6-8</sup>Thyroid Cancer Center, Department of Surgery, Gangnam Severance Hospital, Yonsei University College of Medicine, Seoul, South Korea

<sup>5</sup>National Health Insurance Service Ilsan Hospital, Goyang-si, Gyeonggi-do, South Korea

## INTRODUCTION

The incidence of papillary thyroid microcarcinoma (PTMC) has been recently increasing and there are discussions about its treatment strategies because of its excellent prognosis with an indolent disease course. However, there are only few studies, which evaluated the recurrence rate of PTMCs. This study was performed to identify the recurrence of PTMCs during a 10-year follow-up.

## MATERIALS AND METHODS

In this study, 327 patients who underwent thyroidectomy for PTMCs at Thyroid Cancer Center, Gangnam Severance Hospital and who were followed up for more than 10 years were retrospectively analyzed.

## RESULTS

Of the 327 patients, there were 295 (89.9%) females, mean age was 46.4 to 9.8 and with tumor size of  $0.6 \pm 0.2$ . Eighteen patients (5.5%) initially presented with lateral neck metastasis and underwent total thyroidectomy with lateral lymph node dissection. In 122 patients (37.3%), lobectomy was performed, whereas 187 patients (57.2%) underwent total thyroidectomy. Mean follow-up time was  $136.5 \pm 12.7$  months. During the follow-up time, recurrence was observed in 13 (4%) patients. Recur site was identified as follows: op bed 2 (15.4%), regional 10 (76.9%), distant 1 (7.7%). Mean time to recurrence was  $64.8 \pm 30.3$ .

## CONCLUSION

Although PTMC has been known to have an excellent prognosis, our study revealed that initial lateral neck node metastasis occurred in 5.5%. During the follow-up time of 10 years, in 4% of the patients, recurrence was observed, with lateral neck nodes to be most frequent site of recurrence.

## Posters Day 2 March 9, 2018

### Influence of Thyroidectomy on Obesity of Aged Patients

<sup>1</sup>Min-Young Park, <sup>2</sup>Ah-Leum Ahn, <sup>3</sup>Jae-Kyung Choi, <sup>4</sup>Young-Bum Yoo, <sup>5</sup>Jung-Hyun Yang, <sup>6</sup>Kyoung S Park

<sup>1-6</sup>Konkuk University Medical Center, Seoul, South Korea

#### AIM

Thyroidectomized patients complain of weight gain, identifying their thyroidectomy as the event precipitating subsequent weight gain. However, the relationship of obesity after thyroidectomy and remnant thyroid amount is not clear. The purpose of this study was to determine whether thyroidectomized patient experienced obesity postoperatively in patients receiving total thyroidectomy or lobectomy.

#### MATERIALS AND METHODS

We performed a retrospective chart review of subjects receiving medical care at an academic medical center from June 2009 to December 2013. We compared clinical characteristics and obesity-related factors of preoperative and postoperative status in 227 patients who underwent total thyroidectomy (n = 124) or lobectomy (n = 103).

#### RESULTS

At baseline, patients who underwent total thyroidectomy were older (mean age 48.5 years) than those who underwent lobectomy (mean age 42.8 years) ( $p < 0.001$ ). There were no significant differences in baseline weight, height, and laboratory results. There were no significant differences concerning changes in weight and body mass index from the start to completion of the study ( $p = 0.516$  and  $p = 0.684$ ). Females over 45 years of age who underwent total thyroidectomy group had a higher risk of postoperative obesity than those who received lobectomy (odds ratio = 3.78,  $p = 0.012$ ).

#### CONCLUSION

Despite the perception of many patients that remnant thyroid tissue is correlated with obesity, patients who had undergone total thyroidectomy in the previous year did not gain more weight than those who had undergone lobectomy. The risk of obesity was higher in females over 45 years of age who received total thyroidectomy *vs* lobectomy.

### Postlobectomy Serum Thyroid-stimulating Hormone Level is a Prognostic Factor in Low- and Intermediate-risk Papillary Thyroid Carcinoma

<sup>1</sup>Yu-mi Lee, <sup>2</sup>Tae-Yon Sung, <sup>3</sup>Jong H Yoon, <sup>4</sup>Ki-Wook Chung, <sup>5</sup>Suck J Hong

<sup>1-5</sup>Department of Surgery, Asan Medical Center, University of Ulsan College of Medicine, Seoul, South Korea

#### INTRODUCTION

We performed this study to determine the target thyroid-stimulating hormone (TSH) value that affects structural recurrence in patients with low-risk and intermediate-risk papillary thyroid carcinoma (PTC) who underwent a thyroid lobectomy.



## MATERIALS AND METHODS

Patients with PTC (n = 1047) who received a thyroid lobectomy and central compartment node dissection were included in this study.

## RESULTS

Structural recurrence occurred in 42 of the patients (4.0%) and none of the patients died from PTC. By multivariate analysis, primary tumor size (with a cut-off of 0.85 cm) and the serum TSH level measured 1 year after initial therapy (with a cut-off of 1.85 mU/L) were independent risk factors for structural recurrence.

## CONCLUSION

Thyroid-stimulating hormone levels during the early postoperative period need to be monitored and maintained in a lower normal range, even in patients with low-risk and intermediate-risk PTC who undergo a thyroid lobectomy.

---

# Zuckerkindl's Tubercle in Nodular Goiter causing Airway Compression: The Answer is Always Right

<sup>1</sup>Shun-Siang Chong, <sup>2</sup>Shih-Ming Huang

<sup>1,2</sup>Surgical Department, Faculty of Medicine, University of Malaya, Malaysia

## INTRODUCTION

Zuckerkindl's tubercle (ZT) is a protrusion from the thyroid gland at its posteromedial border. The size varies, but it serves as the landmark to identify the recurrent laryngeal nerve during thyroidectomy. It can cause airway compression even though the size of nodular goiter is small, as long as the ZT is prominent. In this study, we proved that the posterior indentation of airway by ZT is always from the right side of a nodular goiter. If left untreated, it will subsequently result in airway compression.

## MATERIALS AND METHODS

We identified 145 patients from the endocrine clinic with benign nodular goiter and prominent ZT by ultrasound and subsequently computed tomography (CT) of the neck. Posterior compression of the trachea by ZT was identified by the cross-sectional view of CT scan.

## RESULTS

Eighty-six patients (59.3%) had prominent right ZT, 37 patients had prominent left ZT (25.5%), and 22 patients showed bilateral prominent ZT (15.2%). Out of 86 patients with right ZT, 17 patients demonstrated posterior indentation of trachea (19.8%), whereas only one patient presented with trachea posterior indentation by the left ZT (2.7%). For those with bilateral ZT, two patients had trachea indentation posteriorly from the right ZT (9.1%). All patients exhibited certain degree of lateral compression by the nodular goiter.

## CONCLUSION

Because of the special anatomy of the neck, a high incidence of right ZT in nodular goiter is liable to cause posterior compression of trachea, which later causes significant airway narrowing that requires surgical resection.

---

# Giant Adrenal Liposarcoma

<sup>1</sup>AC Leong, <sup>2</sup>KY Wong, <sup>3</sup>A Adibah, <sup>4</sup>B Anita, <sup>5</sup>B Sarinah, <sup>6</sup>NA Hisham

<sup>1-6</sup>Hospital Putrajaya, Damansara Utama, Malaysia

## INTRODUCTION

Liposarcomas are rare malignant tumors of fatty tissue and they are the second commonest type of soft-tissue sarcoma. It is known to usually involve the extremities, retroperitoneum, and inguinal region. Rarely, it is found in areas in which most of body fat is usually stored. Fatty tumors of the adrenal are uncommon and have not received much attention in literature. From published literature, the more common adrenal lipomatous tumors are lipomas, teratomas, and angiomyolipomas. The first case of documented liposarcoma was in 2001 and since then it has not been widely reported.

Here we report a case of the largest documented giant liposarcoma of the adrenal gland. An unfortunate 59-year-old lady presented with a painless huge abdominal mass measuring 17.2 × 16.5 × 11.7 cm. The complexity of the diagnosis in this rare adrenal lipomatous tumor, its histology, and treatment is discussed. We highlight the aggressive nature of this disease and its poor prognosis despite best surgical treatment.

## Transoral Endoscopic Thyroidectomy by a Vestibular Approach with Endoscopic Retractor

<sup>1</sup>Seok-Mo Kim, <sup>2</sup>Soo Young Kim, <sup>3</sup>Hojin Chang, <sup>4</sup>Jun HakHoon, <sup>5</sup>Bup-Woo Kim, <sup>6</sup>Yong Sang Lee, <sup>7</sup>Cheong Soo Park, <sup>8</sup>Hang-Seok Chang

<sup>1-3,5-8</sup>Department of Surgery, Thyroid Cancer Center, Gangnam Severance Hospital, Yonsei University College of Medicine, Seoul, South Korea

<sup>4</sup>Department of Surgery, CHA Bundang Medical Center, Cha University, Gyeonggi-do, South Korea

### INTRODUCTION

Transoral endoscopic thyroidectomy by a vestibular approach (TOETVA) is a novel technique for thyroid cancer operation. Compared with other endoscopic approaches including transaxillar or bilateral axillo-breast approach, it requires substantial dissection to reach the thyroid and provides the shortest access to the target organ. The aim of this study was to report on our initial experiences with transoral endoscopic thyroidectomy by a vestibular approach with endoscopic retractor for the management of thyroid carcinoma.

### MATERIAL AND METHODS

From September 2016 to October 2017, 70 patients with thyroid cancer underwent TOETVA. We used a three-port technique through the oral vestibule with endoscopic retractor, and thyroidectomy with central compartment dissection was performed endoscopically using conventional laparoscopic instruments and an ultrasonic device.

### RESULTS

All patients had papillary thyroid carcinoma. Less than total or total thyroidectomy with ipsilateral central compartment node dissection was performed (67 vs 3). The mean operation time was 96.5 minutes (56–213 minutes). The average number of lymph nodes resected was 2.6 (1–12). Three patients experienced a transient hoarseness, which was resolved within 3 months. Most of the patients could return home within 3 days after surgery.

### CONCLUSION

The TOETVA is safe and feasible and provides an excellent cosmetic outcome.

## Thyroid Malignancies among Patients with Thyroid Swellings: A Clinicopathological Profile from Eastern India

<sup>1</sup>Samajdar Debabrata, <sup>2</sup>VP Singh

<sup>1,2</sup>Command Hospital Eastern Command, Kolkata, West Bengal, India

### INTRODUCTION

The annual incidence of thyroid cancer varies considerably in different registries, ranging from 1.2 to 2.6 per 100,000 individuals in men and from 2.0 to 3.8 per 100,000 in women. However, there is no definite data from Indian subcontinent. This study is an effort to understand the clinicopathological profile of thyroid swellings in Eastern India.

### MATERIALS AND METHODS

Prospective observational study, carried out at this Armed Forces Tertiary care Hospital in Eastern India. All patients presenting with thyroid swelling from January 2016 to June 2017 were studied. Patients with proven malignancies were excluded. All patients underwent surgery.

### RESULTS

In this study a total of 60 patients were evaluated using clinical, radiological, and final histopathological evidence. These patients were in the age group between 20 and 80 years of age and qualified for inclusion in the study based on the criteria defined earlier. A total of 12 participants, i.e., 20%, were eventually found to have thyroid malignancy. The remaining 48 patients, i.e., 80% of the study group had benign thyroid neoplasms. Ultrasonography (USG) thyroid with TIRADS and USG-guided fine-needle aspiration cytology (FNAC) were most important determining factors.

### CONCLUSION

When ordering for preoperative ultrasound (US) scan of thyroid, a surgeon should specifically ask for the visualization of echogenicity, nodularity, microcalcification, lobar involvement, and presence of neck node. Preoperative TSH levels should be documented among all patients being planned for surgery. Whenever possible FNAC should be performed under ultrasound guidance.

# Single Center Surgical Experience in Thyroid Malignancy in Isolated Himalayan State

<sup>1</sup>Bharat Nair, <sup>2</sup>AK Kaundal, <sup>3</sup>B Nair, <sup>4</sup>S Sultania, <sup>5</sup>D Thomas, <sup>6</sup>K Guleria, <sup>7</sup>K Malhotra

<sup>1-4,6,7</sup>Department of General Surgery, Indira Gandhi Medical College, Shimla, Himachal Pradesh, India

<sup>5</sup>Department of Otorhinolaryngology and Head and Neck Surgery, Indira Gandhi Medical College, Shimla, Himachal Pradesh, India

## INTRODUCTION

Thyroid cancer is the most common endocrine malignancy worldwide. However, no current data are available for this Himalayan region. Our center is trying to accumulate data to understand pattern and identify problems faced in the management of thyroid malignancies.

## MATERIALS AND METHODS

This was a retrospective record-based study. Prior IRB permission was taken. I.G.M.C Shimla, an 800-bedded hospital is also the Regional Cancer Center, located in Himalayan belt and caters to population of about 5 million people with large numbers living in remote areas, serving as the only tertiary center in the region. Epidemiological data for patients diagnosed with thyroid malignancy during past 2 years were collected. From this data 38 patients who were operated were identified and records analyzed.

## RESULTS

About 31.5% patients were male (mean age 40.20 years), 69.42% were female (mean age 50.50 years).

Highest number were operated for papillary carcinoma 68.42% (n = 26) then follicular carcinoma 21.05% (n = 8), 5.26% (n = 2) for medullary, and 5.26% (n=2) for Hurtle cell carcinoma. Mean age for malignancies was 39.56 years for papillary, 43.75 years for follicular, 45.00 years for medullary, and 60.5 years for Hurtle cell. Two cases of anaplastic carcinoma were also studied.

## CONCLUSION

Study represents population from isolated Himalayan state with distinct geographic-environmental and dietary habits. Wide spectrum of thyroid malignancies are prevalent here. There is high degree of social stigma attached to cancer hence most patients present with advanced disease and there is poor follow-up in many cases. Greater awareness needs to be generated among population regarding screening, treatment options, and importance of follow-up.

# Aggressive Surgical Management of Patients with Follicular Thyroid Carcinoma with Skeletal Metastases

<sup>1</sup>M Shreyamsa, <sup>2</sup>Anand K Mishra, <sup>3</sup>Pooja Ramakant, <sup>4</sup>Kul R Singh, <sup>5</sup>Naseem Akhthar, <sup>6</sup>Chanchal Rana

<sup>1-6</sup>Department of Endocrine Surgery, King George's Medical University, Lucknow, Uttar Pradesh, India

## INTRODUCTION

Distant metastasis is a well-documented occurrence in natural history of thyroid malignancies, particularly in follicular carcinoma (FTC). Metastases at initial presentation involving bone are rare.

## AIM

To assess aggressive surgical and adjuvant treatment outcomes in patients with FTC-skeletal metastases.

## MATERIALS AND METHODS

We had total 238 patients of thyroid swellings from July 2016 to October 2017 out of which 48 were malignancies, 5 of which were FTC with accessible skeletal metastases and 2 with multiple high burden metastases. All seven underwent total thyroidectomy (TT) with radioactive-Iodine ablation (RAIA) along with additional appropriate therapy (mentioned in each case).

Patient 1: A 44-year-old lady with thyroid swelling for 2 years and swelling over right clavicle for 6 months. Computed tomography showed metastasis in clavicle, sternum, tumor thrombus in SVC.

Additional: MRND+CCLND, excision of hemiclavicle, manubrium, and SVC tumor-thrombectomy.

Patients 2 and 3: A 45-year-old lady and 50-year-old gentleman with thyroid mass for 4 years and swelling over left clavicle for 8 months.

Additional: Hemiclaviclectomy.

Patients 4 and 5: A 58-year-old gentleman with thyroid mass for 4 years and swelling over left clavicle for 4 months. Computed tomography showed retrosternal extension, clavicular and sternal metastases, multiple large mediastinal nodes with encasement of vessels. Other patient 46-year-old lady with thyroid swelling, skull, and multiple skeletal metastases.

Additional: EBRT.

Patient 6: A 48-year-old gentleman with thyroid swelling and skull metastases.

Additional: Skull metastasectomy.

Patient 7: A 65-year-old lady with thyroid mass for 20 years, cervical lymphadenopathy for 8 months. Computed tomography showed solitary left 7th rib metastasis.

Additional: MRND+CCLND and rib excision.

No major morbidity in perioperative period. One patient died 1.5 years after treatment, rest all are doing well.

## CONCLUSION

Aggressive excision of skeletal metastases is a feasible option for isolated/accessible metastases followed by RAI and multimodality treatment works better in widespread metastatic FTC.

## Does Neutrophil: Lymphocyte Ratio Affect Thyroid Tumorigenesis in Both Benign and Malignant Disease Biology?

<sup>1</sup>VVHPK Sasi Mouli, <sup>2</sup>Pooja Ramakant, <sup>3</sup>Anand Mishra, <sup>4</sup>Kul R Singh, <sup>5</sup>Chanchal Rana, <sup>6</sup>M Shreyamsa

<sup>1-6</sup>Department of Endocrine Surgery, King George's Medical University, Lucknow, Uttar Pradesh, India

## INTRODUCTION

Inflammation plays a vital role in tumorigenesis and inflammatory biomarkers like neutrophil:lymphocyte ratio (NLR) are recently being used as prognostic factors for assessing the aggressiveness of thyroid nodules and especially malignancies.

## AIM

To see correlation of NLR in benign and malignant thyroid lesions and also compare data in larger (>5 cm) thyroid nodules vs smaller (≤5 cm) thyroid nodules.

## MATERIALS AND METHODS

We did a retrospective data analysis of all patients with benign and malignant thyroid nodules undergoing thyroid surgery in our department during June 30, 2016 to October 30, 2017.

## RESULTS

Out of total 238 patients with thyroid nodules, mean age was 38.78 years, female:male 5:1, and 79.83% benign (n = 190) and 20.17% malignant (n = 48). As per Table 1 we found patients with higher NLR were more of female gender, not much difference in age group/tumor size/malignancy:benign ratio or thyroid-stimulating hormone (TSH) values as compared with patients with lower NLR.

**Table 1:** Comparison of data in patients with NLR ≤ 2.16 (n = 119) and NLR > 2.16 (n = 119)

Parameters		NLR ≤ 2.16	NLR > 2.16	p-values
Age		38 ± 15.88	36 ± 13.37	0.45
Gender	Male	21	22	0.04
	Female	98	97	
Tumor size	≤5 cm	34	37	0.56
	>5 cm	20	25	
Histology	Benign	96	94	0.69
	Malignant	23	25	
TSH		1.57 ± 1.58	1.03 ± 1.42	0.18
Age group	≤45	68	80	0.13
	>45	35	26	

## CONCLUSION

We did not find any statistically significant difference in tumor biology in relation to patients with higher NLR as compared with those with lower NLR. There may be many other angiogenesis factors, which may play a role in tumorigenesis and that needs further studies for better understanding of disease biology.

# A Family History Promoted Early Detection of the Young Medullary Thyroid Carcinoma

<sup>1</sup>Yuko Ishibashi, <sup>2</sup>Katsutoshi Takahashi, <sup>3</sup>Noriko Makita, <sup>4</sup>Katsunori Manaka, <sup>5</sup>Masahiko Tanabe, <sup>6</sup>Yasuyuki Seto

<sup>1-6</sup>The University of Tokyo Hospital, Tokyo, Japan

## INTRODUCTION

When MEN2A has an autosomal dominant inheritance, and one of the family members is judged as MEN2A, there is a chance to detect and treat early other family members who do not have or develop the disease. We genetically screened the patient's family diagnosed as MEN2A, and we found that the family had the same genetic mutation. Then they received blood tests, ultrasound, CT scan, and were found with an early medullary carcinoma.

## MATERIAL AND METHODS

The case was with the twin brothers who were 21 years old. Their grandfather and father's cousin were diagnosed with MEN2A, and their father had pheochromocytoma and medullary carcinoma of thyroid. Their father received total thyroidectomy and adrenalectomy. He took the genetic checkup from this opportunity. He had *RET* genetic mutation and was diagnosed as MEN2A. Then his twin sons requested taking genetic tests and medical screening from their father's history.

## RESULTS

They also had same mutation as their father. And they also had nodule in thyroid by screening with ultrasound, and were diagnosed with medullary carcinoma. Total thyroidectomy was carried out on the brothers. Now, they are receiving annual checkup and do not have hyperparathyroidism or pheochromocytoma.

## CONCLUSION

The permeability of hereditary medullary carcinoma is 100%. And it relatively develops in young age. Therefore, early diagnosis and treatment are needed for MEN family. In this case, by asking family medical history of MEN2A in detail, we found it possible to do a screening check and detect medullary carcinoma in early stage without symptoms.

---

# Clinicopathological Characteristics and Outcomes in Patients with Poorly Differentiated Thyroid Carcinoma: A 10-year Retrospective Analysis

<sup>1</sup>K Rakesh Chandru, <sup>2</sup>S Zahir Hussain

<sup>1,2</sup>Department of Endocrine Surgery, Madras Medical College, Chennai, Tamil Nadu, India

## INTRODUCTION

Poorly differentiated thyroid carcinoma (PDTC) is a rare malignancy, which exhibits a unique histological architecture and represents the bridge between well-differentiated and anaplastic thyroid cancers. Only few data are available in the literature regarding its clinical behavior and treatment consensus.

## MATERIALS AND METHODS

This is a retrospective study of all PDTC cases diagnosed among the thyroid cancer patients at endocrine surgery department of a tertiary medical centre in South India from 2007 to 2016. The data collected included demographics, clinical presentation, histopathology, treatment, and outcomes.

## RESULTS

Only 19 cases of PDTC were diagnosed among 626 thyroid carcinomas. Patients were in the age group of 40 to 65 years, of which 17 were females and 2 were males. The initial presentation in all cases was goiter. All patients had undergone total thyroidectomy and three patients had additional neck dissection. Adjuvant radiotherapy was given for all patients except two who received radioiodine therapy. The tumor size ranged from 6 to 13 cm and majority of them were insular subtype. Five patients survived more than 5 years and 12 patients more than 3 years. Three patients had recurrent disease. Lung metastasis was found in 5 cases.

## CONCLUSION

Poorly differentiated thyroid cancer is an aggressive and rare thyroid cancer. The prevalence rate in our study population is 3% and it varies among regions. At present, surgery remains the mainstay of treatment in the control of locoregional disease. Larger studies are required regarding consensus for adjuvant therapy and optimal management of PDTC.

---

## An Audit of Clinicopathological Concordance of TIRADS and Bethesda Classifications in Thyroid Nodule Ultrasound and Cytology

<sup>1</sup>Cheryl Tan, <sup>2</sup>Reyaz S Moi

### INTRODUCTION

Clinicopathological correlation of thyroid nodules is still not well established despite the introduction of the Thyroid Imaging Reporting and Data System (TIRADS) in 2015. An internal audit was conducted a year on comparing the TIRADS scoring with the findings on fine-needle aspiration cytology (FNAC) using the Bethesda System. The aim is to determine the relevance of our concordance previously published.

### MATERIALS AND METHODS

A retrospective analysis of 64 consecutive cases over the following year (January–December 2016) comparing the same single-surgeon-performed bedside thyroid nodule ultrasound findings with the TIRADS classification and FNAC report with the Bethesda Classification. Similar inclusion/exclusion criteria were used. Benign-appearing nodules were classified under TIRADS 2 and 3. Indeterminate lesions were reported as TIRADS 4, and malignant-appearing nodules were classified as TIRADS 5 within the same setting during the ultrasound. All nodules underwent FNAC, and TIRADS findings were then compared with the Bethesda FNAC Classification.

### RESULTS

Of 64 cases, 57 were considered benign or probably benign, 7 were suspicious for malignancy on ultrasound. The overall sensitivity and specificity were 60 and 93.2% respectively, with a negative predictive value of 96.5%. The overall concordance rate was 83% ( $\kappa = 0.65$ ). The values closely resembled our internal audit performed previously.

### CONCLUSION

The internal audit yielded similar results in 2015 and 2016. Therefore, having a consistent approach to reporting TIRADS scoring will aid in our future practice of diagnosing malignancy more accurately on ultrasound.

## The Great Mimicker: A Case and Literature Review of Pheochromocytoma-induced (Takotsubo) Cardiomyopathy presenting with Severe Cardiogenic Shock

<sup>1</sup>Mehak Mahipal, <sup>2</sup>Ng J Jie, <sup>3</sup>Rajeev Parameswaran

<sup>1-3</sup>Division of Endocrine Surgery, National University Health System, Singapore

### INTRODUCTION

Pheochromocytoma presenting with Takotsubo cardiomyopathy and severe cardiogenic shock requiring resuscitation with extracorporeal membrane oxygenation (ECMO) is rare.

### MATERIALS AND METHODS

A 30-year-old lady presented with acute central chest pain on a background of intermittent headaches, dyspnea, flushing of recent onset, and preeclampsia during first pregnancy. Initial investigations revealed significantly elevated troponins with concomitant ST changes on electrocardiogram, metabolic acidosis, and hyperlactatemia. Emergency coronary angiogram revealed normal coronary arteries; however, worsening cardiogenic shock prompted elective intubation and initiation of ECMO. Negative cardiomyopathy screen in the presence of refractory hypertension prompted a search for secondary causes, which returned positive for bilateral adrenal masses. Biochemical investigations showed significantly elevated metanephrines in keeping with functioning pheochromocytoma. She underwent open bilateral adrenalectomy (without the need for cardiac bypass).

### RESULTS

Histology confirmed bilateral pheochromocytoma (right 6.5 cm and left 7.3 cm with a satellite nodule 3.6 cm) limited to the adrenal glands. Postoperative phase was complicated by profound hypotension requiring inotropic support and subsequent pulmonary embolism. Other complications sustained during her treatment included aortic dissection with acute right lower limb ischemia resulting in eventual limb loss and vocal cord paresis. She was discharged when stable and is currently awaiting genetic evaluation.

## CONCLUSION

Pheochromocytoma should be suspected when patients present with Takotsubo cardiomyopathy and severe cardiopulmonary dysfunction of no index cause. Early recognition of this catecholamine induced state permits prompt reversal with appropriate management.

---

## Clinicopathological Evaluation of Papillary Thyroid Microcarcinoma

<sup>1</sup>Kimihito Fujii, <sup>2</sup>Yukie Ito, <sup>3</sup>Mirai Ido, <sup>4</sup>Takahito Ando, <sup>5</sup>Junko Kousaka, <sup>6</sup>Yukako Mouri, <sup>7</sup>Shogo Nakano

<sup>1-7</sup>Aichi Medical University, Ngakute, Japan

## INTRODUCTION

Clinicians sometimes encounter papillary thyroid microcarcinomas (PMC) under 10 mm in diameter that is concomitant with lymph node metastases. In this study, we assessed PMC clinicopathologically to clarify the risk factors that worsen patient's prognosis.

## MATERIALS AND METHODS

Forty-two patients who underwent surgeries were enrolled. The factors assessed include patients' characteristics, pathological findings, and serum thyroid hormonal level.

## RESULTS

The extrathyroidal invasion (denoted as "Ex1 or more," 23 cases) was the strongest risk factor that causes nodal metastases with odds ratio of 17.2 (95% confidence interval: 4.3–68.8). Dividing the patients enrolled into the two groups whether the cancer invade extrathyroidally or not, "Ex1 or more" and Ex0 (means no thyroid capsule invasion, 29 cases), the former group had both the diagnosis of cancer preoperatively and the larger tumor size. The mean tumor diameter with SD of "Ex1 or more" and Ex0 group was  $8.03 \pm 2.23$  (SD) and  $5.49 \pm 2.79$  ( $p = 0.0009$ ) respectively. No significant difference of preoperative serum level of free triiodothyronine, free thyroxine, thyroid-stimulating hormone, and thyroglobulin was recognized between the two groups.

## DISCUSSION

Generally, the prognosis of PMC patients is favorable. However, the theory does not apply to the cases that is associated with nodal metastasis or extrathyroidal invasion. It is controversial whether the resective treatment is required for the proven PMCs or not. For the cases which are associated with extrathyroidal invasion, the regional lymph nodal resection with lobectomy should be performed. Simple respective treatments might be sufficient for the cases of the incidental PMC.

---

## Adrenal Schwannoma: A Rare Incidentaloma

<sup>1</sup>Ajit S Oberoi, <sup>2</sup>Kamal Kataria, <sup>3</sup>Rajinder Parshad, <sup>4</sup>Rajni Yadav, <sup>5</sup>Ankur Goyal

<sup>1-5</sup>All India Institute of Medical Sciences, New Delhi, India

## INTRODUCTION

Adrenal schwannoma is a rare tumor with very few reported cases in literature. It is a slow growing benign nerve sheath tumor rarely presenting as incidentalomas, which is difficult to diagnose on preoperative imaging. Standard management includes adrenalectomy. Histopathology with immunohistochemistry confirms the diagnosis.

## CASE REPORT

An old female presented to surgical outpatient department for left-sided adrenal incidentaloma diagnosed on ultrasound abdomen. Examination revealed normotension with a  $15 \times 15$  cm firm nontender ballotable mass in the left hypochondrium. Ultrasound abdomen revealed oval mass in upper pole of left kidney. Contrast-enhanced computerized tomography (CT) scan was suggestive of a heterogeneously enhancing mass in the left suprarenal location having wide area of contact with renal artery, renal vein, and aorta with no uptake on MIBG SPECT/CT. Blood investigations were suggestive of a nonsecretory adrenal mass. Patient underwent open transabdominal left adrenalectomy. Pathological examination revealed an encapsulated  $14 \times 10 \times 9$  cm mass weighing 900 gm. Histopathological examination revealed adrenal schwannoma, which was immunopositive for S-100. On 2 months follow-up patient is in preserved state of health with no recurrence.

## CONCLUSION

Adrenal schwannoma should be suspected as a rare differential of adrenal incidentaloma. It is difficult to diagnose preoperatively and only histopathology makes the final diagnosis.

---

## Pheochromocytoma presenting as Acute Intestinal Obstruction

<sup>1</sup>J Ferdinant, <sup>2</sup>S Dhalapathy

<sup>1,2</sup>Madras Medical College, Rajiv Gandhi Government General Hospital, Chennai, Tamil Nadu, India

## INTRODUCTION

Pheochromocytoma usually presents as triad of palpitation, headache, and diaphoresis, this case report intends to highlight an unusual presentation of pheochromocytoma as acute intestinal obstruction.

## MATERIALS AND METHODS

A 48-year-old female presented with acute abdominal distention, pain, and vomiting. She was diagnosed as a case of acute intestinal obstruction, on evaluation she had hypertension. Abdominal imaging unraveled adrenal mass, which was biochemically proved as pheochromocytoma.

## RESULTS

Intestinal obstruction was managed conservatively and she was started on alpha-blocker after adequate blockade, she was relieved of intestinal obstruction and after attaining hemodynamic and cardiovascular stability pheochromocytoma was excised uneventfully. Following excision she did not had any further attack of intestinal obstruction and her hypertension was cured.

## CONCLUSION

In cases of acute intestinal obstruction with persistent hypertension high index of suspicion is crucial in unraveling potentially life-threatening underlying pheochromocytoma. Adequate alpha-blockade relieves intestinal obstruction in such cases.

---

## Primary Hyperparathyroidism: A Case Series

<sup>1</sup>Fatimah Nabilah, <sup>2</sup>Nor H Muda, <sup>3</sup>Hussain Mohamad, <sup>4</sup>Siti H Mohamad

<sup>1-4</sup>Department of Surgery, Hospital Sultanah Nur Zahirah, Kuala Terengganu, Malaysia

## INTRODUCTION

Primary hyperparathyroidism (PHPT) is a rare condition caused by overproduction of parathyroid hormone. The prevalence is 0.1 to 1.0% with incidence of 28 cases per every 10,000 individuals in general population. About 80% of PHPT attribute to parathyroid adenoma, 15% is caused by hyperplasia of parathyroid glands, while parathyroid carcinoma accounts less than 1% of the cases. We are reporting on series of PHPT cases that underwent surgical treatment at our center in 2017.

## MATERIALS AND METHODS

This is a prospective case study involving six patients operated at our center in 2017. In this case series we tried to look at clinical differences between parathyroid carcinoma and adenoma.

## RESULTS

Six patients, consisting of four females and two males, aged between 12 and 76 years (mean age 40). Mean size of parathyroid adenoma is 3.3 cm compared with 5 cm in parathyroid carcinoma. One pediatric patient presented with rickets-like symptoms, while two patients presented with severe bone disease, such as osteitis fibrosa cystica. Another three cases presented with nonspecific symptoms. All cases undergone parathyroidectomy with three cases had concurrent ipsilateral thyroidectomy.

## CONCLUSION

It is difficult to distinguish between benign and malignant parathyroid tumors from clinical point of view. Generally parathyroid carcinoma associates with more severe complication. Surgeon must practice high index of suspicion to ensure adequate resection and the emergence of parafibrin staining may aid in assessing parathyroid gland.



# Analysis of Clinical Features of Differentiated Thyroid Cancer related to Pregnancy

<sup>1</sup>Meng Xianying, <sup>2</sup>Wang Yaoqi, <sup>3</sup>Jiang Haomin, <sup>4</sup>Zhang Qiang, <sup>5</sup>Chen Guang, <sup>6</sup>Wei Jia, <sup>7</sup>Yang Shuai

<sup>1-7</sup>Department of Thyroid Surgery, The First Hospital of Jilin University, Changchun, Jilin, People's Republic of China

## INTRODUCTION

Differentiated thyroid carcinoma (DTC) is the second most common carcinoma in pregnant women and its clinical features related to pregnancy are important for treatment. We carried out a retrospective study to analyze the relations between pregnancy and DTC in capsule invasion, multicentricity, lymph node metastasis, and coexistence with Hashimoto's thyroiditis and to assist surgeons to make a better treatment program.

## MATERIALS AND METHODS

We reviewed the medical records of 893 female patients who underwent surgery in the Department of Thyroid Surgery, the First Hospital of Jilin University from January 2009 to August 2015. There were 103 patients during pregnancy period, which was defined 9 months before parturition to 1 year after parturition as study group, 619 patients who were after childbirth more than 1 year and 171 patients who did not have childbearing history as control groups. Then we analyzed the relations between pregnancy and clinical features by Statistical Package for the Social Sciences version 19.0 statistical software.

## RESULTS

A total of 893 female patients were included and the average age was 33. All patients were diagnosed as PTC by postoperative pathological examination. We found that there was little difference in capsule invasion, multicentricity of tumor, and coexistence with Hashimoto's thyroiditis between study group and control groups ( $p > 0.05$ ). Comparing the lymph node metastasis between the groups, we found that patients in study group had more lymph node metastasis than control groups ( $p < 0.05$ ).

## CONCLUSION

We had come to the conclusion that pregnancy had no influence on capsule invasion, coexistence with Hashimoto's thyroiditis, and multicentricity. It was worth mentioning that pregnancy may increase the incidence rate of lymph node metastasis.

---

# Analysis of Clinical Features of Differentiated Thyroid Cancer related to Pregnancy

<sup>1</sup>Meng Xianying, <sup>2</sup>Daijiro Kagawa, <sup>3</sup>Ryoko Ono, <sup>4</sup>Takao Miyaguni

<sup>1-4</sup>Naha City Hospital, Naha-shi, Okinawa-ken, Japan

## INTRODUCTION

Sentinel lymph node biopsy (SNB) by patent blue V (PBV) is widely performed in breast cancer surgery. We report two cases with blue urticaria due to PBV used for SNB during breast cancer surgery.

## CASE REPORTS

### Case 1

A 66-year-old female was scheduled for wide excision and SNB of an invasive ductal carcinoma of right breast. She has no medical history and has no oral intake. There was no history of atopy or prior documented drug allergy. Surgery was performed under general anesthesia. Two percent PBV was injected in the periareolar region, and the sentinel lymph node was dissected. Within 30 minutes, she presented with bluish urticarial-like plaques on the head, upper limbs, and trunk; monoammonium glycyrrhizinate glycine L-cysteine hydrochloride was then used. She recovered uneventfully and was discharged from hospital on second postoperative day without skin changes.

### Case 2

A 63-year-old female was scheduled for wide excision and SNB of an invasive ductal carcinoma of the left breast. There was no history of drug allergy. Two percent PBV injected under general anesthesia. Fifty minutes later, the patient presented with blue urticaria around the injection area, which gradually spread through the left upper arm and trunk. There was no other symptoms, and the skin manifestation disappeared 2nd postoperative day.

## CONCLUSION

We reported two cases with blue urticarial due to PBV. One of the early sign of allergic reaction is skin rash. Therefore, it is important to pay attention to skin changes with use of PBV.

---

## Apperception of Endocrine Surgery among Postgraduate Residents in a Tertiary Care Referral Center in South India

<sup>1</sup>Bharadhwaj Ravindhran, <sup>2</sup>Sendhil Rajan

<sup>1,2</sup>Department of Surgery, St. John's Medical College Hospital, Bengaluru, Karnataka, India

### INTRODUCTION

Endocrine surgery is an emerging specialty in India with a significant increase in endocrine surgical procedures performed in recent years. We sought to assess awareness and scope of practice of endocrine surgery among resident doctors at a tertiary care center in South India.

### MATERIALS AND METHODS

In this pilot study, 150 questionnaires were distributed to residents from preclinical, paraclinical, medical, and surgical specialties. The survey aimed to assess their familiarity with the speciality of endocrine surgery. They were also asked to pick the top three surgical specialties in order of preference, who they believed were experts in managing clinical conditions related to endocrine surgery.

### RESULTS

About 111 questionnaires were analyzed with a response rate of 74%. The analysis showed that 69% of respondents were aware of endocrine surgical services provided in the city, and 52% were aware of the same in our hospital. About 94.6% were aware of training programs in endocrine surgery in India; 81% were aware of minimally invasive procedures for endocrine surgical conditions; and 62% believed that short stay surgery was possible in endocrine surgery. Endocrine surgeons were considered the experts by 37% of respondents for thyroid disorders, for parathyroid neoplasms, 38% for pancreatic tumors, 37% for adrenal neoplasms, 72.1% for Cushing's or Conn's adenoma, and 82% for MEN syndromes.

### CONCLUSION

Our study shows that the scope and practice of endocrine surgery are not completely understood by our medical colleagues. Measures at individual and institutional levels are required to improve the apperception of the specialty among health care professionals.

---

## Histological Surprise in a Locally Invasive Thyroid Carcinoma

<sup>1</sup>Bharadhwaj Ravindhran, <sup>2</sup>Sendhil Rajan, <sup>3</sup>Suraj Manjunath, <sup>4</sup>PR Sreenath, <sup>5</sup>Renuka Malipatel, <sup>6</sup>LN Mohan

<sup>1-6</sup>Departments of General Surgery, Pathology& Surgical Oncology, St John's Medical College, Bengaluru, Karnataka, India

### INTRODUCTION

Thyroid cancers invading the trachea are uncommon and usually are poorly differentiated cancers. We present a unique such case.

### CASE REPORT

A 47-year-old female presented to us with a 6-month history of neck swelling and hypothyroidism and had developed noisy breathing for the last 4 months, with gradually worsening dyspnea. Local examination revealed a firm-hard nodular goiter. On imaging, multiple cystic peripherally enhancing lesions involving the whole thyroid gland with tracheal invasion, left internal jugular vein thrombus, and cervical-lymphadenopathy were seen. Bronchoscopy revealed a subglottic-intraluminal growth. Fine needle aspiration and core needle biopsy from the lesion were suggestive of Hashimoto's thyroiditis. Patient was planned for neck exploration. Intraoperatively, a gray white tumor completely replacing the thyroid gland with left internal jugular vein thrombus was seen. The tumor was found to be invading the larynx and trachea extrinsically as well. The tumor was invading the thyroid ala, cricoid, and proximal trachea with pharynx. In view of advanced tumor and high suspicion of aggressive poorly differentiated malignancy, and refusal of the patient to undergo a laryngectomy, total thyroidectomy with tracheal shave was done. Histopathology revealed adenoid cystic carcinoma arising from the trachea and involving the entire thyroid gland.

## CONCLUSION

Adenoid cystic carcinoma of trachea accounts for 1% of respiratory tract cancers. Generally considered a slow-growing tumor with prolonged clinical course, extrinsic invasion of adjacent structures is very rare. The case reported a rare variant of adenoid cystic carcinoma of the trachea, which locally invaded the thyroid gland, simulating an aggressive malignancy.

---

## Transoral Endoscopic Thyroidectomy Vestibular Approach (TOETVA): Preliminary Experience in a Single Center

<sup>1</sup>N Siddhartha Chakravarthy, <sup>2</sup>AJ Cherian, <sup>3</sup>Deepak Abraham, <sup>4</sup>MJ Paul

<sup>1-4</sup>Department of Endocrine Surgery, Christian Medical College, Vellore, Tamil Nadu, India

## INTRODUCTION

Transoral endoscopic thyroidectomy vestibular approach (TOETVA) is a novel technique and has excellent cosmesis.

## MATERIALS AND METHODS

From August 2016 to August 2017 a total of four patients underwent TOETVA. A three-port technique of one 10 mm and two 5 mm ports was used through the oral vestibule.

## RESULTS

All four patients were women. Two underwent total thyroidectomy and two had hemithyroidectomy. Two patients had multinodular goiter and two had solitary thyroid nodule. All were benign on fine needle aspiration cytology and ultrasound and requested surgery for cosmesis. Mean age of the patients was  $30 \pm 11.5$  years, mean tumor size was  $3.4 \pm 0.47$  cm. Mean operating time in total thyroidectomy and hemithyroidectomy was  $262 \pm 137.8$  and  $165 \pm 21.2$  minutes respectively. Nodular hyperplasia was present in three patients and one had adenomatous hyperplasia. Two patients had transient numbness of the lower lip, which recovered in 6 weeks; one patient had temporary hypocalcemia and was normocalcemic after 3 months. None of them had voice change, hematoma, or surgical site infection. There was no case of conversion to conventional thyroidectomy.

## CONCLUSION

TOETVA is true scar less technique of thyroidectomy for patients who want cosmetic surgery. The advantage of this technique is good cosmetic results with no increase in complications. The time taken for this procedure could decrease with increasing surgeon's experience.

---

## Can the Brown Tumor of Mandible in Tertiary Hyperparathyroidism regress after Parathyroid Removal: A Case Report and Review of Literature

<sup>1</sup>MH Nasheef, <sup>2</sup>Mahamad Sadhana, <sup>3</sup>AC Leong, <sup>4</sup>B Anita

<sup>1-4</sup>Department of Breast & Endocrine Surgery, Putrajaya Hospital, Kajang, Selangor, Malaysia

## INTRODUCTION

Brown tumor (BT) is a noncancerous lesion resulting from abnormal bone metabolism in hyperparathyroidism (HPT). It creates a local destructive effect at the bone. Renal failure (RF) patients with hypocalcemia cause a long-standing hypersecretion of parathyroid hormone (PTH). The parathyroid gland (PG) gains an autonomous character that cause tertiary hyperparathyroidism (THPT). Increased circulating levels of PTH result in increased osteoclastic bone resorption in cortical bone. Mandible is a commonly affected site. We presented a case of BT in a young female patient associated with THPT, which have recovering affect after parathyroid surgery.

## CASE REPORT

A 31-year-old lady had RF for 5 years on regular HD. She noticed changes in her facial appearance. She was seen by maxillofacial surgeon, debulking surgery was done, biopsy revealed palatal mass, right lingual area, giant cell lesion consistent with BT of HPT. Her serum calcium 2.14 mmol/L, PTH 569 pmol/L. In view of worsening symptoms of THPT and BT, total parathyroidectomy was done in August 2017. Postsurgery, her swelling regressed.

## DISCUSSION

Parathyroid surgery is the gold standard management of BT. The PTH level will return to normal, thus leading to decrease in BT or resolve spontaneously. We reviewed few studies published in high-impact journals in which authors reported regress of

the BT of the mandible. Brown tumor however is avoidable if early detection and prompt treatment was made simultaneously by endocrinologist, radiologist, and surgeon.

## Hashimoto's Thyroiditis has no Impact on the Outcomes of Papillary Thyroid Cancer

<sup>1</sup>Mehak Mahipal, <sup>2</sup>Joel Lau, <sup>3</sup>Samantha P Yang, <sup>4</sup>Sujith Wijerathne, <sup>5</sup>Ngiam K Yuan, <sup>6</sup>Rajeev Parameswaran

<sup>1,2,4-6</sup>Division of Endocrine Surgery, National University Hospital, Singapore

<sup>3</sup>Division of Endocrinology, National University Hospital, Singapore

### INTRODUCTION

Association of papillary thyroid cancer with Hashimoto's thyroiditis (HT) has been reported in literature with conflicting results, with some studies showing a favorable outcome and others not. The aim of our study was to assess the impact of HT in PTC in a South East Asian cohort.

### MATERIALS AND METHODS

Retrospective analysis of 408 patients treated for papillary thyroid cancer from 2000 to 2015 at a tertiary institution. Demographic, clinicopathological profiles, and treatment details were collected. Outcomes analyzed were nodal involvement, recurrence of thyroid cancer, and mortality.

### RESULTS

A total of 408 patients (294 F:114 M) were treated for papillary thyroid cancer of whom 108 (27%) patients showed the presence of Hashimoto's thyroiditis. The mean age of the patients was 46 (15–86) years, with the predominant race being Chinese (58%). The presence of thyroiditis was more commonly seen in women ( $p = 0.009$ ) and Chinese ( $p = 0.007$ ). Similarly, HT was seen in tumors with the presence of extrathyroidal ( $p = 0.04$ ) and extranodal extension ( $p = 0.038$ ), with no correlation with any of the other histopathological parameters studied. Recurrences were seen in 43 (11%) patients with 6 patients in central neck, 24 patients in regional lymph nodes, and 13 patients in distant sites. Cohort mortality was seen in 13 (3%) patients.

### CONCLUSION

Hashimoto's thyroiditis is not associated with adverse outcomes in papillary thyroid cancer.

## Laparoscopic Posterior Retroperitoneal Adrenalectomy in a Superobese Patient (BMI > 60)

<sup>1</sup>Alan SL Tien, <sup>2</sup>Cheng B Yip, <sup>3</sup>Ming K Yew

<sup>1,3</sup>Department of General Surgery, Royal Perth Hospital, Perth, Australia

<sup>2</sup>Department of Anaesthesia, Royal Perth Hospital, Perth, Australia

### INTRODUCTION

Laparoscopic posterior retroperitoneal adrenalectomy (PRA) has gained popularity for benign adrenal lesions. Posterior retroperitoneal adrenalectomy allows direct access to adrenal glands and avoids dealing with intra-abdominal organs. There are concerns about patient transfer, positioning of patient to avoid pulmonary splinting, and technical feasibility in laparoscopic PRA in obese patients. Our aim is to show the feasibility of PRA in a superobese patient [body mass index (BMI) > 60].

### MATERIALS AND METHODS

Our patient was a 37-year-old female with BMI of 60.25 (weight 204 kg/height 1.84 m). She had recurrent Cushing's disease despite multiple procedures for adrenocorticotropic hormone secreting pituitary adenoma and was not responding to medical therapy. She was recommended for bilateral adrenalectomy. Preoperative preparation involved a multidisciplinary approach. Our hospital safe patient-handling team modified current methods for transfer of obese patient. Our medical engineering team custom-made abdominal and chest support with three-dimensional technology to allow abdominal excursion during ventilation and decrease pulmonary splinting. We conducted trials on awake patients weeks before surgery to check for pressure areas and ventilation with the custom-made body support. We also made modifications with port site size and positions and earlier excision of retroperitoneal fat to create larger operative field.

## RESULTS

The operation time was 221 min for bilateral adrenalectomy. Total blood loss was less than 50 mL. The peak ventilator pressure was 35 cm H<sub>2</sub>O with tidal volume of 700 mL and frequency of 12/min. Maximum end-tidal CO<sub>2</sub> was 50 mm Hg. The length of stay was 2 days. Patient required minimal analgesia.

## CONCLUSION

Laparoscopic PRA in superobese patient is feasible and safe.

---

## Tip of the Iceberg: Not Your Typical Titanic Story

<sup>1</sup>Dhiauddin H Ismail, <sup>2</sup>Seniyah M Sikin, <sup>3</sup>Sarajah Arulanantham

<sup>1-3</sup>Hospital Sultan Ismail, Johor Bahru, Malaysia

## INTRODUCTION

Neuroendocrine tumors (NETs) are neoplasms that arise from the cells of endocrine and nervous systems. The NETs of the thyroid are rare, and sometimes metastasis to the thyroid gland from neuroendocrine carcinoma arising elsewhere. We report a rare entity of NETs of the thyroid with retrosternal extension.

## CASE REPORT

A 76-year-old Chinese gentleman presented with airway compromise requiring intubation. He has developed slow-growing neck mass for about a year and they have discovered difficulties to extubate him. The combined ultrasound and computed tomography (CT) scan of the neck revealed an enlarged and heterogeneous left thyroid lobe with retrosternal extension, thyroid in origin. Guided tru-cut biopsy of his left thyroid lobe demonstrated few oncocyctic lesion with infarction necrosis. He was then referred to Endocrine Surgery Unit where he underwent a subtotal thyroidectomy instead, due to dense adhesion to distal most retrosternal portion of left thyroid gland. He remains stable postoperatively with tracheostomy *in situ*.

## RESULTS

Histopathological report showed a malignant and nodular thyroid gland composed of neoplastic cells with extensive necrosis. The immunohistochemicals studies revealed: CgA (+), Syn (+), and Ki-67 (+, > 15%). Ga-68 DOTANOC (PET-CT) scan showed somatostatin receptor avid malignancy in the thyroid gland, cervical nodes, mediastinum, and the right lung. A final diagnosis of neuroendocrine tumor of retrosternal thyroid (grade 2) was given. Limited literature reported on NETs of thyroid with retrosternal extension, looking at further management and prognostication. Currently, he is awaiting Sandostatin treatment.

---

## Unilateral Adrenal Metastasis mimicking an Adrenocortical Carcinoma

<sup>1</sup>Seong-Hong Tan, <sup>2</sup>Ernest CW Ong, <sup>3</sup>Siew-Yep Hoh, <sup>4</sup>Khoon-Leong Ng

<sup>1-4</sup>Endocrine Surgery Unit, Department of Surgery, Faculty of Medicine, University of Malaya, Kuala Lumpur, Malaysia

## INTRODUCTION

Unilateral tumors of the adrenal gland are commonly incidentalomas or functioning benign adenomas. Adrenocortical carcinomas (ACC) are rare, with an incidence of approximately one to two per million population per year. We highlight an unusual case of a 52-year-old man who presented with a short history of right upper quadrant pain. Examination showed a large right hypochondrial mass. Radiological and biochemical investigations pointed toward a non-secreting right ACC with liver infiltration and nodal involvement. No other intra-abdominal lesions were detected. No distant metastases were seen on the Positron Emission Tomography/Computed Tomography scan. An open right adrenalectomy and segmental liver resection were performed. Postoperative recovery was uneventful. Histopathological report of the lesion revealed metastatic adenocarcinoma of unknown origin. The patient is currently undergoing adjuvant chemotherapy.

## Association of Chronic Thyroiditis and Differentiated Thyroid Carcinoma: A Retrospective Cohort Analysis

<sup>1</sup>SA Seneviratne, <sup>2</sup>P Kumara

<sup>1,2</sup>Department of Surgery, Faculty of Medicine, Colombo, Sri Lanka

### INTRODUCTION

Chronic thyroiditis causes progressive autoimmune destruction of the thyroid gland and fibrosis, which may lead to permanent hypothyroidism. Chronic thyroiditis has also been suggested to be associated with development of differentiated thyroid malignancy. We conducted this study to assess the association of occurrence of chronic thyroiditis in thyroid malignancies compared with benign neoplasms and multinodular goiters in patients undergoing thyroidectomy.

### MATERIALS AND METHODS

A retrospective analysis of histopathology reports of patients who underwent thyroidectomy at the Professorial Surgical Unit, National Hospital of Sri Lanka from 2014 July to 2017 June was performed. All patients with a primary histological diagnosis of chronic thyroiditis (n = 20) were excluded.

### RESULTS

Of the total 202 thyroidectomies included, 47 had differentiated thyroid malignancies (23.2%). Of the malignant thyroids 10 (21.2%) had coexistent chronic thyroiditis while 18 (11.6%) out of 155 benign goiters had associated chronic thyroiditis (p = 0.075). Incidence of coexistent thyroiditis was lowest in multinodular goiters (13 out of 113, 11.5%) while 17.2% (5 out of 29) patients with benign neoplasms had associated chronic thyroiditis.

### CONCLUSION

Although there was a tendency for malignant thyroid lesions to be associated with chronic thyroiditis, this difference was statistically not significant. Further studies in a larger cohort are recommended to identify the association between thyroiditis and differentiated thyroid cancer.

## A Case of Bronchogenic Cyst with Suspected Left Adrenal Tumor

<sup>1</sup>Takahiro Mase, <sup>2</sup>Tobinaga Junichi, <sup>3</sup>Masaki Wada, <sup>4</sup>Takao Horiba, <sup>5</sup>Arihiro Shibata, <sup>6</sup>Hironobu Kobayashi

<sup>1-6</sup>Ogaki Tokusyukai Hospital, Ogaki, Japan

### INTRODUCTION

Bronchogenic cyst is usually a congenital anomaly occurring in the mediastinum or pulmonary parenchyma. Since we experienced a case of retroperitoneal bronchogenic cyst, we will report with some literature consideration.

### CASE REPORT

A 38-year-old female was suspected with a left kidney cyst in an abdominal ultrasonography (USG) at a medical examination. Abdominal computed tomography revealed an irregularly shaped and well-defined 86 × 81 mm tumor with a structure on the protrusion, on the inner side of the spleen, and the back of the pancreas. The inside of the tumor exhibited a uniform concentration/signal equivalent to that of the cyst. A left adrenal nonfunctional tumor was suspected and introduced to surgery. Since the fact that the tumor diameter was increasing and showing irregular shape at the USG just before the operation, we judged that the malignancy could not be denied and performed open surgery. The tumor was clear in the boundary with the pancreas and the left adrenal gland, and it was possible to detach easily. In the pathological examination, the cyst was similar to the bronchial wall containing the salivary gland-like acinar tissue, so it was diagnosed as bronchogenic cyst.

### CONCLUSION

We experienced a relatively rare bronchogenic cyst occurring in the retroperitoneal cavity. Because there are reports that it involved malignant findings, it is necessary to carefully select the approach of surgery.

# Calcitonin-negative Medullary Thyroid Carcinoma

<sup>1</sup>PR Sreenath, <sup>2</sup>Rajan Sendhil, <sup>3</sup>Ravindhran Bharadhwaj

<sup>1-3</sup>Department of Surgery, St John's Medical College Hospital, Bengaluru, Karnataka, India

## INTRODUCTION

Medullary carcinoma thyroid originates from parafollicular C cells of the thyroid gland, which produce calcitonin. It is known for its early spread to regional lymph nodes. We present to you a rare case of calcitonin-negative medullary carcinoma.

## CASE REPORT

A 55-year-old lady presented with a 15-year-old history of a left-sided neck swelling. General and systemic examination were within normal limits. Local examination revealed a firm, hard mass over the left side of neck pushing the trachea with impeding fungation. Left-sided cervical lymphadenopathy was also present. On further evaluation, she was found to have metastatic lesions in both lungs. Fine needle aspiration from the cervical lymph node showed metastatic carcinoma and aspirate from thyroid gland showed poorly differentiated carcinoma. Serum calcitonin levels were found to be normal. She underwent Total thyroidectomy with central compartment lymph node dissection and left sided modified radical neck dissection. Multiple firm nodules were noted in both lobes of thyroid with the left lobe being adherent to sternocleidomastoid muscle and left internal jugular vein thrombus. Histopathology revealed a giant cell variant of multifocal medullary carcinoma of thyroid.

## CONCLUSION

Medullary carcinoma of thyroid accounts for 4% of thyroid cancers and are associated with elevated levels of serum calcitonin levels. Higher the level of calcitonin, the greater the likelihood of medullary carcinoma. Calcitonin-negative medullary carcinoma is a rarity in medical literature.

# Intrathyroid Parathyroid Adenoma masquerading as a Thyroid Nodule

<sup>1</sup>Tang M Hon, <sup>2</sup>RM Singaporewalla

<sup>1,2</sup>Department of Surgery, Khoo Teck Puat Hospital, Singapore

## INTRODUCTION

Intrathyroid parathyroid adenoma (iPTH) is rare and the true incidence is less than 1%. We present a case of severe hypercalcemia and marked hyperparathyroidism from a suspected parathyroid tumor where the ultrasound images and needle biopsy report pointed to a thyroid nodule. A 66-year-old gentleman presented with palpitations, nausea, and lethargy. Initial laboratory test showed a raised calcium level of 3.72 mmol/L (N = 1.16–1.32 mmol/L) and parathyroid hormone level (PTH) of 124 pmol/L (N = 1.6–6.9 pmol/L). Parathyroid carcinoma was suspected in view of the markedly raised calcium and PTH levels. Ultrasound of the thyroid showed a 3 cm solid, isoechoic right mid pole thyroid nodule with internal vascularity. Fine needle aspiration cytology showed a Bethesda II thyroid nodule. No enlarged parathyroid glands were seen. Sestamibi parathyroid scan showed intense tracer uptake at the right lower pole. At neck exploration, the right superior parathyroid and thyrothymic area was normal. A hard nodule at the right lower thyroid pole was noted intraoperatively with no identifiable right lower parathyroid gland. An *en-bloc* right hemithyroidectomy, right lower parathyroidectomy, and central compartment lymph node clearance were performed keeping in mind possibility of malignancy. The 15-minute postexcision PTH dropped significantly by 92%. Histology showed a 3.2 cm intrathyroidal parathyroid adenoma with no evidence of malignancy. The right level 6 nodal clearance was negative for malignancy. This case highlights the need to interpret thyroid ultrasound reports and biopsy findings with caution and the importance of intraoperative findings and clinical decision making.

# Nonrecurrent Laryngeal Nerve in Thyroid Surgery: A Case Report in Vietnam

<sup>1</sup>Le V Quang, <sup>2</sup>Ngô X Quy, <sup>3</sup>Ngô Q Duy

<sup>1-3</sup>Vietnam National Cancer Hospital, Thanh Tri District, Hanoi, Vietnam

## INTRODUCTION

The nonrecurrent laryngeal nerve (NRLN) is a rare embryologically derived variant of the recurrent laryngeal nerve (RLN). The proportion of NRLN is about 0.25 to 0.99% in thyroid surgery. The identification and prevention of injury to the laryngeal nerve is one of the main issues in thyroid surgery, thus, thyroid surgeon must have adequate knowledge of all anatomical variations of the RLN.

## MATERIALS AND METHODS

We present a case of a 33-year-old female with thyroid cancer in which NRLN was identified. The patient was discharged without any complication.

## RESULTS

Surgeons revealed that the right laryngeal nerve was not recurrent and it originated directly from the nerve vagus. Moreover, the right subclavian artery of this patient rose directly from the aortic arch. Embryological variant of the NRLNs and their clinical roles were discussed.

## CONCLUSION

The NRLN is a rare clinically relevant structure and is associated with an increased risk of iatrogenic injury, which often leads to temporary or permanent vocal cord paralysis. Thorough anatomical knowledge and cautious dissection are essential to identify any normal variants of NRL, as well as to avoid its injury. Additionally, in terms of embryology, the presence of NRLN is closely related to subclavian artery anomaly.

## The Correlation between Subtotal Thyroidectomy and Calcium Serum Level

<sup>1</sup>Tomasz Zawadzki, <sup>2</sup>Wiktor Krawczyk, <sup>3</sup>Zbigniew Lorenc

### INTRODUCTION

The aim of the study is to determine whether there is a correlation between thyroidectomy and serum calcium level.

### MATERIALS AND METHODS

Retrospective study of 93 patients that underwent sub-total thyroidectomy. Calcium serum level before and after surgery, length of surgery, thyroid hormones level, and amount of resected gland were analyzed.

### RESULTS

Calcium level measured on the first and second day after surgery was compared. The result was not statistically significant,  $t(91) = -1.45$ ;  $p = 0.150$ —calcium serum level did not change significantly between the first and second day. For further analyses we used the average from these two measurements. Postoperative calcium level was compared with preoperative calcium level. The result was statistically significant,  $t(24) = 15.90$ ;  $p < 0.001$ . The effect of surgery on calcium serum level was *very* relevant which equaled 2.71. Longer surgery resulted in lower postoperative calcium levels ( $r = -0.268$ ;  $p = 0.010$ ). Surgery duration correlates positively with the size of decrease in calcium level compared with preoperative measurements ( $r = -0.434$ ;  $p = 0.034$ ). The greatest dimension of the thyroid correlates with the size in decrease in operative calcium level compared with pre-treatment measurements ( $r = -0.613$ ;  $p = 0.020$ ). The size of excised gland correlates with postoperative calcium serum level.

### CONCLUSION

Near-total thyroidectomy results in decrease in serum calcium levels. Length of the surgery correlates with calcium serum level.

## Hyalinizing Trabecular Carcinoma of Thyroid Gland: A Challenge for Diagnosis

<sup>1</sup>K Norhashimah, <sup>2</sup>AH Imisairi, <sup>3</sup>CA Mukarramah, <sup>4</sup>AM Fairus

<sup>1,2</sup>Breast and Endocrine Unit, Hospital Raja Perempuan Zainab II, Kota Bharu, Malaysia

<sup>3</sup>Department of Pathology, Hospital Raja Perempuan Zainab II, Kota Bharu, Malaysia

<sup>4</sup>Department of Diagnostic and Imaging, Hospital Raja Perempuan Zainab II, Kota Bharu, Malaysia

### INTRODUCTION

Hyalinizing trabecular carcinoma of thyroid is an uncommon and unique malignancy of the thyroid gland. It is actually a variant of papillary thyroid cancer due to its similarity in nuclear morphology and immune profile. It contains hyaline material that often confuses it for medullary carcinoma because it mimics amyloid. It is usually misdiagnosed on fine needle aspiration cytology (FNAC).



## CASE REPORT

A 27-year-old gentleman who presented with the complaint of anterior neck swelling for 1-year duration. The swelling gradually increase in size leading to occasional dysphagia for 1-month duration. He was clinically euthyroid. Ultrasound of neck revealed multiple nodules within both lobes. The largest and dominant nodule was in the right lobe. It was ill-defined heterogeneous lesion with presence calcification within and increased intralesional vascularity. Ultrasound-guided biopsy was then performed revealed inconclusive result of hyalinizing trabecular neoplasia, papillary thyroid cancer, and medullary thyroid cancer. Immunohistochemical staining for chromogranin, Congo red, CEA, NSE, CK19 were all negative. His Ki-67 was positive (30%). Tru-cut biopsy under ultrasound guidance was then performed revealed suspicious of squamous cell carcinoma or malignant hyalinizing tumor of thyroid gland. Total thyroidectomy was then performed uneventfully. Histopathological report revealed hyalinizing trabecular carcinoma of thyroid.

## DISCUSSION

We discuss about this rare neoplasm of thyroid and difficulty in diagnosing the disease using FNAC. We also discuss about managing the neoplasm and its different with papillary thyroid cancer.

---

## Edentulous Jaw as Primary Manifestation of Primary Hyperparathyroidism

<sup>1</sup>Sapna, <sup>2</sup>Sabaretnam Mayilvaganan, <sup>3</sup>Saroj Sahoo, <sup>4</sup>C Armal, <sup>5</sup>Navneet K Srivastava, <sup>6</sup>Kishan, <sup>7</sup>SK Agarwal, <sup>8</sup>Amit Agarwal

## INTRODUCTION

Primary hyperparathyroidism (PHPT) usually presents as bone disease, renal, or with gastrointestinal symptoms. Dental symptoms as primary or presenting manifestations are rare. We report two patients who presented with edentulous jaw in young age, which resulted in investigations leading to the diagnosis for primary hyperparathyroidism.

## MATERIALS AND METHODS

We report two patients operated in a tertiary referral center from January 2017 to October 2017 for PHPT with edentulous jaw. We describe the clinical case and surgical findings of these two patients.

## RESULTS

First patient was a 30-year-old lady who had loosening and falling of all teeth suddenly within 2 months; investigations showed hypercalcemia of 13 mg/dL and she had concordant left inferior parathyroid adenoma on ultrasonography and MIBI Scan. She underwent uneventful focused parathyroid with IOPTH monitoring and on follow-up she was normocalcemic. Second patient was a 45-year-old lady who had loosening and falling of most of the teeth with bone pains, it was investigated and she was found to have hypercalcemic crisis of 17 mg/dL. She had an aorta pulmonary window parathyroid adenoma on functional and anatomic imaging. She was treated with hydration, calcitonin, and bisphosphonates and operated in the same admission and underwent sternotomy and focused parathyroidectomy with IOPTH monitoring and on follow-up was normocalcemic.

## DISCUSSION

Dental manifestations are rare but can be the first symptom of PHPT. Severe osteoporosis can manifest as falling of teeth when resorption of jaw occurs due to osteoporosis and tooth become loose and fall off.

---

## Prospective Evaluation of Hungry Bone Syndrome as a Mechanism of Cause of Postoperative Hypocalcemia after Total Thyroidectomy in Subjects with Hyperthyroidism and Its Correlation with Bone Mineral Density

<sup>1</sup>Karunakaran Poongodi, <sup>2</sup>Asokumar Premkumar, <sup>3</sup>Ramalingam Srinivasan, <sup>4</sup>Manickam Rajasekar, <sup>5</sup>Chockalingam Rajasekaran  
<sup>6</sup>Maharajan Chandrasekaran

## INTRODUCTION

Hungry bone syndrome (HBS) is a well-established cause of post-thyroidectomy hypocalcemia in thyrotoxicosis, characterized by profound hypocalcemia, hypomagnesemia, and hypophosphatemia 96 hours after surgery. To date, the incidence and risk

factors associated with development of HBS after total thyroidectomy (TT) remain unclear. This prospective study examined the incidence and predictors of post-thyroidectomy HBS.

## MATERIALS AND METHODS

Thyrotoxic subjects (group I; n = 125; age: mean  $\pm$  standard deviation;  $33.1 \pm 8.1$  years) and 121 euthyroid controls with benign thyroid nodules (group II) undergoing TT were evaluated for bone mineral density (BMD) and serum calcium, magnesium, phosphorus, parathyroid hormone, alkaline phosphatase, 25-hydroxy vitamin D (25-OHD) serially. At least three parathyroid glands were preserved;  $p < 0.05$  was considered significant.

## RESULTS

In group I, 102 subjects (81.6%) had postoperative hypocalcemia. Of these, 42.1% (n = 43; age =  $40.7 \pm 10.7$  years) exhibited HBS, while 57.8% (n = 59, non-HBS group; age =  $33.1 \pm 8.1$  years) did not. Hungry bone syndrome subjects (*vs* non-HBS) had decreased preoperative BMD hip ( $0.760 \pm 0.134$  *vs*  $0.889 \pm 0.149$  gm/cm<sup>2</sup>), spine ( $0.862 \pm 0.129$  *vs*  $1.033 \pm 1.25$  g/sq.cm), 25-OHD ( $24.2 \pm 12$  *vs*  $25.1 \pm 9.8$  ng/dL), postoperative phosphorous ( $3.5 \pm 0.99$  *vs*  $4.69 \pm 1.1$  mg/dL), preoperative ( $1.59 \pm 0.78$  *vs*  $2.06 \pm 0.47$  mg/dL), and postoperative ( $1.48 \pm 0.61$  *vs*  $2.07 \pm 0.59$  mg/dL), magnesium levels (each  $p < 0.05$ ). In multivariate analysis, HBS was associated with low preoperative BMD spine, 25-OHD, hypomagnesemia, and fall in phosphorous levels (each  $p < 0.01$ ). At 6-month post-surgery, three subjects had hypocalcemia. In group II, 21.4% (n = 26) had postoperative hypocalcemia and none exhibited HBS.

## CONCLUSION

Hungry bone syndrome occurs exclusively in thyrotoxic subjects undergoing TT. Vertebral osteoporosis, hypovitaminosis D, preoperative hypomagnesemia, and fall in phosphorous levels within 48 hours after TT is associated with risk of HBS.

## Collision Tumor of the Thyroid, Atypical Parathyroid Adenoma, and Bilateral Pheochromocytoma in a Case of MEN2A with Codon 634 Mutation

<sup>1</sup>Mehak Mahipal, <sup>2</sup>Dexter Chan, <sup>3</sup>Shaun Goh, <sup>4</sup>Sujith Wijerathne, <sup>5</sup>Rajeev Parameswaran

<sup>1-5</sup>Division of Endocrine Surgery, National University Hospital, Singapore

## INTRODUCTION

Medullary (MTC) and papillary carcinoma (PTC) of thyroid gland occurring as a collision tumor with lymph node metastasis from each cancer is rare.

## MATERIALS AND METHODS

A 25-year-old lady presented with symptoms of hypertension, hypercalcemia, and proximal myopathy. Investigations revealed primary hyperparathyroidism, bilateral medullary thyroid cancer on cytology of thyroid nodules with elevated serum calcitonin at 354 pg/mL. Urinary catecholamines were significantly raised and DOPA PET showed bilateral uptake with no foci of metastatic disease. Genetic assessment revealed a codon 634 mutation of the RET gene. She underwent laparoscopic bilateral retroperitoneal adrenalectomy followed by total thyroidectomy, sub-total parathyroidectomy with bilateral selective neck dissection 1 month later.

## RESULTS

Histology revealed bilateral pheochromocytoma on a background of diffuse and nodular medullary hyperplasia, bilateral 1 cm MTC in the thyroid gland, and 1 cm PTC in left thyroid with 2/16 lymph-nodes involved by MTC and 1/16 by PTC respectively in the left neck. Right inferior parathyroid showed adenoma with atypical features. Postoperative recovery complicated by hungry bone syndrome but otherwise well.

## CONCLUSION

Management of collision tumors is challenging due to dual pathology. Ideally cases, such as this should be managed in MDT setting and patient centric. The most aggressive tumor will guide treatment, adjuvant therapy, and follow-up.

# Rare Case of Pheochromocytoma with Unexplained Hypercortisolism

<sup>1</sup>Tang M Hon, <sup>2</sup>RM Singaporewalla

<sup>1,2</sup>Department of Surgery, Khoo Teck Puat Hospital, Singapore

## INTRODUCTION

Rarely pheochromocytomas can cosecrete other substances, such as serotonin, vasopressin, adrenocorticotrophic hormone (ACTH), somatostatin, and neuropeptide. Although the adrenal cortex and medulla are considered distinct functional systems, there seems to be some interactions between them though the exact mechanism remains unclear.

## CASE REPORT

We present a case of a functioning adrenal tumor that was positive for pheochromocytoma and also secreted excessive cortisol. A 41-year-old female presented with palpitations and abdominal discomfort. She had a history of hypertension and diabetes. She was tachycardic and hypertensive. Physical examination was unremarkable with no obvious signs of Cushing's syndrome. Computed tomography scan abdomen revealed a 3.5 cm well-defined right adrenal mass.

Initial hormonal evaluation showed excessive primary cortisol secretion with elevated serum and urinary free cortisol and failure to suppress on low and high dose dexamethasone. Her ACTH level was normal. Urinary pheochromocytoma screen was elevated more than thrice normal levels. After adequate preoperative optimizations, she underwent an uncomplicated right laparoscopic adrenalectomy. Histology showed a benign 3.5 cm tumor in the adrenal medulla that stained positive for pheochromocytoma. There was also a compressed rim of adrenal cortex tissue. The ACTH immunostaining of the tumor was negative.

## CONCLUSION

Her symptoms, hypertension, and diabetes resolved. Repeat hormonal screening tests were all normal. This case highlights that adrenal medullary tumors can rarely cosecrete multiple functional substances. The exact pathophysiology of excessive cortisol secretion in this case remains uncertain.

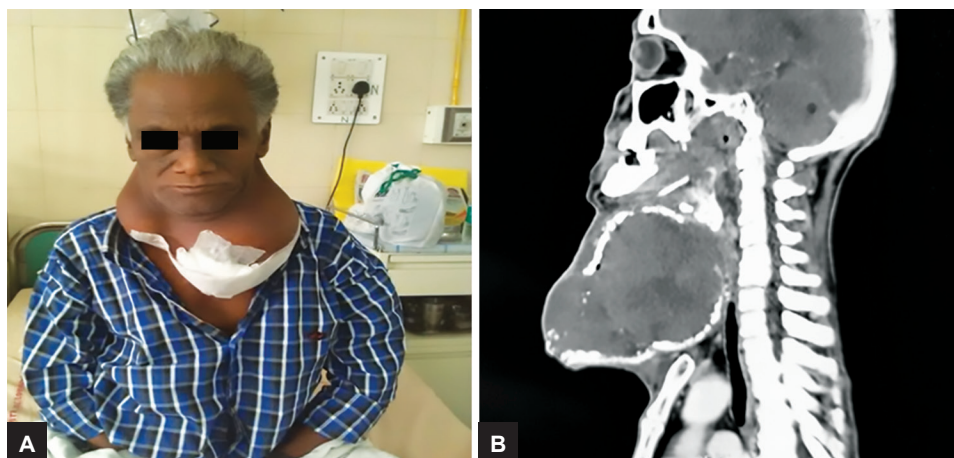
# Riedel's Thyroiditis: A Case Report and Review of Literature

Anukriti Sood

All India Institute of Medical Sciences, New Delhi, India

## INTRODUCTION

Riedel's thyroiditis is a rare benign pathology of thyroid, characterized by a densely fibrotic inflammatory process involving the thyroid gland and the adjacent neck tissues. The rarity of Riedel's thyroiditis adds to the difficulty to differentiate it from malignancy, mainly because of their overlapping symptomatology. We present an unusual case of Riedel's, presented with a huge fixed neck mass with ulceration over the skin and discuss its imagery and pathology.



# From Endoscopic to Robotic-assisted Bilateral Axillobreast Approach Thyroidectomy: Competency acquired through the da Vinci Surgical System Technology Training

<sup>1</sup>Yahya M Aripin, <sup>2</sup>Mohd Z Dimon, <sup>3</sup>Kyung H Kang

<sup>1,2</sup>Faculty of Medicine, Universiti Teknologi MARA, Sungai Buloh, Selangor, Malaysia

<sup>3</sup>Department of Surgery, Chung-Ang University Hospital, Chung-Ang University College of Medicine, Seoul, South Korea

## INTRODUCTION

Conventional training for a new surgical technology typically dictates closed supervision by a mentor within a period of apprenticeship. Robotic surgery is however a minimally invasive surgery, which has very much the same principles as endoscopic surgery. An experienced endoscopic surgeon may just need training on the technology of the robotic system for a safe and effective robotic-assisted surgery.

## MATERIALS AND METHODS

We presented the first seven robotic surgeries performed by an experienced endoscopic surgeon who had completed a structured da Vinci robotic system technology training. Parameters for assessing competency were surgical complications, operation time, and conversion rate.

## RESULTS

The patients were six women and one man, aged from 31 to 60 years. Diagnoses include follicular adenoma, colloid nodule, multinodular goiter, and toxic nodular goiter. Five patients had hemithyroidectomy and two had total thyroidectomy. Average console time for hemithyroidectomy was 164 minutes (131 to 250 minutes). There was no conversion to open surgery. One patient had postoperative transient hypocalcemia. There was no vocal cord palsy, swallowing difficulty, restricted neck movement, or significant pain in the upper chest. All hemithyroidectomy patients were discharged on the second postoperative day.

## CONCLUSION

Technology training alone is sufficient for an experienced endoscopy surgeon to embark on robotic-assisted surgery.

## Clinicopathological Features of Goiter in Abakaliki, Nigeria

<sup>1</sup>Nneka A Sunday-Nweke, <sup>2</sup>Vincent C Enemu, <sup>3</sup>Chinedu C Nwigwe, <sup>4</sup>Amobi C Ogonu

<sup>1-4</sup>Department of Surgery, Federal Teaching Hospital Abakaliki, Ebonyi State, Nigeria

## INTRODUCTION

The prevalence of goiter is greater in countries affected by moderate or severe iodine deficiency, where it is said to be endemic. Thyroid swellings are four times more common in females. Most thyroid swellings are benign, a wide variation is observed in malignancy; 5% of clinical thyroid nodule is malignant while 85 to 20% surgical thyroid specimens are malignant. Fine needle aspiration cytology (FNAC) and ultrasonography are very useful tools in making preoperative diagnosis. Preoperative indirect laryngoscopy is important to assess the positions of the vocal cord and for medicolegal reasons. When treatment is considered, patients performance status, goiter type, success related to treatment option, and regional trends are usually influential.

## AIM

To study the clinicopathological features of goiter and its surgical treatment in Abakaliki, Nigeria.

## MATERIALS AND METHODS

This was a retrospective study. Total of 28 cases of goiters were studied. Patients aged 17 years to 65 years of both sexes with complaints of anterior neck swelling were included. Patients were subjected to clinical examination, neck ultrasonography, thyroid function test, FNAC, and indirect laryngoscopy. Patients were accordingly treated with medical and surgical modes of treatment. All operated specimens were sent for histological evaluation.

## RESULTS

Of all cases, 24 (85.7%) cases were females and 4 (14.3%) cases were males. All cases presented with anterior neck mass. Twenty-two (78.6%) cases were simple multinodular goiter, 3 (10.7%) cases were toxic goiters, and 3 (10.7%) cases were suspected to be malignant. Fine needle aspiration cytology showed 25 (89.3%) benign cases and 3 (10.7%) suspected cases of malignancy. Subtotal thyroidectomy was done for all benign cases and total thyroidectomy for suspected cases of malignancy. All operated specimen underwent histopathological examination of which 25 (89.3%) cases were benign and 2 (10.7%) cases were malignant.

## CONCLUSION

In Abakaliki, Nigeria, the pathological presentation of goiter is usually benign and clinical feature is predominantly of simple goiter.

---

## Parotid Oncocytoma: A Rare Entity to mislead

<sup>1</sup>K Shrikiran, <sup>2</sup>Salelkar Reshama, <sup>3</sup>FP Noronha, <sup>4</sup>Samant Dattaprasad

## INTRODUCTION

Salivary gland tumors are among the complex and diverse kind of neoplasms, causing challenges in diagnosing and surgical management. Parotid gland oncocytoma with incidence of less than 1% pose a clinical challenge since it misleads to pleomorphic adenoma. We present a case of 42-year-old male with right-sided benign swelling turning out to be parotid oncocytoma.

## MATERIALS AND METHODS

A 42-year-old male presented with right side parotid swelling. Preoperative imaging with computerized tomography scan was done which showed encapsulated swelling with few cystic areas and fine-needle aspiration cytology confirmed benign parotid lesion with cluster of epithelial cells. Right-sided superficial parotidectomy sparing facial nerve with complete removal of tumor was done.

## RESULTS

Postoperative recovery was uneventful. Histopathology confirmed benign lesion as oncocytoma with abundant granular acidophilic cytoplasm. Owing to benign nature, no adjuvant therapy was given. Patient is on 2 years disease-free follow-up.

## CONCLUSION

Oncocytoma, a rare entity that misleads like a pleomorphic adenoma should be considered in clinical differential diagnosis and surgical management.

Due to the lack of large series, laborious study of the cases reported in the literature may lead to better understanding of this rare disease.

---

## A Case of an Acrometastasis from Breast Cancer

<sup>1</sup>Ryoko Ono, <sup>2</sup>Daijiro Kagawa, <sup>3</sup>Takao Miyaguni

<sup>1-3</sup>Naha City Hospital, Naha Okinawa, Japan

## CASE REPORT

We report a rare case of breast cancer with an acrometastasis—bone metastasis to the hand or feet. A 62-year-old-woman noticed a mass in her right breast and visited our hospital. Mammography and breast ultrasonography showed a 1.5 cm tumor in her right breast. A needle biopsy was performed and invasive ductal carcinoma (ER 90%, PgR 10%, Her2 score 3+, Ki67 40%) was suspected. Sternal bone metastasis appeared on bone scintigraphy and sternal magnetic resonance imaging (MRI). After tumor-ectomy, radiation therapy to the right breast and sternum was performed and hormonal therapy was continued. Right ankle pain appeared 2 years after surgery. At first it was suspected of trauma or joint degeneration, but no improvement in symptoms was observed. The MRI imaging showed an 8 mm nodule at the distal end of the tibia. An acrometastasis of breast cancer was suspected. Radiation therapy to the right foot joint is performed, and drug therapy is ongoing.

## Duodenal Injury presenting as Fournier's Gangrene: A Case Report

<sup>1</sup>Tuhin Shah, <sup>2</sup>Rakesh K Gupta, <sup>3</sup>Birkha R Joshi, <sup>4</sup>Abhijeet Kumar, <sup>5</sup>Chandra S Agarwal

<sup>1-5</sup>Asia Pacific Medical College, Birgunj, Nepal

### INTRODUCTION

Blunt duodenal injury is uncommon and associated with significant morbidity (30–60%) and mortality (6–25%). The evidence of an isolated traumatic duodenal lesion is rare. On average, one to four other abdominal organ injuries are associated with duodenal trauma.

### CASE REPORT

A 70-year-old man presented to the emergency 10 days after fall injury, with pain and swelling in right inguinal region and scrotum. On examination, vital signs were normal; scrotal erythema, edema, and crepitus were present with absent peritoneal signs. White blood cell count was  $9,100/\text{mm}^3$  with 87% neutrophils. Plain thoracoabdominal radiographs were normal without free gas under diaphragm. Ultrasound showed thickened and inflamed scrotal wall extending to lower abdominal wall with air pockets within. No collection in abdomen. A preoperative diagnosis of Fournier's gangrene was made. Wound debridement under general anesthesia was done. As some bilious content was seen in right inguinal region, exploratory laparotomy was performed. Perforation in third part of duodenum, more than 50% circumference with bilious collection in retroperitoneal space tracking down to right iliac fossa and groin. Duodenorrhaphy was done in two layers with 3-0 polyglactin and silk sutures. A nasogastric tube, reverse tube duodenostomy through proximal jejunum, and feeding jejunostomy with closed abdominal drain in right para-colic gutter.

### CONCLUSION

High suspicion is necessary for early diagnosis of duodenal trauma and CT scan should be performed. In most cases, primary repair of duodenum can be achieved with duodenal decompression via triple tube technique to decrease the risk of duodenal fistula though we did duodenal decompression with double tube and nasogastric tube drain with good results.