

Poster Presentation on Adrenal, Pituitary, and Other Endocrine Glands, Parathyroid Gland, Thyroid Gland

A Case of Pancreatic Gastrinoma with Multiple Liver Metastases treated by Induction Drug Therapy and Surgical Resection

¹Hideaki Oe, ²Ryuichiro Doi

^{1,2}Department of Surgery, Otsu Red Cross Hospital, Shiga Prefecture, Japan

BACKGROUND AND AIMS

Gastrointestinal and pancreatic neuroendocrine tumors (NET) are classified as low grade (G1), intermediate grade (G2), and high grade (G3) by mitotic rate and/or Ki-67 index. The basic treatment for neuroendocrine carcinoma (NEC, G3) with remote metastasis is platinum-based systemic chemotherapy. In contrast, for patients with NET G1 or G2 with remote metastasis, multidisciplinary treatment is necessary in order to prolong patients' survival and relieve symptoms. We report here a patient with pancreatic G1 gastrinoma and its multiple liver metastases.

METHODS

The patient was a 42 years old male who had been suffering from diarrhea for 2 years, and his serum level of gastrin was as high as 4200 pg/mL before treatment. Needle biopsy of the liver proved the tumor was positive for chromogranin A, gastrin, and somatostatin receptor type 2A.

RESULTS

First, we chose an induction drug therapy with sunitinib and octreotide. The size of the liver tumors decreased dramatically and the serum gastrin level became lower than 500 pg/mL. About 1 year after diagnosis, we performed distal pancreatectomy and right hepatic lobectomy. After surgery, the serum gastrin level was normalized, and the activity of daily living (ADL) of the patient was much improved by the consecutive therapies. During the 2-year postoperative follow-up time, the course was favorable and no recurrent lesion was found.

CONCLUSION

Even when there are remote metastases, multidisciplinary treatment including surgical resection should be considered for G1/G2 NET. Further, it should be necessary to study in a larger number of patients if perioperative drug therapy for G1/G2 NET with remote metastases is effective.

Case Report of Laparoscopic Adrenalectomy for Large (≥ 6 cm) Adrenal Masses

¹Shin-young Park, ²Young Up Cho, ³Sei Joong Kim

¹⁻³Department of Surgery, Inha University Hospital, Incheon, South Korea

BACKGROUND AND AIMS

Laparoscopic adrenalectomy has become the procedure of choice for small and benign adrenal lesions. Recently, many surgeons have expanded the range of indications for laparoscopic adrenalectomy, and this approach is used for large adrenal lesions. Our aim is to evaluate the outcome of laparoscopic adrenalectomy for large (≥ 6 cm) adrenal masses.

METHODS

We retrospectively reviewed four patients, who underwent laparoscopic adrenalectomy for a large (≥ 6 cm) adrenal mass at our institute from January 2010 to December 2015.

RESULTS

Among these four cases, three were performed by transperitoneal approach and one was performed by retroperitoneal approach. There was no conversion to open adrenalectomy. The median operation time was 162.5 minutes (95–295 minutes) and the median postoperative hospital stay was 8 days (6–13 days). There was no postoperative morbidity. Pathologic diagnoses of the four cases were adrenal cortical carcinoma (7 cm), simple cyst (7.8 cm), ganglioneuroblastoma (10 cm), and pheochromocytoma (8.5 cm).

CONCLUSION

Laparoscopic adrenalectomy for large adrenal masses is technically feasible and safe.

A Novel *de novo* Germline Mutation of MEN1 Gene in a Young-aged Multiple Insulinoma with Hyperparathyroidism

¹Youn Joon Park, ²Jun Won Min, ³Eui Tae Kim, ⁴Myung-chul Chang

¹⁻⁴Department of Surgery, Dankook University Hospital, Chung Nam Province, South Korea

BACKGROUND AND AIMS

Multiple endocrine neoplasia type 1 is an autosomal-dominant disease caused by the MEN1 germline mutation. We performed a genetic study of young-aged patient with multiple insulinoma with hyperparathyroidism and summarized the clinical history of that patient.

METHODS

A 25-year-old man was admitted for loss of consciousness. Initial laboratory data showed hypoglycemia and hypercalcemia. In the image study, there were two insulinoma in pancreas head and body. The MIBI scan was positive in the left lower parathyroid gland. There was no evidence of pituitary tumor. After diagnosis of insulinoma and hyperparathyroidism, we suspected MEN1, but there was no family history of endocrine disease. We enucleated the insulinoma in the pancreatic head and body. After operation, the blood sugar level was normalized and no hypoglycemic symptom appeared. We tested germline mutations of the MEN1 gene by direct DNA sequence analysis after obtaining the informed consent.

RESULTS

In the genetic study, a frameshift mutation was found in exon 2, which deleted 16 nucleic acids (c.326_341del16) and resulted in a truncation at codon 113. This mutation was not reported previously.

CONCLUSION

We found novel and *de novo* mutation of the MEN1 gene. The genetic study is necessary in case of young-age, multiple endocrine tumors.

A Systemic Review of Rare Adrenal Schwannoma

¹Soo-Young Kim, ²Yong Sang Lee, ³Seok-Mo Kim, ⁴Hojin Chang, ⁵Bup-Woo Kim, ⁶Hang-Seok Chang, ⁷Cheong Soo Park

¹⁻⁷Department of Surgery, Gangnam Severance Hospital, Yonsei University College of Medicine, Seoul, South Korea

BACKGROUND AND AIMS

Adrenal schwannomas are very rare and are usually incidentally found on autopsy and imaging. The aim of this study was to describe our experience of adrenal schwannoma and review the literature reporting this rare tumor.

METHODS

To identify patients with adrenal schwannoma, the MEDLINE database was searched via the major electronic database PubMed using the medical subject heading terms "adrenal" and "schwannoma." The result showed a total of 39 adrenal schwannomas cases including two from our institution.

RESULTS

The mean age at diagnosis was 47.95 years (11–89 years). The female:male ratio was 21:17. Tumors were located on the right or left sides in 16 and 19 patients respectively, while 1 patient had bilateral tumors. The mean tumor size was 6.12 cm (0.6–14.5 cm), and the mean tumor weight was 161.3 gm (31.5–600.0 gm). Sixteen tumors were solid, 4 cystic, 1 solid and cystic, and 18 were not described. Histologically, 14 cases were Antoni A, 2 were Antoni B, and 12 had concomitant Antoni A and B.

CONCLUSION

Adrenal schwannoma is usually an incidental finding, and the clinician must have a high index of suspicion to recognize it when imaging reveals suggestive features.

Tumor Size and Hounsfield Unit Density as a Tool in Risk Stratification of Patients with Adrenal Incidentaloma

¹MA Saiyidah Adila, ²K Normayah, ³B Anita, ⁴B Sarinah, ⁵M Norhisham, ⁶O Fatimah

¹Department of Surgery, National Cancer Institute, Putrajaya, Malaysia

²⁻⁵Department of Surgery, Putrajaya Hospital, Putrajaya, Malaysia

⁶Department of Radiology, Hospital Putrajaya, Putrajaya, Malaysia

BACKGROUND AND AIMS

Nonfunctioning adrenal incidentaloma (AI) is a surgical dilemma with regard to the decision for surgery or nonsurgical management. There are no specific clinical or radiological features to differentiate benign or malignant adrenal mass. Therefore, the majority of benign nonfunctioning AI patients underwent diagnostic adrenalectomy. In order to avoid this, a good risk stratification model is important as a tool to assist the surgeon to make a decision. The aim of our study is to apply the risk stratification model from the Cleveland Study in all AI patients using tumor size and Hounsfield unit (HU) density in noncontrast CT to predict the adrenal pathology.

METHODS

The study was conducted from January 2010 until December 2014 at Hospital Putrajaya. All patients with AI who had adrenalectomy were included in this study. The risk stratification model from the Cleveland Study was used. By assigning points for adrenal size (1, 2, or 3 for tumors <4, 4–6, or >6 cm respectively) and HU density on noncontrast CT (1, 2, or 3 points for HU <10, 10–20, or >20 respectively) the total score and histopathology report were analyzed.

RESULTS

There were 181 patients with adrenalectomy. Thirty-three patients (18%) were identified as AI, but noncontrast CT was retrievable only in 13 patients. All were hormonally inactive. The median age group comprised 44-year-olds (23–66 years). There was one patient (8%) with a score of 2–3, 2 (16%) patients with a score of 4, and 11 (76%) patients with a score of 5–6. All patients with score 2–3 and 4 had benign tumors. There were two patients (18%) with malignant tumour with a score of 5–6.

CONCLUSION

In conclusion, the risk stratification model from the Cleveland Study using adrenal size and HU density is a reliable indicator in predicting malignancy. It helps to spare a substantial number of patients from unnecessary diagnostic adrenalectomy.

Case Report: A Rare Case of Pure Androgen-secreting Adrenal Tumor

¹Nor Safariny Ahmad, ²Hussain Mohamad, ³Siti Hartinie Muhammad

¹⁻³Department of Surgery, Hospital Sultanah Nur Zahirah, Kuala Terengganu, Terengganu, Malaysia

BACKGROUND AND AIMS

Pure androgen-secreting adrenal tumor (PASAT) is a rare disease (1.4–15%), almost uniquely found in females and usually presented with hirsutism, virilization, and disruption of the menstrual cycle.

METHODS

We report a case of an uncommon PASAT. A 49-year-old Malay lady presented to us with a 4-year history of hirsutism, virilization (clitoromegaly), and menstrual irregularity. Physical examination showed the lady had features of hirsutism and clitoromegaly. Blood investigation revealed high testosterone level: 16.9 nmol/L (0.7–2.8 nmol/L) and her DHEAS (dehydroepiandrosterone) was 78. Her ACTH level was <1 pmol/L (normal <11) and the overnight dexamethasone suppression test was normal (serum cortisol: 12.5 nmol/L). She had normal urinary catecholamine. Computed tomography (CT) of the abdomen and pelvic was performed to distinguish between an ovarian and an adrenal tumor as the cause of virilization. Her CT scan showed left adrenal mass, size 2 (AP) × 1.9 (W) × 2.3 (CC) cm. She underwent left posterior retroperitoneoscopic adrenalectomy, and histopathological examination revealed a 4 cm adrenal adenoma with Weiss score 0, which is suggestive of benign tumor. Her symptoms of hirsutism, virilization, and irregular menses improved after 6 months.

RESULTS

Pure androgen-secreting adrenal tumor is an adrenal tumor that exclusively secretes androgens without excess cortisol. It is an extraordinarily rare disease and characteristically present with a combination of hirsutism, virilization, and menstrual irregularity as presented by this patient. Fifty percent of PASATs are malignant; a CT scan may suggest whether the tumor is benign or malignant. Adrenalectomy is indicated in all cases of resectable PASAT, because the diagnosis of benign or malignant can be

differentiated only by a pathologic examination. Adrenalectomy is the treatment of choice, as it can normalize the hormone level and resolve the end-organ effect.

CONCLUSION

The diagnosis of PASAT required a careful history and a thorough physical examination. All suspected cases should be referred to the endocrinology center due to the complexity of investigation. It is important to identify this group because 50% of PASATs are malignant.

The Impact of Body Mass Index on Perioperative Outcomes of Robotic Adrenalectomy

¹Melis Akbas, ²Ozer Makay, ³Ilgin Yildirim Simsir

^{1,2}Department of General Surgery, Ege University Faculty of Medicine, Izmir, Turkey

³Department of Internal Medicine, Division of Endocrinology and Metabolism, Ege University Faculty of Medicine, Izmir, Turkey

BACKGROUND AND AIMS

Obesity is a major comorbidity and influences outcomes of patient care. Robotic surgery, which is a minimally invasive approach, has been increasing in popularity. Although reports regarding impact of body habitus on robotic surgery is known, very little is known about the impact of obesity on the clinical outcomes of patients undergoing robotic adrenalectomy. In this study we evaluated the impact of body mass index (BMI) on perioperative outcomes in patients who underwent robotic adrenal surgery.

METHODS

Forty-seven consecutive patients underwent robotic adrenalectomy from May 2012 to December 2014. Patients were divided into two groups based on their BMI: non-obese (<30 kg/m²) and obese (≥ 30 kg/m²). Besides demographics, Charlson Comorbidity Index (CCI) scores, American Society of Anaesthesiologists' (ASA) scores, tumor size, total operative time, docking time, console time, estimated blood loss, conversions, intraoperative complications, additional analgesia requirements, length of stay, and costs were evaluated.

RESULTS

Of the 47 patients, 33 (70.2%) were non-obese and 14 (29.8%) were obese. Groups were similar in terms of age, gender, CCI, and ASA scores and the history of previous abdominal surgery. There was no statistically significant difference in the total operative time (p=0.270), docking time (p=0.154), console time (p=0.175), blood loss (p=0.990), intraoperative complications (p=0.91), length of stay (p=0.309), and approximate cost (p=0.548). Three cases were converted to open surgery. Non-obese cases requested more additional analgesia (p=0.007). We had no unexpected hospitalizations in both groups.

CONCLUSION

This study does not confirm previous findings concerning the advantages of robotic surgery in the obese. No significant clinical differences between groups, except more additional analgesia requirement in the non-obese cases, were found.

Spontaneous Adrenal Hemorrhage: Variation is the Rule – Case Series of Six Patients in 1 Year

¹Pooja Ramakant, ²S Suganya, ³Siddhartha N Chakravarthy, ⁴Anish J Cherian, ⁵Deepak T Abraham, ⁶MJ Paul

¹⁻⁶Department of Endocrine Surgery, Christian Medical College, Vellore, Tamil Nadu, India

BACKGROUND AND AIMS

Patients with spontaneous adrenal hemorrhage with or without tumors usually present as an emergency. There are various options available for managing such lesions ranging from conservative management, embolization, to surgery (emergency/elective). However, there is no definitive management guideline, and we need to decide the appropriate management option that may be tailor-made for each patient.

This study aims to analyze our series of patients presenting with spontaneous adrenal hemorrhage due to rupture and to assess their clinicopathological profile and outcomes of their management options.

METHODS

Data of patients with spontaneous adrenal hemorrhage presenting during January to November 2015 were analyzed retrospectively using the institutional computerized hospital information-processing service. All clinical, biochemical, radiological, pathological, operative, and follow-up details were recorded.

RESULTS

There were a total of six patients with ruptured adrenal lesions during this 1-year period. All patient details are described in Table 1. Patients usually presented in 3rd/4th decade of their life and only one patient in presented in the 6th decade; the male-to-female ratio was 4:2. All patients presented with severe abdominal pain and four had uncontrolled HTN on medicines. Computed tomography scan/MRI accurately detected hemorrhage. Figure 1 includes radiological and specimen picture of adrenal hemorrhage. Management options included conservative (n=3), embolization followed by emergency surgery (n=1), and emergency surgery (n=2). The histologies were pheochromocytoma (n=1), myelolipoma (n=1), and no tumor (n=3). There was no perioperative mortality.

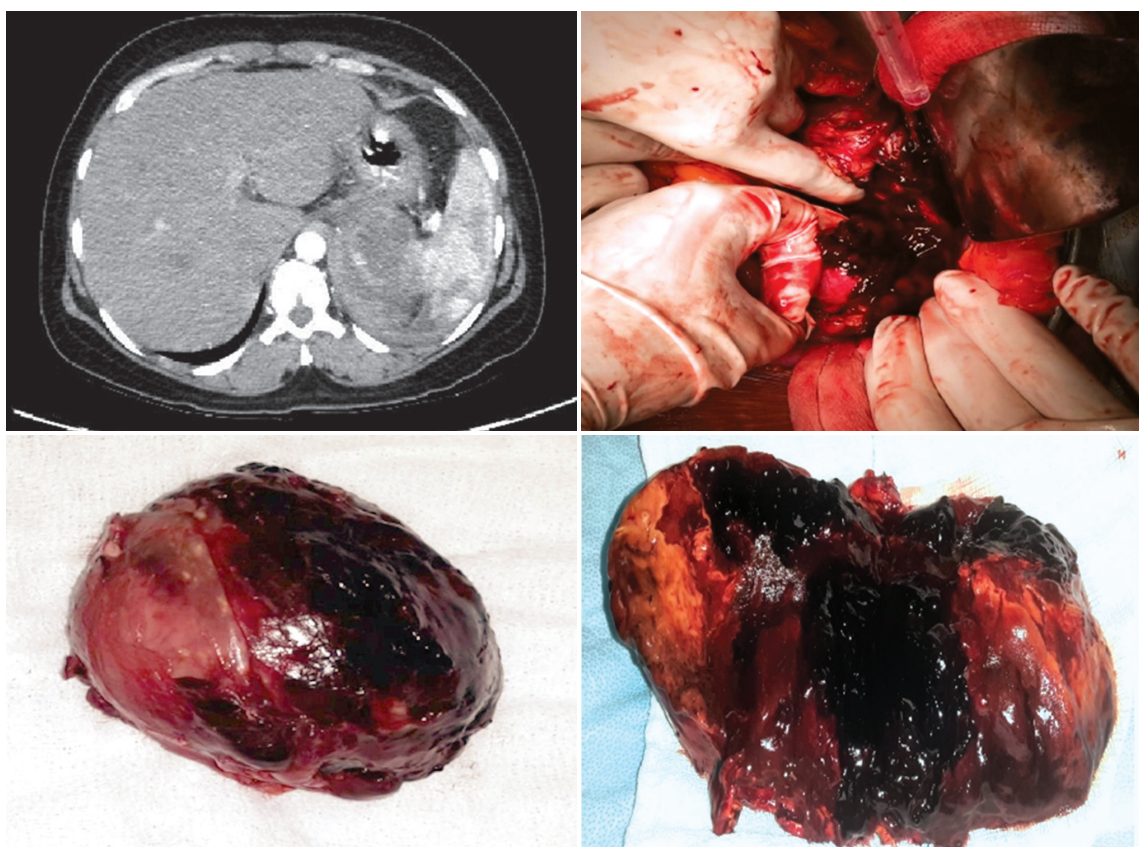


Fig. 1: Radiological and specimen images of adrenal hemorrhage

CONCLUSION

Patients with spontaneous adrenal hemorrhage present with severe abdominal pain with uncontrolled HTN and usually present as an emergency. Nonfunctional /functional adrenal lesions are equally prone to rupture. Emergency surgery is a safe option for those who do not respond to conservative management.

Table 1: History and treatment of examined patients

<i>Patient number, age, gender</i>	<i>Presentation mode</i>	<i>Biochemical (functional/nonfunctional)</i>	<i>Radiological</i>	<i>Treatment option</i>	<i>Follow-up in months and outcome</i>
Patient 1 36 years/ female	Abdominal pain, vomiting, headache for 6 days. HTN+ Hemoglobin dropped from 9 to 6 g/dl with hypotension. Hence, planned emergency surgery without alpha blockade.	Elevated urinary normetanephrines Pheochromocytoma	8 cm left adrenal mass with rupture and hemorrhage confined to perinephric space	Emergency open transperitoneal left adrenalectomy	8 month followup Alive and healthy

<i>Patient number, age, gender</i>	<i>Presentation mode</i>	<i>Biochemical (functional/nonfunctional)</i>	<i>Radiological</i>	<i>Treatment option</i>	<i>Follow-up in months and outcome</i>
Patient 2 32 years/ female	36+ weeks' gestation with right hypochondrium pain and vomiting for 4 days Normotensive	Nonfunctional	3.2 cm right adrenal lesion with rupture	Conservative for adrenal hemorrhage Emergency LSCS	8-month follow-up Hematoma reduced to 1.2 cm Alive and healthy
Patient 3 64 years/ male	Right hypochondrium severe abdominal pain after fall from height HTN+	Nonfunctional No tumor	2.4 cm right adrenal bleed	Conservative	7 months' hematoma resolved Alive and healthy
Patient 4 36 years/ male	Right hypochondrium severe pain for 10 days Fall in Hb needing blood transfusions Normotensive	Nonfunctional myelolipoma	12 cm right adrenal myelolipoma with bleed confined to perinephric space	Emergency laparoscopic converted to open transperitoneal right adrenalectomy	5-month follow-up alive and healthy
Patient 5 40 years/ female	Left hypochondrium severe sudden pain while lifting heavy object HTN+	Nonfunctional left adrenal tumor with bleed	4.6 cm left adrenal lesion with perinephric bleed	Conservative then planned for elective surgery laparoscopically	1-month follow-up resolving hematoma Planned for elective surgery
Patient 6 40 years/ male	Severe abdominal pain, distension and vomiting for 1 day Dyspnoea+ptosis right eye – syncopal attack HTN uncontrolled	Biochemical workup not done preoperative as patient came in critical state needed emergency management Nonfunctional in postoperative workup	13.5 cm left retroperitoneum bleed Left adrenal gland not visualized separately	Emergency embolization of vessels from phrenic artery supplying the lesion and some retroperitoneal vessels – went in HTN crisis Underwent open transperitoneal left adrenalectomy	Histology no tumor, only infarcted adrenal tissue with hemorrhage 3-week follow-up doing well

MIBG Scan in Pheochromocytoma/Paraganglioma

¹Ra-Yeong Song, ²Jin Wook Yi, ³Hyeong Won Yu, ⁴Joon-Hyop Lee, ⁵Jun Woo Jung, ⁶Hyungju Kwon
⁷Su-Jin Kim, ⁸Young Jun Chai, ⁹June Young Choi, ¹⁰Kyu Eun Lee

^{1-3,6,7,10}Department of Surgery, Seoul National University Hospital, Seoul, Korea

^{4,5,9}Department of Surgery, Seoul National University Bundang Hospital, Seoul, Korea

⁸Department of Surgery, Seoul National University Boramae Hospital, Seoul, Korea

BACKGROUND AND AIMS

I-123 MIBG scintigraphy is the most commonly used imaging modality for the diagnostic localization of pheochromocytomas and paragangliomas, with a sensitivity ranging from 80 to 100%. It is comparable with other nuclear imaging studies in detecting primary, sporadic, and non-metastatic PGL. However, lower sensitivities have been reported in the detection of extra-adrenal, small, familial tumors. The purpose of this study was to identify the characteristics of PPGL with false negative I-123 MIBG scintigraphy.

METHODS

Sixty-nine patients (36 males, 33 females) who had undergone preoperative I-123 or I-131 MIBG scintigraphy with or without SPECT/CT between January 2000 and January 2015 were included in the study. The mean age was 48.2 ± 14.2 years (20–78 years). A total of 69 tumors were finally analyzed, since five patients had undergone bilateral adrenalectomy. Biochemical results, imaging and pathologic findings, and genetic mutations were reviewed.

RESULTS

Twenty-six patients had MIBG scintigraphy results only, and 20 patients had undergone I-131 MIBG scan. Contrast-enhanced CT was performed on 67 patients, and MRI was performed on 35 patients. Three patients were diagnosed with von Hippel-Lindau (VHL) syndrome. SDHD mutation was present in four cases, RET mutation in three cases, and the rest were apparently sporadic. Final pathology revealed 65 PPGL (48 pheochromocytoma, 17 paraganglioma), 2 adrenocortical adenomas, and 7 other tumors. The sensitivity of I-123/131 MIBG scintigraphy for PPGL was 83.1%, with a specificity of 55.6%. Eleven (16.9%) PPGL were negative in MIBG scintigraphy. Patients with MIBG-negative PPGL were younger (38.6 ± 12.7 vs 50.0 ± 14.6 years, $p = 0.018$) and tumors were mostly grossly cystic (81.8 vs 20.4% , $p < 0.001$).

CONCLUSION

Younger age and cystic nature may result in a false-negative MIBG scintigraphy.

Clinical Analysis of 30 Patients with Parathyroid Cysts

¹You Pei Ren, ²Jia Liu, ³Guang Chen

¹⁻³Department of Thyroid Surgery, Jilin University, Changchun, Jilin, China

BACKGROUND AND AIMS

To investigate the clinical characteristic, diagnosis, surgical treatment, and prognosis of parathyroid cysts.

METHODS

Thirty cases of parathyroid cysts who had an operation at First Hospital of Jilin University during May 2008 to May 2015 were retrospectively analyzed. The clinical characteristic, diagnosis, surgical treatment, and prognosis were analyzed emphatically.

RESULTS

All patients were diagnosed with parathyroid cysts by postoperative pathology. The mean age of patients was 46.9 years old, and the male-to-female ratio was 1:5. The mean diameter of the cysts was 2.65 cm and the incidence of cyst in the left lobe was double that in the right lobe. Twenty-one cases were diagnosed with parathyroid cysts by ultrasound scan and three cases had elevated levels of parathyroid hormone. All the cases underwent surgical ablation of the cysts without recurrence at 2 months to 6 years of follow-up, and some cases were with surgical excision of the thyroid.

CONCLUSION

Ultrasound scan has important value for the preoperative diagnosis of parathyroid cysts. Surgical resection including minimally invasive surgery is effective in treating parathyroid cysts, and the nonfunctional parathyroid cyst does not easily lapse after resection.

The Benefits of Successful Parathyroidectomy in Patients with Primary Hyperparathyroidism in Sabah

¹Sanjeev Sandrasekar, ²Harinthiran Vijeyan, ³Siti Zubaidah Sharif

¹⁻³Department of Surgery, Queen Elizabeth Hospital, Kota Kinabalu, Sabah, Malaysia

BACKGROUND AND AIMS

To evaluate the effectiveness of parathyroidectomy in patients with primary hyperparathyroidism.

METHODS

Patients who were diagnosed with primary hyperparathyroidism and subjected to parathyroidectomy were identified and their medical records collected. Data on clinical symptoms and laboratory results (serum calcium, ALP, iPTH) were obtained. Parameters were compared between pre- and post-operation, including clinic follow-up. The difference in promotions was assessed with the chi-square test and the difference in mean was assessed with the Student's t-test.

RESULTS

Post-parathyroidectomy patients have significant improvement symptomatically and biochemically. They have improved bonny pain with decrease in serum calcium and phosphates and increase in phosphorus.

CONCLUSION

Parathyroidectomy for patients with primary hyperparathyroidism directly improves the clinical manifestation of hyperparathyroidism and thus improves the quality of life.

Refractory Severe Hypercalcemia Secondary to Atypical Parathyroid Adenoma: A Surgical Challenge

¹MN Fatin, ²RA Rafilis, ³MW Wong, ⁴NA Hakim, ⁵EN Aina

¹⁻⁵Department of Breast and Endocrine Surgery, Hospital Kuala Lumpur, Kuala Lumpur, Malaysia

BACKGROUND AND AIMS

Severe hypercalcemia secondary atypical parathyroid adenoma is rare and poses a surgical challenge. We report a case of severe refractory hypercalcemia secondary to atypical parathyroid adenoma that was successfully treated with parathyroidectomy under local anesthesia.

METHODS

A 50-year-old lady presented with hypercalcemic symptoms since 1 year. Her neck examination revealed a 3 cm hard lump located at the lower right neck region. Laboratory findings were serum calcium of 3.6 mmol/L and iPTH of 98.4 pg/mL. Ultrasound showed a 3.5 × 4.6 × 4.1 cm heterogeneous mass at the lower right neck adhering to the right thyroid lobe.

She was treated with saline diuresis, calcitonin, and bisphosphonate for 3 days along with two cycles of hemodialysis without any clinical and biochemical improvement. We proceeded with neck exploration under local anesthesia and found an enlarged right inferior parathyroid gland measuring 4 × 4 cm densely adherent to the right thyroid lobe. Right hemi-thyroidectomy with parathyroidectomy was successfully performed. The histopathological examination showed an encapsulated parathyroid gland consisting of neoplastic chief cells arranged in a diffuse pattern with numerous congested vascular channels and thickened fibrous connective tissue stroma. The final report was atypical parathyroid adenoma.

RESULTS

Atypical parathyroid adenomas can be described as tumors composed of chief cells arranged in a trabecular pattern with the presence of fibrotic bands, high mitotic activity of more than 1/10 per high-power field, and dense adhesion to the adjacent structures. However, there are lacks of capsular, vascular, or perineural invasions as seen in parathyroid carcinoma.

Various medical therapies including hemodialysis are used as the initial modality to treat the hypercalcemia before proceeding to a definitive surgical intervention. However, in cases of refractory hypercalcemia, surgical intervention under local anesthesia is the only mode of treatment.

CONCLUSION

Parathyroidectomy under local anesthesia can be safely performed in cases with severe refractory hypercalcemia secondary to atypical parathyroid adenoma.

Challenges in Diagnosing and Managing Parathyroid Carcinoma in Putrajaya Hospital

¹Suraya Baharudin, ²KC Hiew, ³Sarinah Basro, ⁴Anita Baghawi, ⁵Norhisham Muda, ⁶Normayah Kitan

¹⁻⁶Breast and Endocrine Unit, Putrajaya Hospital, Putrajaya, Malaysia

BACKGROUND AND AIMS

Diagnosing parathyroid carcinoma can be a challenge as it is based only on clinical suspicion as evidenced by lymph node involvement and the possibility of infiltration in the surrounding structures and distant metastasis either by radiological imaging or by intraoperative findings. Higher serum calcium and larger gland may lead to clinical suspicion of carcinoma.

METHODS

This retrospective study reports 11 cases of parathyroid carcinoma managed in Putrajaya Hospital from 2006 till October 2015.

RESULTS

All cases presented with symptomatic hypercalcemia with the mean highest serum calcium level of 3.5 μmol and serum iPTH level of 485 pmol/L. The right parathyroid gland (55%) was the most commonly affected as compared to the left, and the superior gland was the most dominant. The mean tumor size was 3 cm. Nine cases were diagnosed after primary surgery and two cases were diagnosed after second surgery as the primary surgery revealed a parathyroid adenoma with no clinical suspicion of carcinoma. Five cases had recurrence at similar site and/or ipsilateral central and lateral compartment lymph nodes, which requires multiple surgeries (two to four times). The duration between recurrences range from 1 to 3 years. Two cases had recurrent laryngeal nerve involvement that was sacrificed during the first surgery. Four cases were suspected to have esophageal involvement

intraoperatively. Bone metastasis was suspected by radiological imaging in four cases. Lung and liver metastasis was seen in one case each. Two cases had a previous history of prostate cancer and breast cancer. Only two cases had undergone radiotherapy treatment to the neck. One case died due to postoperative complication with esophageal perforation and carotid artery blowout. Three cases died due to disease progression.

CONCLUSION

Clinicians should have a high index of suspicion in diagnosing parathyroid carcinoma, as early diagnosis and appropriate treatment would improve the outcome.

Intrathyroidal Parathyroid Glands – A Cause for Failed Parathyroid Surgery?

¹Kah Seng Khoo, ²Jack Pein Cheong, ³Siew Yep Hoh, ⁴Shun Siang Chong, ⁵Khoon Leong Ng

¹⁻⁵Department of Surgery, Faculty of Medicine, University of Malaya, Kuala Lumpur, Malaysia

BACKGROUND AND AIMS

An Intrathyroidal parathyroid gland (ITPG) is a rare entity. It is typically located at the superior position and by definition is a parathyroid gland completely surrounded by thyroid parenchyma. The reported incidence is approximately 1 to 2%. Although rare, ITPGs are of surgical import because they are considered to be one of the reasons for failed parathyroid surgery. In this case series, we report three cases of ITPG in patients with chronic kidney disease (CKD) requiring total parathyroidectomy for tertiary hyperparathyroidism. In all the cases, three parathyroid (PT) glands were found at initial surgery but the 4th gland remained elusive. Subsequent investigations and reexploration yielded the remnant PT gland in the intrathyroidal position. The diagnosis of ITPG may be considered when one PT gland is not found during initial surgery but subsequent imaging and 99m-Tc sestamibi studies indicate the presence of a persistent PT gland. If re-operation fails to locate the remnant gland, the diagnosis of an ITPG may be considered. A thyroid lobectomy may then be warranted on the side of the sestamibi uptake. This focused approach may be more justifiable than an empirical thyroid lobectomy at the initial surgery when the PT gland is not found.

METHODS

Case series (Fig. 1).

CONCLUSION

Intrathyroidal parathyroid gland may not be as rare as previously thought. The possibility of an ITPG should be considered if the parathyroid glands are not found during surgical exploration and when the sestamibi scans shows positive uptake. In such cases, although not a standard procedure, a thyroid lobectomy may be considered on the side of the positive Tc-99m MIBI uptake.

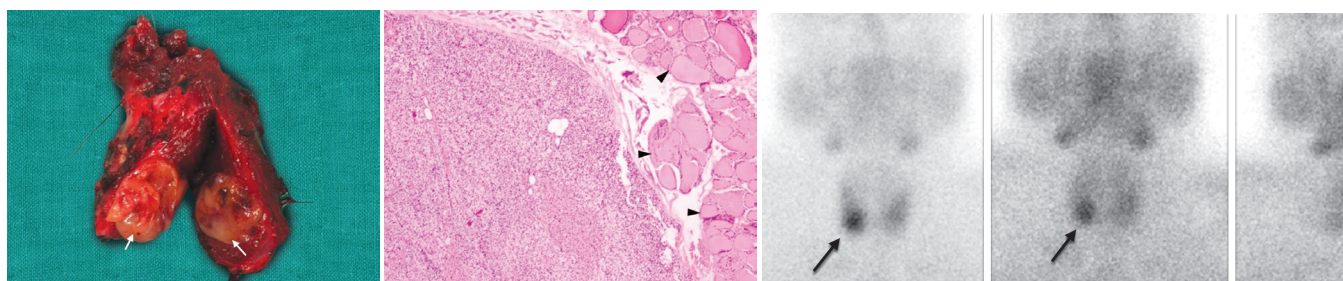


Fig. 1: Suspected parathyroid adenoma high in the left carotid sheath at preoperative assessment (arrow, A), though formal radiology report suggests left inferior adenoma. Intraoperative exploration revealed a fusiform swelling of the left vagus nerve at the level of the carotid bifurcation. The perineurium was incised revealing a small mass consistent with parathyroid tissue on frozen section (arrow, C). Of note no other parathyroid tissue was found in the left neck including the thymus or in any other part of the operative field (B, including gray shaded area)

Four-dimensional Computed Tomography: Its Diagnostic Value and Clinical Impact for Patients with Primary Hyperparathyroidism

¹Yuan Tian, ²Sharman Tan Tanny, ³Genevieve Flannery, ⁴Meir Lichtenstein, ⁵Damien Stella, ⁶Pramit Phal, ^{7,8}Julie A Miller

^{1,2,7}Endocrine Surgery Unit, Royal Melbourne Hospital, Parkville, Victoria, Australia

^{3,4}Department of Nuclear Medicine, Royal Melbourne Hospital, Parkville, Victoria, Australia

^{5,6}Department of Radiology, Royal Melbourne Hospital, Parkville, Victoria, Australia

⁸Department of Surgery, University of Melbourne, Parkville, Victoria, Australia

BACKGROUND AND AIMS

In recent years, four-dimensional computed tomography (4DCT) has emerged as a new localization study for primary hyperparathyroidism (pHPT), providing detailed localization of parathyroid adenoma(s). We recently introduced 4DCT to our imaging armamentarium in a tertiary academic endocrine surgery unit. We aimed to assess the added value of 4DCT in our institution.

METHODS

A retrospective cohort study was conducted, collecting data from 536 consecutive parathyroidectomies performed for pHPT in 510 patients from February 2004 to June 2015. Cure was defined as normocalcemia 6 months following surgery. Since we began using 4DCT in 2011, 100 patients with negative, discordant, or equivocal findings on sestamibi and ultrasound (US) have undergone 4DCT.

RESULTS

Of the 536 parathyroidectomies (78.2% female, mean age 62 years), 384 were minimally invasive parathyroidectomies (MIPs), 107 bilateral neck explorations (BNEs), and 45 re-operative cases (17 MIPs and 28 BNEs). The overall cure rate was 94.7%. Within the cohort, the sensitivity and positive predictive value (PPV) for sestamibi were 76.0 and 93.1% respectively and for US 74.8 and 92.9% respectively.

In 100 patients with equivocal or discordant findings on sestamibi (sensitivity 48.3%) and US (52.3%), 4DCT had a much higher sensitivity of 72.9%. This resulted in 31 cases (up to 41.3%) successfully undergoing MIP instead of BNE. Subgroup analyses were performed. The strength of 4DCT was highlighted in patients with persistent or recurrent HPT, with sensitivity of 4DCT being 60.0% compared to 43.8% of sestamibi and 36.4% of US. Patients with multigland disease (MGD) also benefited from the higher accuracy of 4DCT (sensitivity 67.4%), with six cases (up to 40.0%) avoiding an additional operation because 4DCT detected a bilateral disease that was not appreciated on sestamibi.

CONCLUSION

Four-dimensional computed tomography is useful for parathyroid adenoma (PTA) localization, especially in persistent or recurrent HPT and patients with MGD.

Ectopic Intravagal Parathyroid Adenoma

¹Jurstone Daruwalla, ²Nirupa Sachithanandan, ³David Andrews, ⁴Julie Miller

¹Department of Surgery, Austin Health, University of Melbourne, Parkville, Victoria, Australia

²Department of Endocrinology, St Vincent's Hospital, Fitzroy, Victoria, Australia

³Department of Anesthesia and Pain Management, Royal Melbourne Hospital, Parkville, Victoria, Australia

⁴Endocrine Surgery Unit, Royal Melbourne Hospital, Parkville; Victoria, Australia and Epworth Freemasons Hospital, East Melbourne, Victoria, Australia

BACKGROUND AND AIMS

Intraneural parathyroid adenomas are rare, with only nine cases of intravagal adenomas reported. All but one of the reported cases was found following multiple neck explorations. We report the first case of non-supernumerary ectopic intravagal parathyroid identified at primary exploration (Table 1).

METHODS

A 17-year-old girl with primary hyperparathyroidism and nephrolithiasis was referred with a sestamibi scan reporting a left lower parathyroid adenoma.

RESULTS

No eutopic parathyroid tissue was identified during full exploration of the left neck. Exploration of the carotid sheath revealed a fusiform swelling of the vagus nerve at the carotid bifurcation. Longitudinal incision of the vagal perineurium revealed a 7 mm parathyroid adenoma, which was enucleated. The patient recovered uneventfully, with normalization of serum calcium and parathyroid hormone (PTH) and normal vocal cord function.

CONCLUSION

This is the first reported case of non-supernumerary intravagal parathyroid adenoma resected at initial exploration. The vagus nerve is a rare location for a parathyroid adenoma, but one that should be considered even during primary exploration.

Table 1: Ectopic intravagal parathyroid adenoma in primary hyperparathyroidism

<i>Author year</i>	<i>No. of cases</i>	<i>No. of previous explorations</i>	<i>Operations performed</i>	<i>No. of other parathyroid glands seen</i>	<i>Imaging performed</i>	<i>Location adenoma</i>	<i>Supernumerary</i>
Reiling et al ¹⁷ 1972	1	1	Total thyroidectomy	2	US, CT, scintigraphy	At level of right carotid bifurcation	No
Takimoto et al ²³ 1989	1	0	Subtotal parathyroidectomy	2 left 2 right	Repeat US, CT, and scintigraphy	Below left carotid bifurcation	Yes
Doppman et al ²² 1994	1	4	Right hemithyroidectomy, thymectomy, mediastinal exploration	2 left 1 right	Repeat US, MR, CT, scintigraphy Venous sampling Arteriography – injection of right external carotid	Above right carotid bifurcation	No
Buell et al ²⁴ 1995	1	4	Right hemithyroidectomy, thymectomy, median sternotomy	2 left 1 right	Angiography, chest MR, venous sampling, repeat US, CT, MR and scintigraphy, venous sampling	Above right carotid bifurcation	No
Pawlik et al ²⁵ 2001	1	1	Subtotal parathyroidectomy, right hemithyroidectomy and thymectomy	4	Repeat venous sampling and US	Below left carotid bifurcation	yes
Chan et al ⁴ 2003	4	2-4	Thymectomy, total thyroidectomy, two previous carotid sheath explorations	¥	Repeat US, SPECT, sestamibi, CT and MRI, angiography and venous sampling	3 above carotid bifurcation (2 left, 1 right) 1 below right carotid bifurcation	3 yes, 1 unclear
Daruwalla et al 2014 (this study)	1	0	Left neck exploration with cervical thymectomy	0 (right side not explored)	Initial US and scintigraphy	At level of carotid bifurcation	no

*Patients referred from other institutions and studies unable to clarify from op note and path slides how many parathyroids were previously identified or inadvertently removed

Abbreviations: US: Ultrasound, CT: Computerized tomography, MR: Medical resonance, SPECT: Single-photon emission computed tomography

Multiple Combined with Recurrence Parathyroid Carcinoma (One Case Report)

¹Peisong Wang, ²Yi Han, ³Guang Chen

¹⁻³Department of Thyroid Surgery, The First Hospital of Jilin University, Changchun, Jilin, China

BACKGROUND AND AIMS

Multiple combined with recurrence parathyroid carcinoma is rarely reported in the literature. Compared with solitary parathyroid carcinoma, there is no doubt that multiple combined multiple recurrence parathyroid carcinoma would increase the difficulty of diagnosis, misdiagnosis, and the risk of reoperation.

METHODS

A 64-year-old male patient was diagnosed with parathyroid carcinoma in our department in July 2005.

RESULTS

Because the presence of other tumors was not noticed, the patient underwent surgery three times. He had three parathyroid carcinoma lesions, two on the right side of the neck (one being recurrence parathyroid carcinoma lesion) and one on the left side (Figs 1 to 3).

CONCLUSION

In order to improve the prognosis of patients, there are some treatment experiences worth sharing. En-bloc resection should be recommended. Preoperative FNA is not recommended. Intraoperative frozen pathology has certain reference value, but the misdiagnosis rate remains high. In single cancer cases, we should perform tumor resection together with ipsilateral thyroid lobe resection and lymph node dissection, including thymic tongue and lymph nodes around the trachea. At the same time, we should explore other parathyroid glands. We should give importance not only to treat the primary disease but also to avoid complications. Postoperative monitoring of PTH and blood calcium concentration is necessary. If they remain high, it suggests the tumors have not been completely removed or other lesions exist, even distant metastasis, and it has poor prognosis.

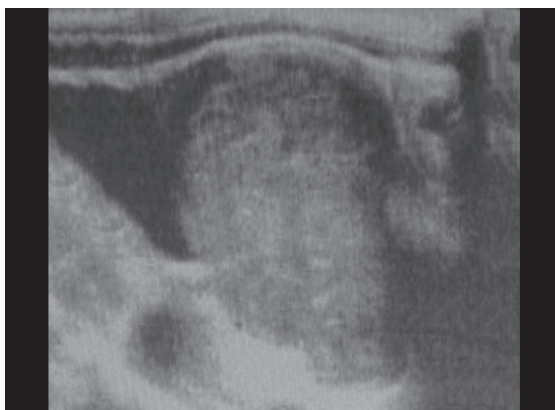


Fig. 1: Ultrasound showing a lesion of substantial neoplasm, about 3.3 × 2.2 cm

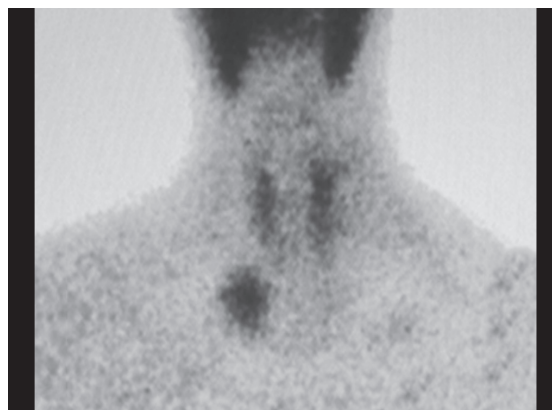
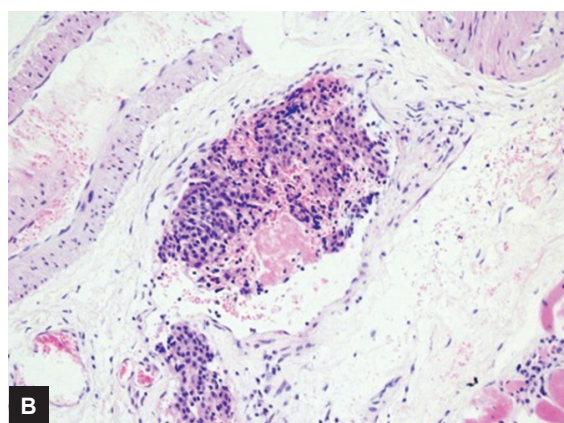
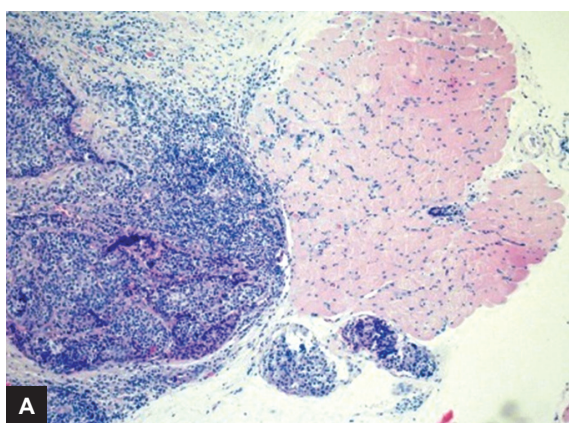


Fig. 2: Parathyroid scintigraphy showing lower right hyperplasia/adenoma



Figs 3A and B: (A) The tumor invaded muscle tissue and blood vessels around (HE ×100), (B) The tumor invaded capsule tumor blood vessels (HE ×200)

Experience in the Diagnosis and Treatment of Parathyroid Carcinoma (A Report of Six Cases)

¹Peisong Wang, ²Gui-Min Wang, ³Shuai Xue, ⁴Di Wu, ⁵Shuo Wang, ⁶Yi Han, ⁷Li-Juan Zheng, ⁸Guang Chen

¹⁻⁸Department of Thyroid Surgery, The First Hospital of Jilin University, Changchun, Jilin, China

BACKGROUND AND AIMS

To study the clinical characteristics of parathyroid carcinoma (PTC).

METHODS

The clinical data of six cases of PTC in our hospital from January 2005 to June 2012 were analyzed retrospectively.

RESULTS

Among the group, the male-to-female ratio was 1:1, and the median age was 46 years. The proportion of patients with osteoarticular and urinary system symptoms was 33.33%. Five cases out of six had a hard painless palpable neck mass. Localization diagnosis rate of ultrasound was 66.67%. Diagnostic rate of parathyroid 99Tcm-MIB scan was 75.00%. Hypercalcemia ratio was 83.33%. Three patients who checked the PTH level all had elevated iPTH (4.2–32.4 times). For only one case, PTC was diagnosed by rapid intraoperative frozen pathological. Postoperative pathology Confirm surrounding infiltration in all cases.

CONCLUSION

Parathyroid carcinoma has a considerable proportion of male and female patients. There is an increase in the percentage of asymptomatic patients. Compared with benign PHPT, the value of calcium, iPTH, and ALP increases more apparently. The diagnosis of PTC largely depends on the intraoperative judgment of the gross specimen instead of intraoperative frozen pathology. The diagnosis of parathyroid carcinoma should be combined with pathological findings and clinical data especially intraoperative findings. Surgery is still the preferred treatment for PTC currently.

Experience in the Diagnosis and Treatment of Parathyroid Tumor (A Report of 45 Cases)

¹Peisong Wang, ²Shuai Xue, ³Guang Chen, ⁴Gu-imin Wang

¹⁻⁴Department of Thyroid Surgery, The First Hospital of Jilin University, Changchun, Jilin, China

BACKGROUND AND AIMS

To investigate the diagnosis and treatment of parathyroid tumor.

METHODS

The clinical data of 45 patients with parathyroid tumor (34 cases of parathyroid adenoma, 5 cases of parathyroid cysts, and 6 cases of parathyroid carcinoma) admitted to our hospital in recent years were retrospectively analyzed.

RESULTS

Eighteen patients had obvious clinical symptoms. The localization diagnosis rate of ultrasound and 99Tcm-MIBI scan were 93.33 and 86.96% respectively. Among the 33 patients who checked the iPTH level, 30 patients had elevated iPTH. Hypercalcemia ratio was 61.36%. All the patients whose lesion had been removed successfully had symptoms of hypocalcemia after surgery. The iPTH level returned to normal 3 to 7 days after surgery; only one case had no significant change in iPTH level; this patient died of multiple metastases after 2 years.

CONCLUSION

When elevated serum calcium, repeated urinary stones, bone and joint pain, osteoporosis, and digestive symptoms are encountered in clinical work, we should be alert to the possibility of PHPT. Nonfunctioning parathyroid cysts can be observed without disposal. For parathyroid adenoma, parathyroid tumor resection is feasible if its position is accurate. For PTC, surgery is the treatment of choice. After surgery, serum calcium, serum phosphorus, PTH, and ALP should be monitored routinely.

The Effect on Parathyroid Function of the Central Lymph Node Dissection

¹Guimin Wang, ²Chang Su, ³Dahai Xu, ⁴Wenxin Zhang, ⁵Zengguang Liu, ⁶Peisong Wang

¹⁻⁶ Department of Thyroid Surgery, The First Hospital of Jilin University, Changchun, Jilin, China

BACKGROUND AND AIMS

To investigate the effect on parathyroid function of the central lymph node dissection and the intraoperative protection method for parathyroid.

METHODS

A total of 118 patients were selected according to the standard, and were divided according to the type of operation into A group undergoing bilateral total thyroidectomy (18 cases) and B group undergoing bilateral total thyroidectomy combined with the central lymph node dissection (100 cases). Both groups accepted gluconate 4 g/d from the onset of the surgery day, and then we compared and analyzed serum calciumion, PTH, and symptom of hypocalcemia of preoperative, postoperative 1st, 3rd, 5th, 7th day and 1 month of both groups.

RESULTS

All patients had no permanent hypoparathyroidism and permanent hypocalcemia; temporary hypoparathyroidism occurred in 50% (59/118). In group A, PTH reduction rate was 22.22% (4/18), and in group B it was 55% (55/100). A significant difference existed between the two groups. PTH of postoperative 1st, 3rd, 5th, 7th day and 1 month were: group A 22.68 ± 16.85 , 17.08 ± 10.07 , 17.43 ± 10.48 , 19.98 ± 11.70 , 33.03 ± 14.87 , and B group 13.41 ± 11.01 , 11.97 ± 9.46 , 11.67 ± 9.06 , 14.33 ± 10.04 , 28.29 ± 15.38 pg/ml. The PTH of postoperative 1st, 3rd, 5th, 7th day and 1 month in group B were less than in group A, with significant differences. The calcium ion level of postoperative 1st, 3rd, and 5th day in group A were was than in the preoperative case, with significant differences; the calcium ion level of postoperative 1st, 3rd, 5th, and 7th day in group B was less than in the preoperative case, with significant differences ($p < 0.01$), and the postoperative 1-month calcium ion level had no significant difference from preoperative case.

CONCLUSION

The surgery of total thyroidectomy and total thyroidectomy combined with cleaning of the lymph node in the central region is often prone to cause temporary hypoparathyroidism after surgery, the latter one more often and more severe. Most patients recover from the hypoparathyroidism in 1 month, and rarely step into the permanent hypoparathyroidism. So total thyroidectomy combined with cleaning of the lymph node in the central region is relatively safe. For only total thyroidectomy, the gluconate injection from the onset of operation day can avoid hypocalcemia. For total thyroidectomy combined with cleaning of the lymph node in the central region, individual therapy is advocated. The twice separation for the central lymph node dissection of parathyroid glands, to some extent, affects the parathyroid gland function. The key to prevent patients from hypoparathyroidism is protection of the parathyroid gland in surgery.

Total Parathyroidectomy without Autotransplantation for Renal Hyperparathyroidism in Patients without Access to Renal Transplant

¹Tommy Siu-Man Yip, ²Shirley Yuk-Wah Liu, ³Enders Kwok-Wai Ng

¹⁻³Department of Surgery, Chinese University of Hong Kong, Hong Kong, China

BACKGROUND AND AIMS

In renal hyperparathyroidism (RHPT), subtotal parathyroidectomy (SPx) or total parathyroidectomy (TPx) with autotransplantation is the recommended treatment to prevent permanent hypoparathyroidism and lifelong need of vitamin D and calcium supplementation. In patients without access to renal transplantation, these surgical approaches may inevitably increase the long-term risk of recurrent hyperparathyroidism. Due to the shortage of kidney donors, TPx alone without autotransplantation is often performed in Hong Kong. The objective of this study is to compare the long-term outcomes between patients receiving TPx alone and SPx for RHPT.

METHODS

This was a retrospective comparative analysis on consecutive patients undergoing either TPx alone (4-gland removal) or SPx (3.5-gland removal) before 2005 in managing RHPT. Exclusion criteria were parathyroidectomy after renal transplant, less than 4-gland operative identification, and TPx with autotransplantation. Long-term biochemical and clinical outcomes were analyzed.

RESULTS

Between 1997 and 2005, 46 RHPT patients underwent parathyroidectomy by TPx alone ($n=40$) and SPx ($n=6$). No significant difference was observed between TPx and SPx groups for their baseline demographics, preoperative PTH levels (182.7 ± 82.8 vs 179.5

± 94.8 pmol/L, $p=0.92$), ALP levels (465.2 ± 378.0 vs 507.2 ± 442.1 IU/L, $p=0.72$), and the duration of RHPT (6.8 ± 4.7 vs 7.7 ± 3.3 years, $p=0.60$). Their perioperative outcomes were comparable. In mean follow-up of 9.3 ± 3.2 years, none of the patients in either group received renal transplantation. The rate of recurrent hyperparathyroidism was significantly higher in SPx group than in the TPx alone group (50.0 vs 7.5% , $p=0.03$). Reoperative parathyroidectomy was required in 16.7% SPx patients and 2.6% TPx patients.

CONCLUSION

Despite the need of lifelong vitamin D and calcium supplementation, TPx alone without autotransplantation was associated with significantly lower risk of long-term recurrent hyperparathyroidism in patients without access to renal transplant.

Incidence and Implications of the Ectopic Parathyroid Gland: Preliminary Experience in a Single-surgeon Series

Doreen LP Lee

Department of General Surgery, Queen Elizabeth Hospital, Kota Kinabalu, Sabah, Malaysia

BACKGROUND AND AIMS

Ectopic and supernumerary parathyroid glands account for recurrent and persistent hyperparathyroidism (HPT). Ectopia results from aberrant migration of the parathyroid embryologic origin. This study was conducted with the following aims:

- To ascertain the prevalence and location of parathyroid glands in parathyroidectomy patients.
- To evaluate the outcomes of surgery.

METHODS

Data were obtained from a parathyroid database about a single-surgeon series of 49 consecutive parathyroidectomy patients. Primary hyperparathyroid (PHPT) patients had preoperative localization with technetium-99m-sestamibi imaging. Neck ultrasound was performed for all patients. Renal hyperparathyroid patients were subjected to bilateral neck exploration with routine cervical thymectomy.

RESULTS

Ectopic parathyroid (PT) was evident in 25 patients (51%) with 7 in the PHPT group and 18 in the renal HPT group. There were 42 ectopic glands. Ectopic superior PT (55%) was most commonly located paraesophageally (28.6%) followed by 7 intrathyroidal (16.7%) and 2 within the carotid sheath (4.7%). There was one gland embedded in Reeve's space, paratracheal position (2.4%).

A total of 33.3% of ectopic inferior glands were encountered in retroclavicular and infraclavicular component of the thymus (14), three within thyroid parenchyme (7.1%), one each in the carotid sheath and mediastinum (4.7%).

The average time required to complete a standard orthotopic 4-gland parathyroidectomy was 60 minutes. The presence of ectopic glands prolonged surgery by a mean duration of 52 minutes. Two patients were operated under surgeon-performed regional anesthesia and one had a sternal split. There were no recurrent or persistent hyperparathyroidism at a median follow-up of 17.5 months.

CONCLUSION

The presence of ectopic PT glands in this analysis is significant. The end result of the exhaustive search was justified and gratifying. Neck ultrasound has low sensitivity in the localization of enlarged PT glands. Meticulous systemic exploration of the neck determines a successful outcome to achieve cure for these already debilitated patients.

Clinicopathological Features and Causes of Failure of Parathyroidectomy in Primary Hyperparathyroidism

¹Syakir Azahar, ²AB Ainal Huda, ³B Sarinah, ⁴K Normayah, ⁵B Anita, ⁶MN Hisham

¹Department of Surgical Oncology, National Cancer Institute, Putrajaya, Malaysia

²⁻⁶Department of Breast and Endocrine Surgery, Putrajaya Hospital, Putrajaya, Malaysia

BACKGROUND AND AIMS

The clinical spectrum of primary hyperparathyroidism has undergone a striking change in developed countries, with the predominant form being asymptomatic hyperparathyroidism. However, such trend has not been documented in Malaysia. We examined the clinicopathological features and outcomes of surgery following first-time parathyroidectomy in our primary hyperparathyroidism (PHPT) patients and subsequently explored factors that could be associated with failure.

METHODS

We retrospectively reviewed 335 patients with biochemical evidence of PHPT who underwent primary surgery at Hospital Putrajaya from 2002 to 2015. Their clinical presentations, biochemical parameters, preoperative imaging, operative procedures, final histology, and outcome of surgery were analyzed.

RESULTS

The mean age of our patients was 58 years (18–75) and majority were female (60.7%). Only 13% of patients were asymptomatic. The most common presenting features were renal stones (32.1%), fatigue or body weakness (19.7%), and bony pain (18%). The mean serum calcium level was 3.1 $\mu\text{mol/L}$. About 35% of patients had serum calcium between 3 and 3.5 $\mu\text{mol/L}$ and another 15% more than 3.5 $\mu\text{mol/L}$. The first 292 patients had only single preoperative localization using a surgeon-performed ultrasound and the subsequent 63 patients had dual modalities (surgeon-performed ultrasound and Tc-99m sestamibi with SPECT/CT).

Our failure rate (persistent disease) was 5.4% (18/335) and recurrent rate was 1.8% (6/335). Almost all of the persistent cases had only a single preoperative localization (23/24). Of the 18 patients with persistent disease, 5 had double adenoma, 6 had multiglandular disease, 2 ectopic gland, and 2 intrathyroidal. All patients with recurrent disease had parathyroid carcinoma.

CONCLUSION

A significant proportion of failures were due to the inability to recognize the presence or extent of multiglandular disease and double adenoma. The measurement of intraoperative parathyroid hormone (iOPTH) may be helpful to reduce the failure rate.

Impact of Preoperative Calcium Loading with Predicted Elemental Calcium Requirement in Achieving Stable Calcium Level after Total Parathyroidectomy in Renal Hyperparathyroidism

¹Juliana Abdul Latiff, ²Kugan Raman, ³Sarinah Basro, ⁴Normayah Kitan

¹⁻⁴Department of Surgery, Hospital Putrajaya, Putrajaya, Malaysia

BACKGROUND AND AIMS

Achieving stable calcium level after total parathyroidectomy is challenging due to severe hungry bone syndrome observed in renal hyperparathyroidism. Serum alkaline phosphatase (ALP) is useful in determining the amount of calcium requirement after parathyroidectomy.

METHODS

The study examined the impact of calcium replacement protocol on calcium stabilization and length of hospital stay following total parathyroidectomy in renal failure patients.

This was a cross-sectional study conducted from December 2011 until December 2014.

All renal hyperparathyroidism patients who underwent total parathyroidectomy at Hospital Putrajaya were included. Those with parathyroid cancer and primary hyperparathyroidism were excluded. Group A comprised patients between 2011 and 2013 in whom the calcium requirement were started postoperatively based on the serum calcium level to achieve a stable calcium level. Group B comprised patients with the introduction of the calcium replacement protocol. These patients were treated with calcium to induce hypercalcemia in the preoperative period and the regime was adjusted postoperatively. The duration to stabilize the calcium between these two groups was analyzed.

RESULTS

There were 44 patients in group A and 36 patients in group B. In group B, the duration for calcium stabilization postoperatively was reduced from a median of 5 days (interquartile range=24) to 3 days (interquartile range=3) after the introduction of the protocol as a result of better calcium balance ($p < 0.001$).

CONCLUSION

The study showed that preoperative calcium loading with predicted postoperative calcium requirement can achieve early calcium stabilization leading to early discharge.

Can Postoperative Early Parathormone predict Hypocalcemia after Sutureless Thyroidectomy? Cerrahpasa Experience

¹Murat Ozcan, ²Serkan Teksoz, ³Akif Enes Arikan, ⁴Selen Soylu
⁵Cemre Ozdemir, ⁶Recep Ozgultekin, ⁷Yusuf Bukey, ⁸Ates Ozyegin

^{1-4,6-8}Department of General Surgery, Cerrahpasa Medical Faculty, Istanbul University, Istanbul, Turkey

⁵Cerrahpasa Medical Faculty, Istanbul University, Istanbul, Turkey

BACKGROUND AND AIMS

Parathyroid hormone regulates calcium metabolism by promoting transfer of calcium into and out of bone, resorbing in the kidneys, and absorbing from the gastrointestinal tract. This study investigates the predictive value of early preoperative parathyroid hormone (PTH) on hypocalcemia after sutureless total thyroidectomy with energy-based devices.

METHODS

Patients who underwent sutureless total thyroidectomy between January 2014 and October 2015 were analyzed retrospectively. Patients with a history of previous thyroidectomy or parathyroidectomy, patients who underwent parathyroidectomy (incidental or intentional) or hemithyroidectomy, and patients with hypo/hypercalcemia or hypo/hyperparathyroidism before surgery were excluded. Alteration in PTH levels after thyroidectomy (obtained in first 12 hours) was compared for hypocalcemia according to laboratory results. ROC analysis was performed for detecting sensitive and specific PTH alteration.

RESULTS

There were 514 patients who underwent sutureless thyroidectomy. Of these, 399 were female and 115 were male. The average age was 48.9 ± 13.1 years. Only 1 (0.2%) patient had hypoparathyroidism, 132 (25.7%) had hyperparathyroidism, 36 (7%) was hypocalcemic, and 2 (0.4%) were hypercalcemic preoperatively. In total, 358 patients were included in the study. Values of preoperative and postoperative PTH and calcium are given in Table 1. The ROC analysis was performed to test PTH change and hypocalcemia in laboratory results. When postoperative PTH was less than or equal to 63% of preoperative value, hypocalcemia was seen with 60% sensitivity and specificity.

Table 1: Pre- and postoperative PTH and adjusted calcium values

	<i>Minimum</i>	<i>Maximum</i>	<i>Average</i>	<i>Std. deviation</i>
Preoperative PTH (pg/ml)	18.34	64.81	43.71	10.99
Preoperative calcium adjusted for albumin (mg/dl)	8.40	10.18	9.04	0.345
Postoperative PTH (pg/ml)	1.66	117.00	28.84	18.32
Postoperative calcium adjusted for albumin (mg/dl)	5.61	10.43	8.52	0.45

CONCLUSION

Alteration in postoperative PTH value according to preoperative value can be a helpful tool in prediction of post-thyroidectomy hypocalcemia.

The Accuracy of FNAC for Thyroid

¹Tatsuya Hojo, ²Naotaka Nomura, ³Kei Nakahara, ⁴Takema Sakoda

¹⁻⁴Department of Otorhinology, Rinku General Medical Center, Izumisanoshi, Osaka, Japan

BACKGROUND AND AIMS

Thyroid nodules are common clinical findings and have a reported prevalence of 4 to 7% of the adult population. In Japan, these days several health examinations have been developed. People are pointing out their thyroid lesions by accident. Fine needle aspiration cytology (FNAC) is a useful method for the diagnosis of lesions.

This is a retrospective study of 213 diagnosed cases of thyroid nodules who underwent FNAC for diagnosis. The results were categorized according to the recent Japan Thyroid Association classification into: insufficient for diagnosis, benign, indeterminate, suspicious for malignancy, and malignant.

And 58 of the 213 FNAC cases underwent surgery of the thyroid gland. Fine needle aspiration cytology diagnoses were compared with their corresponding final histologic ones.

METHODS

Thyroid swellings were aspirated using 22-gauge disposable needles using standard procedures under US-guidance.

RESULTS

The study included 213 cases presented with thyroid nodules who underwent diagnostic thyroid FNAC. The female-to-male ratio was 3.5:1, and the median age was 64.6 years. A total of 152 cases (71%) were diagnosed as benign, 17 cases (8%) as indeterminate, 5 cases (2.4%) as suspicious for malignancy, 21 cases (9.9%) as malignant, and 18 cases (8.5%) as unsatisfactory.

Of about 58 cases undergoing surgery, the final histologic diagnoses showed 18 cases (31%) of adenomatous goiter, 7 cases (12%) of follicular adenoma, 23 cases (40%) of papillary carcinoma, (6.8%) cases of follicular carcinoma, 1 case (1.7%) of poorly differentiated carcinoma, 1 case (1.7%) of undifferentiated carcinoma, and 2 cases (3.4%) of malignant lymphoma.

Cytologic diagnoses were compared with their corresponding final histologic ones. Fine needle aspiration cytology achieved a sensitivity of 92.8%, a specificity of 94.2%, a positive predictive value of 100%, a negative predictive value of 73%, and a total accuracy of 83%.

CONCLUSION

Fine needle aspiration cytology is regarded as the standard initial investigation in the diagnosis of thyroid swellings. The technique is safe, simple, and quick.

Myricetin induces Human Papillary Thyroid Cancer Cell Death via BAX and Caspase-dependent Pathway

¹Tae Kwun Ha, ²Ha-kyoung Park, ³Sang-hyo Kim

^{1,3}Department of Surgery, Busan Paik Hospital, Busan, Korea

BACKGROUND AND AIMS

Myricetin is a member of the flavonoid class of polyphenolic compound with antioxidant properties and is found in various berries, herbs, and walnuts. According to several previous studies, it seems to demonstrate anticancer activity against hepatocellular carcinoma, skin carcinoma, and pancreatic cancer. However, the anticancer activity of myricetin on human thyroid cancer cells has not been studied yet.

METHODS

We investigated the anticancer effects of myricetin on SNU-790 human papillary thyroid cancer cells (HPTC).

RESULTS

We found that myricetin induces cytotoxicity and cell death in SNU-790 HPTC in a dose-dependent manner. We determined myricetin-induced apoptotic cell death by Annexin/PI staining assay. Myricetin treatment turned the SNU-790 HPTC populations into apoptotic cells by showing PI positive, indicating necrosis in a dose-dependent manner. We determined that myricetin decreases the activation of caspase-3 and -9 and increases the release of BAX from 100 μ M by Western blot analysis on SNU-790 HPTC.

CONCLUSION

These results suggest that myricetin-induced apoptosis was mediated by BAX and caspase-dependent pathway. This may prove useful in the development of therapeutic agents for papillary thyroid cancer.

Could Radiofrequency Ablation be an Alternative Treatment Option for Micropapillary Carcinoma of Thyroid Gland?

¹Byung Seup Kim, ²Kyungho Kang, ³Tae Ik Eom

^{1,3}Department of Surgery, Hiu Clinic, Seoul, Korea

²Department of Surgery, Chung-Ang University Hospital, Seoul, Korea

BACKGROUND AND AIMS

We report a case of a 41-year-old woman with papillary thyroid cancer, managed with ultrasound-guided percutaneous radiofrequency ablation (RFA).

METHODS

The sonogram and fine-needle aspiration cytology (FNAC) revealed 0.6 \times 0.5 cm sized papillary thyroid carcinoma (PTC) in the right lobe upper pole. We recommended right lobectomy to her, but she refused operation because she was planning to conceive

via artificial fertilization. We considered alternative delayed operation after delivery, but she had phobia about cancer. So we decided to perform RFA for PTC. The tumescent was injected around the upper pole of the right thyroid lobe just before RFA to avoid thermal damage to recurrent laryngeal nerve and sympathetic trunk. After securing safe distance between cancer tissue and surrounding nerve structures, we performed RFA including normal tissue around cancer. The RFA needle was moved back after complete ablation to avoid cancer seeding. There were no complications associated with RFA.

RESULTS

After 1 month, she was pregnant. The necrotic lesion was measured sonographically as being 0.9×0.7 cm at 3 months after RFA. The lesion decreased to 0.5×0.3 cm in size 9 months after RFA. At that time, re-FNAC for RFA lesion showed acellular specimen. The aspirated specimen was very thick. The lesion became a small spot 12 months after RFA. There are still no local recurrences or regional or distant metastasis 48 months after RFA.

Is Aggressive Treatment Mandatory in Familial Papillary Thyroid Carcinoma Patients?

¹Sohee Lee, ²Jaseong Bae, ³Yong-Seok Kim, ⁴Jeong-Soo Kim

^{1,2}Department of Surgery, Seoul St Mary's Hospital, College of Medicine, The Catholic University of Korea, Seoul, Korea

^{3,4}Department of Surgery, Uijeongbu St Mary's Hospital, College of Medicine, The Catholic University of Korea, Uijeongbu, Korea

BACKGROUND AND AIMS

Familial papillary thyroid carcinoma (PTC) was known to show less-favorable prognostic features than the sporadic form; therefore, more aggressive treatment and careful follow-up have been recommended. However, there are some debates on the aggressiveness and treatment policy of early detected familial PTC with increased use of high-resolution ultrasonography. The aim of this study was to investigate the biological aggressiveness of familial PTC.

METHODS

Between September 2008 and July 2015, a total 123 patients of familial PTC were evaluated. Clinical and histopathological features and outcome were compared to that of 3,958 sporadic PTC patients followed in the same period according to the same institutional protocols.

RESULTS

The numbers of family members with PTC were two in 111 families, three in 10 families, 4 in 2 families, and 5 in 1 family. The mean age of familial PTC was similar with sporadic PTC; however, age younger than 45 years was more frequent in familial PTC (55.3 vs 45.6%, $p = 0.035$). The mean tumor size and the proportion of microcarcinoma were similar between the two groups ($p = 0.487$ and 0.411 respectively). The rate of total thyroidectomy showed no significant difference and the extent of nodal dissection (CCND/mRND) was also similar in both groups ($p = 0.181$ and 0.995). The bilaterality was more frequent in familial PTC ($p < 0.001$) and other histologic factors including extrathyroidal extension, multiplicity, and TNM stage showed no significant differences between the two groups. The recurrence rate was similar between the two groups ($p = 0.866$).

CONCLUSION

Familial PTC shows similar biologic behavior with sporadic PTC; therefore, a more aggressive treatment is not mandatory with only familial history of PTC.

Changing Trends in the Clinicopathological Features and Clinical Outcomes of Medullary Thyroid Carcinoma

¹Hyemi Kwon, ²Won Gu Kim, ³Tae-Yon Sung, ⁴Min Ji Jeon, ⁵Dong Eun Song, ⁶Yu-mi Lee, ⁷Jong Ho Yoon, ⁸Ki-Wook Chung, ⁹Suck Joon Hong, ¹⁰Jung Hwan Baek, ¹¹Jeong Hyun Lee, ¹²Tae Yong Kim, ¹³Young Kee Shong, ¹⁴Won Bae Kim

^{1,2,4,12-14}Department of Internal Medicine, Asan Medical Center, University of Ulsan College of Medicine, Ulsan, South Korea

^{3,6-9}Department of Surgery, Asan Medical Center, University of Ulsan College of Medicine, Ulsan, South Korea

⁵Department of Pathology, Asan Medical Center, University of Ulsan College of Medicine, Ulsan, South Korea

^{10,11}Department of Radiology, Asan Medical Center, University of Ulsan College of Medicine, Ulsan, South Korea

BACKGROUND AND AIMS

The early detection of papillary thyroid cancer has contributed to the increase in the incidence and improved clinical outcomes. However, recent changes in medullary thyroid carcinoma (MTC) over time remain unclear. We evaluated changes in the clinicopathological characteristics and clinical outcomes in patients with MTC in recent years.

METHODS

A total of 109 MTC patients were classified based on the year of initial surgery: 1996–2000 (n=14), 2001–2006 (n=39), and 2007–2011 (n=56).

RESULTS

The primary tumor size significantly decreased and the proportion of micro-MTCs (size ≤ 1 cm) increased over time ($p=0.002$ and <0.001 respectively). The proportion of patients with cervical lymph node (LN) metastasis significantly decreased ($p=0.037$), and the ratio of metastatic LNs significantly decreased ($p=0.011$). The disease-free survival (DFS) rate of patients significantly improved over time ($p=0.007$). There was no significant difference in DFS between micro-MTC and macro-MTC patients. However, more advanced LN stage patients demonstrated more recurrences ($p<0.001$). Especially, there were significantly more recurrences in patients with N1b diseases in comparison with patients without cervical LN metastases ($p<0.001$).

CONCLUSION

The prognosis of MTC patients has significantly improved in recent years. These changes could be associated with the early diagnosis before the development of lateral and extensive cervical LN metastases.

Negative Expression of CPSF2 predicts a Poorer Clinical Outcome in a Patient with Papillary Thyroid Carcinoma

¹Tae-Yon Sung, ²Mijin Kim, ³Tae Yong Kim, ⁴Won Gu Kim, ⁵Yangsoon Park, ⁶Dong Eun Song, ⁷Su-yeon Park, ⁸Hyemi Kwon
⁹Yun Mi Choi, ¹⁰Eun Kyung Jang, ¹¹Min Ji Jeon, ¹²Young Kee Shong, ¹³Suck Joon Hong, ¹⁴Won Bae Kim

^{1,13}Department of Surgery, Asan Medical Center, University of Ulsan College of Medicine, Ulsan, South Korea

^{2,4,7-12,14}Department of Internal Medicine, Asan Medical Center, University of Ulsan College of Medicine, Ulsan, South Korea

^{5,6}Department of Pathology, Asan Medical Center, University of Ulsan College of Medicine, Ulsan, South Korea

BACKGROUND AND AIMS

The BRAFV600E mutation is a promising prognostic biomarker for patients with papillary thyroid carcinoma (PTC), but its incidence variation differs widely depending on geographic regions. A recent study reported that the loss of cleavage and polyadenylation specificity factor subunit 2 (CPSF2) gene was associated with increased cellular invasion, cancer stem cell, and aggressiveness of PTC. This study was aimed to evaluate the protein expression of CPSF2 as a prognostic marker of PTC, especially in regions with high prevalence of BRAFV600E mutation.

METHODS

This study included 159 patients with classical PTC who underwent total thyroidectomy and received ablative doses of 131I. Protein expression of CPSF2 was evaluated by immunohistochemistry and graded semi-quantitatively. The presence of BRAFV600E mutation was evaluated by direct sequencing.

RESULTS

Negative protein expression of CPSF2 was observed in 34 (21.3%) of the 159 PTC cases. The BRAFV600E mutation was significantly associated with CPSF2 positivity ($p=0.03$). In multivariate analysis, negative CPSF2 expression was significantly associated with cervical lymph node metastasis (OR 2.56, $p=0.28$), and distant metastasis (OR 3.48, $p=0.02$). After adjusting the age, gender, tumor size, extrathyroidal invasion, lymphovascular invasion, and BRAFV600E mutation, the CPSF2-negative group was significantly associated with lower recurrence-free survival compared to the CPSF2-positive group (hazard ratio 2.14, $p=0.03$).

CONCLUSION

Negative protein expression of CPSF2 was independently associated with poor clinical outcome of PTC. The expression of CPSF2 could be useful as a prognostic marker of PTC in regions with high prevalence of BRAFV600E mutation.

Micro-RNA Expression and BRAFV600E Mutation in Papillary Thyroid Carcinoma

¹Song I Yang, ²Kwang Kuk Park, ³Jeong Hoon Kim

^{1,3}Department of Surgery, Kosin University College of Medicine, Busan, South Korea

²Department of Surgery, Hub-Hu Hospital, Korea

BACKGROUND AND AIMS

Aberrant micro-RNA (miRNA) expression, particularly miR-221, miR-222, and miR-146b, increases in papillary thyroid carcinoma (PTC). BRAFV600E is the most frequently identified genetic alteration in papillary thyroid carcinoma. The purpose of this study

was to identify the link between BRAFV600E status and the expression of miRNAs in PTC and to analyze the associations of miRNAs with clinicopathological characteristics.

METHODS

The authors used total RNA of 51 formalin-fixed paraffin-embedded tissues of 42 PTCs (36 classic PTC, 6 follicular variant PTC) and 9 benign tumor to analyze the miRNA expression pattern of three selected miRNAs (miR-221, miR-222, and miR-146b using RT-PCR TaqMan miRNA assay to explore the diagnostic utility of this method, and the presence of the BRAFV600E mutation was determined by polymerase chain reaction amplification of exon 15 followed by direct sequencing.

RESULTS

The expression levels of all three miRNAs were significantly increased in PTC when compared to benign tumor. The expression miRNAs was significantly high in patients with cervical lymph node metastasis and advanced TNM stage. In addition, miR-146b expression levels were significantly higher in PTC patients with BRAFV600E mutation. The relative quantification ($2^{-\Delta\Delta Ct}$) of miR-146b was also high among the miRNAs. To evaluate the diagnostic value of these three miRNAs for PTCs, the receiver operating characteristic (ROC) curve analysis was performed. Individually, the AUC for miRNA-146b was 0.923 (cutoff value -1.97, sensitivity 88.9%, specificity 85.7%).

CONCLUSION

In this study, the expression of miR-221, miR-222, and miR-146b was associated with a poorer clinicopathological outcome. Especially, the expression of miR-146b increased more in PTC patients with BRAFV600E mutation. These findings showed a role of miR-146b as a potential biomarker in differentiating PTC from benign tumor and as a prognostic indicator of PTC. Further investigation is required to confirm the role of miRNAs in the pathogenesis of PTCs.

Clinicopathologic Features according to Capsulation between Papillary Thyroid Carcinoma and Follicular Variant of Papillary Thyroid Carcinoma

¹Song I Yang, ²Kwang Kuk Park, ³Jeong Hoon Kim

^{1,3}Department of Surgery, Kosin University College of Medicine, Busan, South Korea

²Department of Surgery, Hub-hu Hospital, Korea

BACKGROUND AND AIMS

The follicular variant of papillary thyroid carcinoma (FVPTC) is the most common histologic subtype of papillary thyroid carcinoma (PTC). But FVPTC is difficult to diagnose due to pathologic features. There is also debate on the optimal extent of surgery. We separated FVPTC into two groups and compared the clinical features in an attempt to apply the treatment.

METHODS

All 40 patients with FVPTC who were diagnosed between 1990 and 2009 were reviewed and separated into two groups, an encapsulated group and an infiltrative group, based on whether a capsule was formed or infiltration occurred. These two different subtypes of FVPTC were compared based on the traits of sensitivity of diagnosis and clinicopathologic features.

RESULTS

After review by a pathologist, 21 of 40 patients (55%) were found to have encapsulated tumors and 18 patients (45%) had infiltrative tumors. There was no difference in age, sex, or size. Patients with encapsulated FVPTC had a significantly lower rate of lymph node metastasis (4.5%), multicentric tumors (18.2%), and thyroid capsular invasion (9.1%) compared with the infiltrative tumor group (50, 50, and 50%, $p < 0.05$). There was no difference in FNA sensitivity between the two groups, but the sensitivity to frozen biopsy was higher in the infiltrative group. There was no recurrence in the encapsulated group, but four patients (22.2%) experienced recurrence in the infiltrative group.

CONCLUSION

The follicular variant of PTC can be separated into two subgroups by histologic features, and there are some clinicopathologic differences between the two groups. Patients who had encapsulated FVPTC had a lower rate of lymph node metastasis, multicentric tumors, and thyroid capsular invasion. They also showed a lower rate of recurrence than the infiltrative group. It is suggested that the encapsulated group can be treated with limited surgery and the infiltrative group needs aggressive treatment.

How Much do We leave Remnant Volume to reduce Hypothyroidism after Thyroid Lobectomy? Computed tomography-based Volumetry Study

¹Sang Uk Park, ²Jeong Soo Kim, ³Se Jeong Oh, ⁴Hoon Choi, ⁵Dong Sik Heo

^{1,3-5}Department of General Surgery, Incheon St Mary Hospital, Incheon, South Korea

²Department of General Surgery, Uijeongbu St Mary Hospital, Gyeonggi-do, South Korea

BACKGROUND AND AIMS

In several medical literatures, the risk factors of hypothyroidism after thyroid lobectomy are listed as high preoperative thyroid stimulating hormone (TSH), lower free thyroxine (T4), and thyroiditis factors. These factors may be predictable for hypothyroidism but not preventable. So we focus on the relationship between thyroid volume and postoperative hypothyroidism, and applied it to surgery.

METHODS

We retrospectively reviewed 240 patients with lobectomy from January 2011 through December 2014. Thyroid volume was calculated by computed tomography (CT) volumetry and compared to pathologic volume. The relationship between hypothyroidism and several factors, such as serum were compared TSH, free T4, thyroglobulin antibody, anti-thyroperoxidase (TPO) antibody, and compare isthmusectomy and not isthmusectomy.

RESULTS

There was no difference in CT volumetry and pathologic thyroid volume, and smaller remnant thyroid volume was significantly increased in hypothyroidism. High preoperative TSH was increased in hypothyroidism and other factors were not. Patients who underwent isthmusectomy had no difference compared to those who did not undergo isthmusectomy.

CONCLUSION

In patients with high TSH, more thyroid tissue seems to be able to prevent postoperative hypothyroidism.

Tract Recurrence of a Follicular Neoplasm after Endoscopic Thyroidectomy

¹HyunGu Kim, ²BoSung Chun, ³DongWook Park, ⁴Myung-jin Kim, ⁵JunWoo Lee

⁶JooHyun Woo, ⁷WooSung Lim, ⁸Nam-Sun Paik, ⁹Byung-In Moon

¹⁻⁹Department of Surgery, Ewha Womans University School of Medicine, Seoul, South Korea

BACKGROUND AND AIMS

Endoscopic thyroidectomy is drawing attention as an alternative to conventional thyroidectomy in patients with a benign thyroid nodule. Previous studies showed that this procedure is safe and feasible compared to conventional thyroidectomy. However, unexpected complications can arise from endoscopic procedure because several subcutaneous tracts are positively necessary. Especially, numerous authors reported that recurrence could occur in the tract of subcutaneous tissue.

METHODS

The authors experienced the interesting case of recurrence in the tract after unilateral endoscopic thyroidectomy due to the follicular neoplasm.

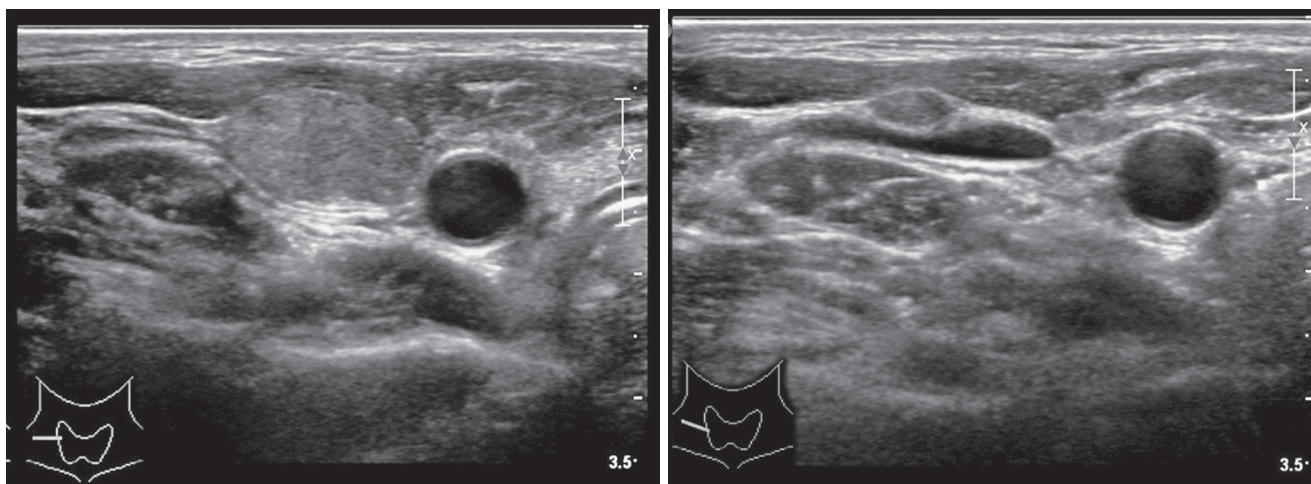
RESULTS

A 29-year-old woman visited our clinic with a complaint of palpable neck mass. She was diagnosed with follicular neoplasm and underwent an endoscopic hemithyroidectomy.

After 8 years, she came to our clinic with a right-sided neck mass. Ultrasonography showed three enlarged lymph nodes measuring 1.5 cm in maximal diameter at the right neck level IV area, which were assumed to be metastatic lymph nodes. Also, there was a small nodule in the remnant right thyroid, but it had no suspicious findings. She had a fine needle aspiration for suspicious lymph nodes and thyroid nodule. The pathologic report of lymph node was atypia or follicular lesion of undetermined significance, while that of the thyroid nodule was benign. Selective lymph node dissection was performed immediately with the conventional method. The lesion was tightly attached on the surface of the internal jugular vein. Pathological examination revealed an adenomatous hyperplastic thyroid nodule. Based on histological findings, the lesion was regarded as implantation of thyroid tissue detached from the specimen in previous endoscopic thyroidectomy. During the follow-up period of 60 months, there was no tumor recurrence.

CONCLUSION

When performing the endoscopic thyroidectomy with a large follicular neoplasm, clinicians should be careful not to separate the specimen and to remove all resected tissues.



Changing Trends in the Management of Well-differentiated Thyroid Carcinoma in Korea

¹Yong Sang Lee, ²Seok-Mo Kim, ³Hojin Chang, ⁴Bup-Woo Kim, ⁵Hang-Seok Chang, ⁶Cheong Soo Park

¹⁻⁶Department of Surgery, Thyroid Cancer Center, Gangnam Severance Hospital, Yonsei University College of Medicine, Seoul, South Korea

BACKGROUND AND AIMS

A questionnaire conducted in 2009 found that members of the Korean Association of Thyroid-Endocrine Surgeons (KATES) favored more aggressive treatment of well-differentiated thyroid carcinoma (WDTC) than physicians from other countries. This study assessed changes in the practical management of WDTC in Korea since the previous survey.

METHODS

Questionnaires were sent by e-mail to the members of KATES. Of these, 101 members completed the questionnaire. Their responses were compared with those of the 2009 survey.

RESULTS

Of the respondents, 53.5 and 80.2% indicated that they would perform fine-needle aspiration cytology on nodules <0.5 and 0.5 to 1.0 cm in diameter respectively. If cytology was positive, many respondents favored surgical treatment, regardless of tumor size. Compared with the 2009 survey, a slightly higher percentage favored observation of patients with tumors <0.5 cm in diameter, and a larger percentage recommended less-than-total thyroidectomy for patients with T1 cancers. Respondents in 2014 favored less-aggressive lymph node dissection, irrespective of tumor size, preferring short-term treatment with suppressors of thyroid-stimulating hormone. The percentage preferring postoperative high-dose radioactive iodine therapy slightly increased, whereas the percentage favoring external irradiation decreased in 2014 compared with 2009.

CONCLUSION

The management of Korean patients with WDTC changed from 2009 to 2014. In 2009, Korean respondents favored more aggressive treatment of WDTC than respondents from other countries. In 2014, however, Korean respondents favored a more conservative approach, especially of patients with microcarcinoma.

Cervical Great Vessel Invasion of Thyroid Carcinoma

¹Hyeung Kyoo Kim, ²Hyukjun Yun, ³Seok-Mo Kim, ⁴Hojin Chang, ⁵Bup-Woo Kim

⁶Yong sang Lee, ⁷Hang-Seok Chang, ⁸Cheong Soo Park

¹⁻⁸Department of Surgery, Yonsei University College of Medicine, Seoul, South Korea

BACKGROUND AND AIMS

Invasion of the tumor into great vessel of the cervical area is rare. It indicates the disease's aggressive nature. We present our experience with 81 patents who underwent surgical management for thyroid carcinoma and invasion to the cervical great vessel.

METHODS

Between November 2007 and April 2015, 81 patients were analyzed. A retrospective medical record was reviewed of patients who underwent thyroid surgery at Gangnam severance hospital. The clinicopathologic characteristics included gender, age, histology, LN dissection extents, invasion sites, surgical management of invasion, lateral neck site (level II, III, and IV), and operation type.

RESULTS

The median age was 50 (11–87), with 60.5% females. Histology was as follows: papillary 68 (84.0%), follicular 2 (2.5%), medullary 3 (3.7%), anaplastic 7 (8.6%), and metastatic 1 (1.2%). The origin of the invasion was thyroid in 9 cases (11.1%) and lateral neck node in 72 cases (88.9%). All patients underwent a thyroidectomy with or without lateral neck node dissection. The great vessel invasion site(s) were internal jugular vein (IJV) in 69 cases (85.2%), common carotid artery (CCA) in 5 (6.2%), and both IJV and CCA in 7 (8.6%). The surgical management of invasion were shaving-off procedure in 43 cases (53.1%), partial resection and repair in 7 (8.6%), and complete resection and ligation in 50 (38.3%). The lateral neck node level were level II in 4 cases (5.6%), level III in 18 (25%), and level IV in 50 (69.4%). The operation type was 1st-time operation in 69 cases (85.2%) and reoperation in 12 (14.8%).

CONCLUSION

Great vessel invasion of thyroid cancer was more common in lateral neck node invasion than thyroid direct invasion. Most lymph node invasions were level IV. More than half, 43 cases (53.1%), can be treated with the shaving-off procedure.

Single-incision Endoscopic Thyroidectomy by the Axillary Approach with Gas Inflation for Benign Thyroid Tumor: A Single Surgeon's Experience

¹Yohan Park, ²Kiyoung Sung

^{1,2}Department of Surgery, Bucheon St Mary's Hospital, The Catholic University of Korea College of Medicine, Seoul, South Korea

BACKGROUND AND AIMS

Endoscopic thyroid surgery has several advantages, including reduced postoperative pain and good cosmetic results. However, this procedure requires wide dissection area; therefore, it might cause severe wound pain and cosmetic disruption occasionally. Therefore, we performed trans-axillary single-incision endoscopic thyroidectomy (SIET) with gas inflation. The aim of this study is to present a single surgeon's experience with an SIET and to investigate the learning curve of an SIET.

METHODS

Between June 2009 and September 2014, a total of 105 patients who underwent hemithyroidectomy for the benign thyroid tumor via an SIET procedure were included in the present study. All of the procedures were performed by the same surgeon. Each patient's operative outcomes were prospectively collected and analyzed. The cumulative summation (CUSUM) analysis was used to assess the learning curve of an SIET.

RESULTS

No mortality and serious morbidity were observed during the study period. The overall mean operative time was 105 minutes and the mean operative time in the experienced phase was 95 minutes. CUSUM analysis showed decreasing trend for the 35th patient, suggesting that more than 35 cases were needed for surgeon's competency. A total of 79.76% patients were extremely satisfied with their wound postoperatively.

CONCLUSION

Our results seem to be reasonable compared to those of previous researches. The SIET procedure is safe and feasible for benign thyroid tumor and has acceptable learning curve for the surgeon who is competent with conventional endoscopic thyroidectomy.

Clinical Features of Micro-medullary Thyroid Carcinoma Less than 1 cm in Diameter

¹Ju Young Jang, ²Jae Hoon Chung, ³Sun Wook Kim, ⁴Tae Hyuk Kim, ⁵Yoon Young Cho

¹⁻⁵Division of Endocrinology and Metabolism, Department of Internal Medicine, Samsung Medical Center, Seoul, South Korea

BACKGROUND AND AIMS

The clinical behavior of medullary thyroid carcinoma less than 1 cm in diameter (micro-MTC) is not clear. The clinical characteristics of preoperative calcitonin-negative (<10 pg/ml) MTC has been reported to be heterogeneous, but it was not evident in micro-

MTC. Therefore, we conducted this study to evaluate the clinical features and outcome of micro-MTC compared to MTC > 1 cm (macro-MTC) and evaluated the clinical characteristics of calcitonin-negative micro-MTC.

METHODS

We reviewed the medical records of 133 patients with MTC who underwent total thyroidectomy with neck dissection at Samsung Medical Center from 1994 to 2014. Their median follow-up period was 55 (1–229) months.

RESULTS

Among 133 MTC patients, 50 had micro-MTC. Their median tumor size was 0.7 cm, and preoperative calcitonin and CEA levels were significantly lower than those in macro-MTC (median: 52 *vs* 854 pg/ml; 2.8 *vs* 20.2 ng/ml, $p < 0.001$). Comparing to macro-MTC, the patients with micro-MTC had significantly less frequent node metastasis (especially N1b), extrathyroidal invasion, and advanced stages (III/IV) (24 *vs* 53%; 6 *vs* 37%; 16 *vs* 45%; $p < 0.05$). They had no distant metastasis (0 *vs* 7%; $p < 0.05$).

Micro-MTC patients were divided into three groups according to preoperative calcitonin levels: group 1 (1–10 pg/ml, $n = 7$), group 2 (11–99 pg/ml, $n = 24$), and group 3 (> 100 pg/ml, $n = 14$). Group 1 had significantly smaller tumor size, less-frequent node metastasis, and less-frequent advanced stages (III/IV) than group 3 (median: 0.5 *vs* 0.8 cm; 14 *vs* 57%; 14 *vs* 36%, $p < 0.05$).

CONCLUSION

In conclusion, node metastasis, extrathyroidal invasion, and advanced stages were less common in micro-MTC than in macro-MTC. In micro-MTC, calcitonin levels were closely related to the high-risk clinicopathological factors. The results obtained here suggest that the calcitonin-negative micro-MTC may be considered as the most favorable subset in MTC patients.

Optimal Cut-off Values of Lymph Node Ratio predicting Recurrence in Papillary Thyroid Cancer

¹Seul Gi Lee, ²Jun Heo, ³Min Jhi Kim, ⁴Jung Bum Choi, ⁵Tae Hyung Kim, ⁶Eun Jeong Ban

⁷Cho Rok Lee, ⁸Jong Ju Jeong, ⁹Kee Hyun Nam, ¹⁰Jandee Lee, ¹¹Woong Youn Chung

¹⁻¹¹Departments of Surgery, Severance Hospital, Yonsei University College of Medicine, Seoul, South Korea

BACKGROUND AND AIMS

Regional lymph node (LN) metastasis has a significant impact for the prediction of recurrence in patients with papillary thyroid cancers (PTC); however, the prognostic value of the lymph node ratio (LNR), which is defined as the ratio of the number of metastatic LNs to the total number of investigated LNs, is controversial. In this study, we determined the optimal cut-off values of LNRs for the prediction of recurrence in PTC patients.

METHODS

This large cohort study retrospectively evaluated 2,294 patients who underwent total thyroidectomy for PTC at a single institution from October 1985 to June 2009. The prediction probability of central LNR (cLNR, level VI) and total LNR (tLNR, levels II–VI) was estimated by the binominal logistic regression analysis. Hazard ratios of the cut-off LNR values for cancer recurrence were calculated for relevant covariates using multivariate Cox regression analyses. Kaplan–Meier analyses were also utilized to assess the effects of estimated LNR cut-off values on recurrence-free survival (RFS).

RESULTS

Of the 2,294 patients, 138 (6.0%) presented cancer recurrence during the follow-up period (median duration = 107.1 months). The prediction probability indicated that LNRs of 0.4 and 0.5 for central LN and total LN respectively are optimal cut-off values for precise prediction with minimization of outliers. Multivariate Cox regression analyses revealed that $cLNR \geq 0.4$ was independently predictive of recurrence in patients with N0 and N1a PTCs [hazard ratio (HR): 7.016, 95% confidence interval (CI): 3.72–12.986, $p < 0.001$] and that $tLNR \geq 0.5$ indicated a significantly increased risk of recurrence in patients with N1b PTCs (HR: 2.372, 95% CI: 1.458–3.860, $p < 0.001$). In addition, Kaplan–Meier analyses clearly demonstrated that these LNR cut-off values are precisely operational in RFS estimation.

CONCLUSION

The cut-off values of 0.4 and 0.5 for cLNR and tLNR respectively were identified. Risk stratification combined with these LNR cut-off values may prove useful to determine treatment and follow-up strategies for PTC patients.

Retrosternal Goiter: A Case with Superior Vena Cava Obstruction

¹Maya Mazuwin Yahya, ²Syed Hassan S Ab Aziz, ³Zaidi Zakaria

¹⁻³Department of Surgery, Universiti Sains Malaysia, Penang, Malaysia

BACKGROUND AND AIMS

Retrosternal goiter is an enlargement of the thyroid gland that extends down to the mediastinum. The incidence of retrosternal goiter in thyroidectomy patients ranges from 1 to 20%. Patients usually present with obstructive symptoms. This is a case presentation of a patient with multinodular goiter with retrosternal extension

METHODS

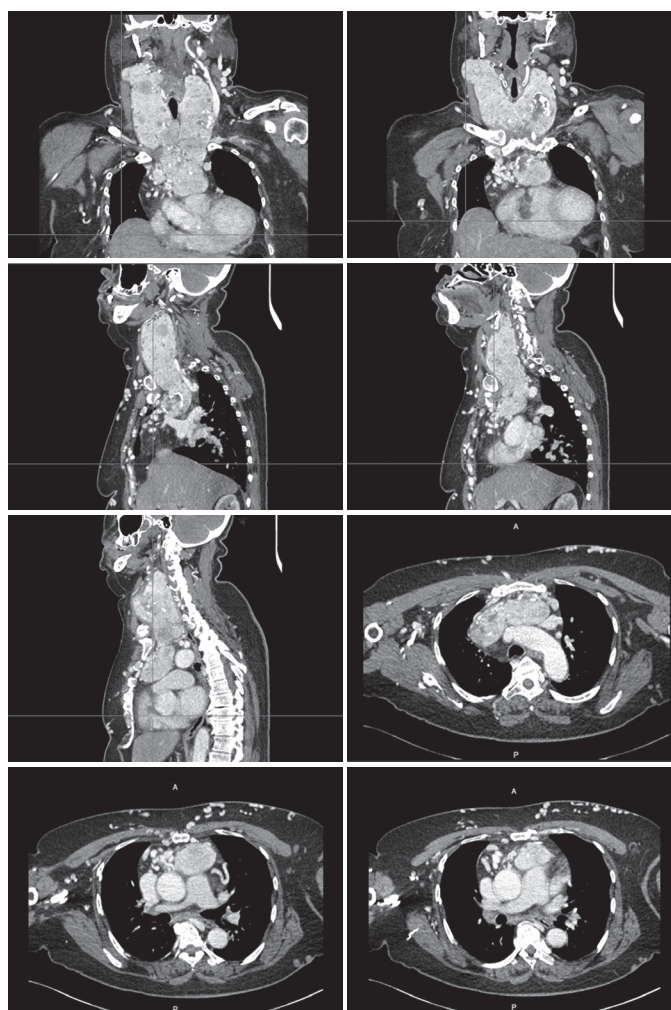
A 59-year-old lady presented with anterior neck swelling and progressive swelling of her face. She had a history of multinodular goiter for 19 years. Clinically she was mildly toxic and on low-dose carbimazole. There was anterior neck swelling and dilated superficial veins were noted at the upper part of her trunk. Her face was swollen and puffy. Contrast enhanced computed tomography scan showed a large multinodular goiter with retrosternal extension with compression to the trachea and superior vena cava.

RESULTS

Surgery was planned after cardiothoracic consultation. Through a successful cervical approach total thyroidectomy was done. The patient was discharged well. The histopathology examinations showed multinodular goiter.

CONCLUSION

The management of retrosternal goiter is surgery. Successful cervical approach may be discussed. Temporary tracheostomy may be necessary.



Thyroid Cancer in Queen Elizabeth Hospital (Sabah, Malaysia) 2010–2015: A Comprehensive Review

¹Jin-Jiun Mah, ²Siti Zubaidah Sharif, ³Saritra Raj, ⁴Doreen Lee

¹⁻⁴Department of Breast and Endocrine Surgery, Queen Elizabeth Hospital, Kota Kinabalu, Sabah, Malaysia

BACKGROUND AND AIMS

A surge in thyroid cancer incidence over the past three decades is a worldwide phenomenon, partly as a result of increasing use of ultrasonography and fine-needle aspiration cytology (FNAC) in cancer detection. There have been few detailed studies on thyroid cancers in Malaysia. We aim to review the records of thyroid cancer patients in Queen Elizabeth Hospital, Sabah.

METHODS

We designed a retrospective study for patients with thyroid cancers who were under follow-up in Queen Elizabeth Hospital from January 2010 to August 2015. The case records were retrieved and analyzed using SPSS version 22. Patients' demography, mode of presentation and risk factors, type of surgeries performed, intraoperative findings, postoperative outcomes, duration of follow-up, and histological variants were evaluated.

RESULTS

There were a total of 46 thyroid cancer patients, predominantly comprised of females (78.3%). The mean age of the patients was 45.8 years. Majority of the patients (76.1%) were euthyroid and had a single thyroid nodule (78.3%). Only 26.1% had associated symptoms and 6.5% had risk factors for thyroid malignancy. A total of 65.2% underwent total thyroidectomy, while 34.8% underwent hemithyroidectomy. Intraoperative findings revealed involvement of the surrounding structures in 23.9% patients, recurrent laryngeal nerve in 8.7% patients, and cervical lymph nodes in 30.4% patients. Postoperatively, six patients suffered vocal cord palsy, two had wound infection, and one had tracheostomy done. There was no incidence of hematoma formation. The mean follow-up period for the patients was 18.3 months. Histopathological examination showed 67.4% of papillary variant, 19.5% of follicular variant, 10.8% of papillary microcarcinoma, and 2.1% of medullary variant. Mean MACIS score was 7.21. A total of 80.4% of patients underwent/were referred radioactive iodine therapy and 13% had extranodal metastasis.

CONCLUSION

This is the first review of thyroid cancers in the state of Sabah, Malaysia. Future prospective studies can be done on the findings from this review.

Thyroid Storm due to Functioning Lung and Bone Metastases of Well-differentiated Thyroid Cancer

¹Nor Safariny Ahmad, ²Saiyidah Adila Mohd Adibi, ³Normayah Kitan

¹⁻³Department of Surgery, Hospital Putrajaya, Putrajaya, Malaysia

BACKGROUND AND AIMS

Thyroid storm resulting from functioning metastasis in well-differentiated thyroid cancer is rare. It may result from a large, bulky, and extensive metastatic tumor functioning either autonomously or after stimulation by TSH receptor antibody.

METHODS

We report a case of thyroid storm resulting from hyperfunctioning lung and bone metastases from well-differentiated thyroid cancer.

RESULTS

A 70-year-old woman underwent total thyroidectomy and bilateral modified radical neck dissection for follicular variant of papillary thyroid cancer in August 2015. Her computed tomography scan showed multiple lung and bone metastases. She was scheduled for radioactive iodine (RAI) therapy for her metastatic lesion. However, she presented with signs and symptoms of thyroid storm 1 week before her RAI. She had persistent vomiting, headache, high-grade temperature, supraventricular tachycardia, and low GCS in the ward. She was intubated for impending respiratory collapse and monitored in ICU. Her TSH was <0.03 mU/l (0.34–5.6) and fT4 was >76.7 pmol/l (7.9–14.4 pmol/l). Her Burch-Wartofsky score was >50 points, suggestive of thyroid storm. Unfortunately she passed away 5 days later due to myocardial infarction.

CONCLUSION

Thyroid storm due to functioning metastases from thyroid cancer is extremely rare. Hyperfunctioning thyroid cancer metastases represent therapeutic challenge compared to nonhyperfunctioning metastases from thyroid cancer, as both metastases cancer and thyroid storm need to be treated. The combination of thyroid storm and metastatic differentiated thyroid cancer has high morbidity and mortality.

Intraoperative Recurrent Laryngeal Nerve Monitoring in High-risk Thyroid Surgery: A Systematic Review

¹Yahya Mohd Aripin, ²Shaiful Amir Abdul Manap

^{1,2}Department of General Surgery, Universiti Teknologi MARA, Shah Alam, Malaysia

BACKGROUND AND AIMS

Systematic studies of intermittent intraoperative nerve monitoring (IONM) have shown that IONM does not significantly reduce rates of recurrent laryngeal nerve (RLN) palsy. The significance of IONM might be more apparent if it is used in high-risk thyroid surgery.

METHODS

A literature search for studies comparing IONM *vs* without IONM in high-risk thyroid surgery was performed. High-risk thyroid surgery includes thyroidectomy for cancer, Grave's disease, large goiter, and revision surgery. Studies were reviewed for overall, transient, and permanent RLN palsy per nerve and per patient at risk.

RESULTS

Four retrospective controlled studies and two retrospective observational studies were included. Most studies were on thyroid cancer except one controlled study on revision thyroidectomy and one controlled study on multiple risk factors including cancer, Grave's disease, and revision thyroidectomy. The rates of overall, transient, and permanent RLN palsy in thyroid cancer for IONM *vs* without IONM were 2.2 *vs* 3.7%, 1.8 *vs* 2.8%, and 0.5 *vs* 0.8% respectively. The overall rate in revision thyroidectomy with IONM *vs* without IONM was 0.8 *vs* 4.9%. None of these differences were statistically significant.

CONCLUSION

The current review shows no statistically significant differences in the rate of RLN palsy with or without the use of intermittent IONM in high-risk thyroid surgery. Nevertheless, it should be regarded as a promising supplementary tool to visual identification in preventing RLN palsy.

Characteristics of Medullary Thyroid Cancer Cases in Putrajaya Hospital

¹Suraya Baharudin, ²Ramizah Mohd Shariff, ³Lisa Mohamed Nor, ⁴Sarinah Basro

⁵Anita Baghawi, ⁶Nor Hisham Muda, ⁷Normayah Kitan

¹⁻⁷Breast and Endocrine Unit, Putrajaya Hospital, Putrajaya, Malaysia

BACKGROUND AND AIMS

Medullary thyroid cancer (MTC) is a rare cancer that accounts for only about 3 to 5% of thyroid cancer. It arises from the parafollicular cells that secrete calcitonin. Most commonly, it is sporadic. Lymph node metastases at presentation are seen in almost 50% of cases. Most of the cases have unilateral solitary nodule (75%).

METHODS

We reported retrospective data of 21 cases of MTC that were being treated at Putrajaya Hospital from 2002 till October 2015.

RESULTS

We had 21 patients who were being managed at our center, of which eight patients were being referred for further management after primary surgery was done. We had almost equal gender distribution with 57% of cases aged less than 40 years. Ethnic distributions were as follows: 8 Malay, 7 Indian, 5 Chinese, and 1 other. All of our cases had palpable anterior neck swelling with 13 cases with lymph node metastasis at presentation. The average tumor size was 4 cm. The right lobe (46%) was more affected than the left, with 33% of cases being bilateral. Two cases had multifocal lesion on similar lobe. Twelve cases had distant metastasis at presentation. More than 50% had high serum calcitonin at presentation and one case had carcinoid syndrome. We had only five cases that were known to be MEN.

CONCLUSION

The majority of our cases were sporadic with unilateral solitary nodule. Lymph node metastasis and high serum calcitonin level were frequently seen in our center.

Primary Squamous Cell Carcinoma of Thyroid: A Case Report

¹Nor Safariny Ahmad, ²Maznah Md Zain, ³Yusri Rahimi Jusoh

¹⁻³Department of Surgery, Hospital Sultanah Nur Zahirah, Kuala Terengganu, Terengganu, Malaysia

BACKGROUND AND AIMS

Primary squamous cell carcinoma (SCC) of the thyroid gland is an uncommon entity representing <1% of all primary carcinomas of the thyroid gland. It is an aggressive tumor with a poor prognosis. Overall survival usually does not exceed 6 months after the time of diagnosis. The aim of this study is to report a rare case of SCC of the thyroid gland at our center.

METHODS

A 73-year-old lady presented with anterior neck swelling associated with dysphagia for a duration of 2 months. Clinically, she was not tachypnoeic but had audible stridor. Neck examination revealed enlarged bilateral thyroid lobe, size 8 × 6 cm and hard in consistency. Initial FNAC revealed only colloid goiter and no malignant cell. Computed tomography scan showed thyroid mass involving both lobes and isthmus with bilateral cervical lymphadenopathy suggestive of malignancy with multiple bilateral lung metastases (Fig. 1). Vocal cord assessment found right vocal cord palsy likely due to recurrent laryngeal nerve infiltration. She planned for total thyroidectomy but refused operation and opted for traditional treatment. However, she came back 1 month later with airway obstruction, and emergency tracheostomy was performed, which was technically difficult due to tumor invasion. After stabilization, total thyroidectomy was successfully done with intraoperative findings of malignant looking thyroid gland infiltrating the anterior wall of trachea. She was monitored in ICU postoperatively. Unfortunately, she had septic shock secondary to pneumonia and succumbed 1 month after surgery. Histology examination of her thyroid gland showed moderately differentiated SCC (Fig. 2).

RESULTS

Primary SCC of the thyroid gland usually presents with classic triad features; (I) rapidly enlarging mass in the older patients behaving like anaplastic carcinoma, (II) may be associated with other thyroid malignancies and (III) histological features of intercellular bridges and keratin.²

Carcinoma showing thymus-like elements (CASTLE) disease of the thyroid gland, anaplastic thyroid carcinoma and metastasis from adjacent organs should be considered in the differential diagnosis.³

Squamous cell carcinoma is of unknown etiology, as the thyroid gland normally composed of follicular cells. Few theories have been suggested. First, the embryonic nest theory suggests that the squamous cells are derived from the remnants of thyroglossal duct or the epithelium of the thymus.⁴ Secondly, the metaplasia theory suggests that these cells present as a result of environmental stimuli (inflammation and Hashimoto's thyroiditis).⁵ Thirdly, the dedifferentiation theory suggests that existing papillary, follicular, medullary and anaplastic thyroid carcinoma de-differentiate into SCC.⁶

CONCLUSION

Primary SCC of the thyroid gland is a rare and aggressive tumor. Treatment with surgery, radiation therapy, and chemotherapy alone has been found ineffective in previously published similar case reports, as majority of these patients present as locally advanced cases not amenable for curative resection.

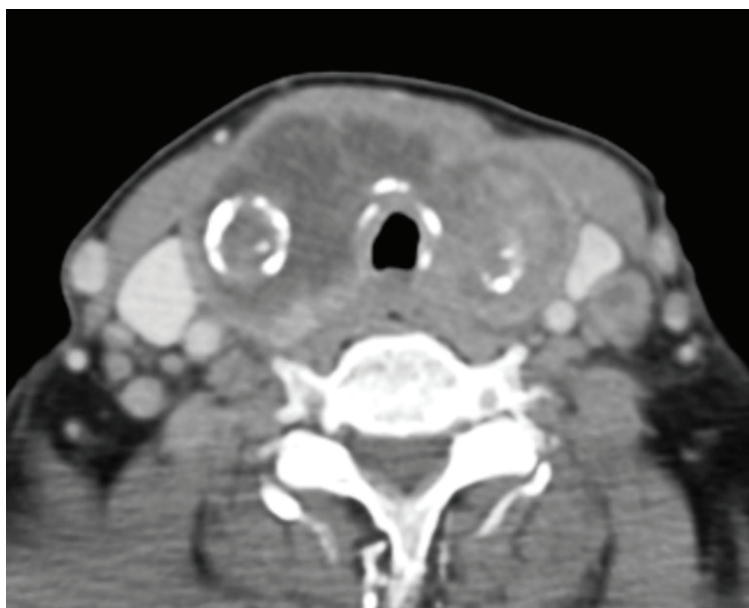


Fig. 1: Computer tomography-scan image

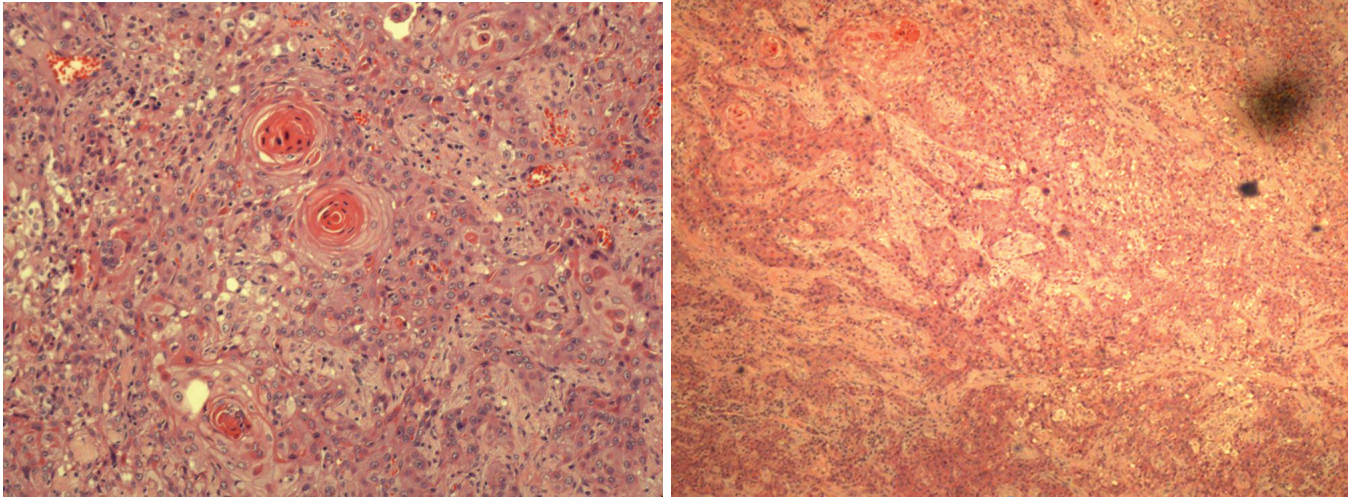


Fig. 2: Histology examination showed moderately differentiated squamous cell carcinoma. Tumor tissue is composed entirely of malignant squamous cells. These cells are cohesive and arranged in sheets, nests, cords, islands, and trabeculae pattern. These malignant cells exhibit large, pleomorphic, hyperchromatic to vesicular nuclei with large prominent eosinophilic nucleoli and abundant eosinophilic cytoplasm. Individual keratinization and intercellular bridges are noted. Tumor cell spindling can be seen. Mitotic figures are brisk including atypical form. Tumor necrosis is noted as well. This tumor is seen infiltrating the surrounding skeletal muscle bundles and destroying the thyroid gland parenchyma

The 3.5 ms Rule of Stimulation Latency in Identification of Nonrecurrent Laryngeal Nerve: Is it always True?

¹RA Rafliis, ²MW Wong, ³NA Hakim, ⁴M Rohaizak, ⁵O Suraya, ⁶EN Aina

^{1-3,6}Department of Breast and Endocrine Surgery, Hospital Kuala Lumpur, Kuala Lumpur, Malaysia

⁴Department of Breast and Endocrine Surgery, Universiti Kebangsaan Malaysia Medical Centre, Kuala Lumpur, Malaysia

⁵Department of Surgery, Universiti Teknologi MARA, Shah Alam, Malaysia

BACKGROUND AND AIMS

A nonrecurrent laryngeal nerve (NRLN) has a shorter course to enter the larynx and theoretically will have a shorter latency period on electromyography (EMG). Different types of NRLN will have different latency periods as the courses are different. A previous report has shown that latency shorter than 3.5 ms has a very high sensitivity and specificity for diagnosis of NRLN. We present two different types of NRLN with latency period longer than 3.5 ms.

METHODS

Case series.

RESULTS

Case 1

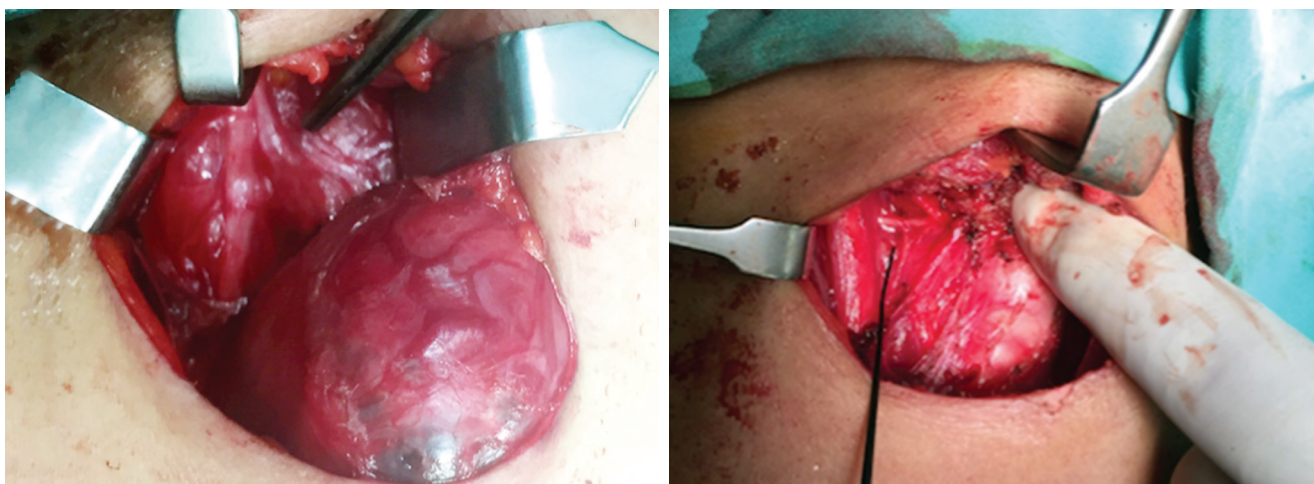
A 40-year-old lady presented with large nodular loiter and underwent total thyroidectomy. Left hemithyroidectomy was uneventful. During right hemithyroidectomy, stimulation of the right vagus (V1) nerve at the mid-cervical region was absent. The stimulation was extended superiorly on the vagus and there was a good amplitude with latency of 3.88 ms, with suspicion of a right NRLN. Further meticulous dissection confirmed type 1 NRLN.

Case 2

A 42-year-old lady presented with a right thyroid nodule and was scheduled for a right hemithyroidectomy. During dissection and stimulation of the right vagus (V1), the latency period was normal at 5.2 ms. Further dissection at the inferior pole of the gland failed to identify the recurrent laryngeal nerve (R1). The dissection and mapping performed lateral to the gland identified a type 2B NRLN, entering at the posterior aspect of the larynx.

CONCLUSION

Stimulation of the vagus nerve (V1) in the early stage of thyroidectomy is useful in identifying NRLN, by looking at either the point of stimulation or latency period. Care still should be taken during the dissection as the sensitivity varies according to the different types of NRLN.



Aggressive Familial Medullary Thyroid Carcinoma

¹Suraya Othman, ²Rohaizak Muhammad, ³Shahrin Niza Abdullah Suhaimi, ⁴Nor Faezan Abdul Rashid

^{1,4}Department of Surgery, Universiti Teknologi MARA, Shah Alam, Malaysia

^{2,3}Department of Surgery, Universiti Kebangsaan Malaysia, Bangi, Selangor, Malaysia

BACKGROUND AND AIMS

Medullary thyroid carcinoma (MTC) is a rare C-cell calcitonin-producing tumor, representing approximately 5% of all thyroid tumors. It occurs in sporadic and familial forms. The familial form of MTC accounts for 20 to 25% of cases, is usually a component of multiple endocrine neoplasia (MEN) IIA or IIB, or presents as pure familial MTC (FMTC) syndrome. Mutation of RET proto-oncogene is a well-known cause of the familial form.

METHODS

Here we present a series of aggressive FMTC involving three siblings in a family, two males and one female.

The first sibling presented with bilateral neck swelling at the age of 26 years, and total thyroidectomy with bilateral and central lymph node dissection was done in August 2014. Ultrasonography done in January 2015 showed residual disease close to the esophagus and trachea. However, recent PET-CECT showed resolved hypermetabolic lesion.

The second sibling, a 30-year-old man, presented with gradually increasing right thyroid nodule in July 2014. He underwent the same procedure as his brother. In May 2015, he had right cervical lymph node recurrence and right cervical lymph node dissection was performed.

The third sibling, a 28-year-old female, had a screening ultrasonography in August 2014, which showed three nodules in the left thyroid lobe, two solid lesions and one with coarse calcification. Fine needle aspiration biopsy was suggestive of medullary thyroid carcinoma and also had curative operation done. She is currently well with no sign of recurrence.

RESULTS

In all our patients, screening for MEN2 was negative and they refused to have genetic testing for RET proto-oncogenes.

CONCLUSION

Screening for MTC and early treatment (total thyroidectomy with central neck lymph node clearance) had nearly a 100% cure rate. However, a vigilant surveillance with calcitonin and imaging is important to detect early recurrence.

Challenges in Managing a Rare Case of Medullary Thyroid Carcinoma Associated with Carcinoid Syndrome

Sarinah Basro

Department of Breast and Endocrine Surgery, Hospital Putrajaya, Putrajaya, Malaysia

BACKGROUND AND AIMS

Medullary thyroid carcinoma (MTC) associated with carcinoid syndrome is a rare clinical occurrence.

METHODS

We report our challenges in diagnosing and managing MTC associated with carcinoid syndrome.

RESULTS

A 43-year-old Indian man presented with left thyroid nodule since 6 months. The nodule was firm in consistency and measured 4 × 3 cm. On computed tomography scan, the left thyroid nodule was heterogenous with the presence of enlarged ipsilateral cervical lymph nodes. Fine needle aspiration reported as follicular neoplasm. He underwent surgery for the possibility of follicular thyroid carcinoma. Unfortunately, after the induction he developed persistent severe tachycardia and hypotension. The operation was abandoned and he was subjected for further workout.

Further history revealed that he had diarrhea three to four times per day. He also experienced palpitation and facial flushing during defecation. His 24-hour urine catecholamine was normal. Serum calcitonin and CEA were markedly raised. However, the urine 5HIAA was normal. Guided biopsy of the thyroid nodule confirmed MTC.

The diagnosis of MTC with carcinoid syndrome was established and he was prepared for surgery again. Despite preoperative administration of octreotide for 3 days, he still developed severe tachycardia and hypotension. Fortunately, his condition improved with aggressive administration of octreotide and phenylephrine. His vital signs became more stable upon removal of the tumor, and we proceeded with bilateral modified neck dissection. His postoperative recovery was uneventful. At 3 months' follow-up his symptoms disappeared and serum calcitonin and CEA were normalized.

CONCLUSION

Like other neuroendocrine tumors, MTC may present as a carcinoid syndrome. Undiagnosed carcinoid syndrome may cause catastrophic event during surgery. A multidisciplinary teamwork is crucial for the optimal treatment strategy. An aggressive perioperative administration of octreotide enabled the surgery to be performed successfully.

Follicular Lesion/Neoplasm Scoring System: A New Clinical Score in Predicting Thyroid Cancer

¹A Adibah, ²KC Hiew, ³B Sarinah, ⁴K Normayah, ⁵A Asmiati, ⁶N Sa'at

¹⁻⁴Department of Breast and Endocrine Surgery, Hospital Putrajaya, Putrajaya, Malaysia

⁵Department of Pathology, Hospital Putrajaya, Putrajaya, Malaysia

⁶Department of Breast and Endocrine Surgery, National Clinical Research Centre, Kuala Lumpur, Malaysia

BACKGROUND AND AIMS

The diagnosis of thyroid follicular carcinoma, based on the cytology, has always been challenging. Surgery is often necessary for definitive diagnosis; therefore, preoperative decision is important to avoid second surgery. The objective of this study is to develop a new clinical score to predict thyroid cancer in patients with cytology findings of follicular lesion and follicular neoplasm.

METHODS

We retrospectively reviewed 345 patients who underwent thyroid surgery in Hospital Putrajaya from March 2001 to June 2015 who had initial fine-needle aspiration cytology (FNAC) of follicular lesion and follicular neoplasm based on the Bethesda System. The selected predictive factors that may be associated with malignancy, including suspicious clinical findings, nodule characteristics, and ultrasound findings, were analyzed. All variables for predictors were entered into a full binary logistic regression model. Variables that were statistically significant ($p < 0.05$) were chosen for Follicular Lesion/Neoplasm Scoring System (FLESS). The odds ratio calculated for chosen variables was converted into weights (points) and the optimal cut-off value of the score was calculated by means of Youden index.

RESULTS

Forty-one patients were excluded due to incomplete data. Of 301 patients, 93 (31%) had confirmed thyroid carcinoma. The FLES score comprises eight variables: Firmness (4 points), rapid growth (7 points), solitary (2 points), heterogeneity (3 points),

irregular margin (5 points), solid (3 points), calcification (4 points), and lymphadenopathy (3 points). The optimal cut-off point calculated was 10. The score predicted that a total of 82 patients (88%) who scored more than 10 points had thyroid cancer (sensitivity 0.88; specificity 0.82).

CONCLUSION

The FOTC score can assist in predicting thyroid cancer in patients with follicular neoplasm and lesion, hence reducing the rate of unnecessary surgery.

Papillary Thyroid Carcinoma occurring as Thyrotoxicosis with Right Neck Metastasis: A Case Report

¹Siew Yep Hoh, ²Wai Leong Kok, ³Shun Siang Chong, ⁴Khoon Leong Ng

¹⁻⁴Department of Endocrine Surgery, University Malaya Medical Centre, Kuala Lumpur, Malaysia

BACKGROUND AND AIMS

Papillary thyroid carcinoma (PTC) is the most common well-differentiated thyroid cancer representing 75% of all thyroid cancers. It appears as either an irregular solid, cystic mass or a nodule in normal thyroid parenchyma and typically has an indolent natural history. Most patients with PTC present with an asymptomatic palpable thyroid swelling. The presentation of PTC without any evidence of thyroid swelling is rare. Even rarer is the occurrence of functional PTC resulting in thyrotoxicosis.

METHODS

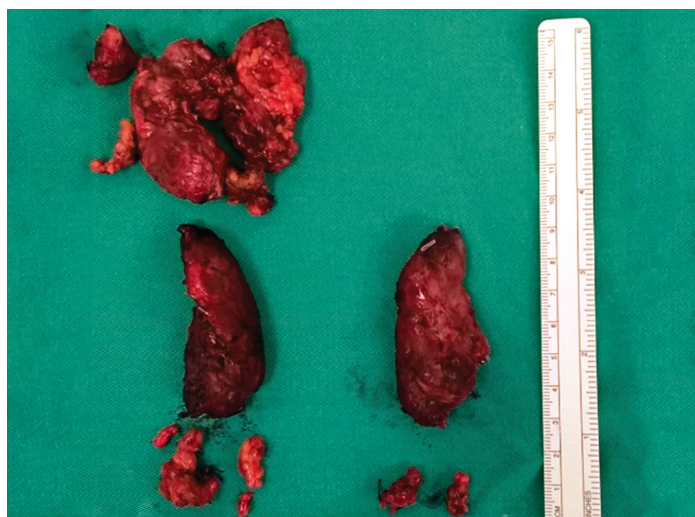
We hereby report such a case, whose initial presentation was symptomatic thyrotoxicosis with right neck lymphadenopathy. This was a 35-year-old lady with no previous history of neck radiation or significant family history of thyroid diseases. She first sought treatment for her thyrotoxicosis symptoms. Her serum TSH level was found to be low while both her T4 and T3 levels were high. Physical examination revealed enlarged right lymph nodes with no palpable thyroid lump. Subsequent neck ultrasound showed an ill-defined vascular lesion with micro-calcification at the right thyroid lobe measuring $1.3 \times 0.8 \times 1.4$ cm with several right enlarged necrotic level III and IV lymph nodes. The FNAC of the lymph node was suspicious for carcinoma, while the right thyroid lesion showed atypical cells suspicious for PTC.

RESULTS

The patient's thyrotoxicosis was controlled with carbimazole before proceeding for total thyroidectomy with selective neck dissection, right (II, III, IV, and V) and left (VI and VII). An ill-defined lesion was noted grossly in the right thyroid lobe. HPE of the right thyroid lesion suggested PTC of follicular variant. Lymph nodes of right level II to V were positive of metastatic PTC. She recovered well from her surgery and is currently ongoing treatment under oncology.

CONCLUSION

Although the probability of coexisting thyrotoxicosis and malignancy is extremely rare, a careful evaluation still needs to be carried out to exclude concurrent thyroid malignancy in such patients.



Ectopic Papillary Thyroid Carcinoma in Branchial Cyst

¹Nor Faezan Abdul Rashid, ²Rohaizak Muhammad, ³Shahrin Niza Abdullah Suhaimi, ⁴Suraya Othman

^{1,4}Department of Surgery, University Technology MARA, Shah Alam, Malaysia

^{2,3}Department of Surgery, University Kebangsaan Malaysia, Bangi, Selangor, Malaysia

BACKGROUND AND AIMS

Papillary thyroid carcinoma is the commonest well-differentiated thyroid carcinoma comprising about 80 to 85% of all thyroid malignancy. It has an excellent prognosis with survival rate of more than 95% at 25 years. However, the incidence of thyroid malignancy from this ectopic thyroid tissue is extremely rare and may manifest as a spectrum of thyroid disease. Thyroid malignancy arising from ectopic thyroid tissue is extremely rare with only few reported cases in the literature. Papillary thyroid carcinoma arising from ectopic thyroid tissue is the most commonly reported in branchial cysts. The perplexing questions about it are: is it arising *de novo* in the ectopic thyroid tissue or does it reflect a metastasis? Here we report a 43-year-old man incidentally found to have an ectopic papillary thyroid carcinoma arising from the left branchial cyst following the excision of the cyst. An examination of the neck revealed a mass arising from the left side of the neck. A preoperative computed tomography (CT) scan showed only a large branchial cyst compressing on the left thyroid gland and displacing the left carotid sheath. A total thyroidectomy with left central neck dissection was performed, which showed a focus of 22 × 12 × 9 mm tumor at the left lower lobe with three out of four left central neck nodes involvement.

Chest Wall Numbness following the Shoulder–Axilla–Breast Endothyroidectomy Method

¹Rohaizak Muhammad, ²Shahrin Niza Abdullah Suhaimi, ³Nor Faezan Abdul Rashid

^{1,2}Department of Surgery, Universiti Kebangsaan Malaysia, Bangi, Selangor, Malaysia

³Department of Surgery, Universiti Teknologi MARA, Shah Alam, Malaysia

BACKGROUND AND AIMS

In transaxillary thyroidectomy, the access is created from the axilla and breast, dissection of the skin and subcutaneous tissue from the pectoralis fascia. Among the structures that come into view are the medial supraclavicular nerve and the inferior branches of the superficial transverse cervical nerves. Damage to these nerves potentially produces altered sensation over the chest and neck. The study was aimed to look at the association between cutaneous nerve supply and altered sensation of the skin over the chest wall following transaxillary endoscopic thyroidectomy.

METHODS

This was a prospective analysis of nine patients who underwent SABET. The technique performed was transaxillary approach using three trocars at the tip of the shoulder, breast, and axilla. The dissection plane was created using diathermy hook superficial to the pectoralis fascia with the help of CO₂ insufflation at a pressure of 10 to 12 mm Hg and light illumination at 40. Endoscopic thyroidectomy was performed by splitting the muscle fibers at the lateral part of the sternothyroid muscle using ultracision.

RESULTS

Nine patients underwent endoscopic hemithyroidectomy for benign thyroid lesion. The average operating time was 90 minutes. There was no complication noted. Two patients had the nerve sacrificed, but only one patient developed chest wall numbness. One patient had the nerve preserved but developed numbness and hyperesthesia. In two patients, the nerves were not found, yet developed numbness, and in four patients, the nerves were not found and did not develop any numbness over the chest wall.

CONCLUSION

Sensation of the skin has an overlapping nerve supply. The altered sensation following endoscopic thyroidectomy may not solely be dependent on the division of the cutaneous nerve. There might be other factors involved like stretching of the skin due to gas insufflations and heat injury due to the use of energy device.

Immunohistochemical Analysis of Globo H Expression in Thyroid Malignancy

¹Shih-Ping Cheng, ²Yuan-Ching Chang, ³Chih-Long Chang, ⁴Chien-Liang Liu, ⁵Ming-Jen Chen

^{1,2,4,5}Department of Surgery, MacKay Memorial Hospital and Mackay Medical College, New Taipei, Taiwan

³Department of Obstetrics and Gynecology, MacKay Memorial Hospital and Mackay Medical College, New Taipei, Taiwan

BACKGROUND AND AIMS

Globo H is a member of the family of carbohydrate antigens on the outer membrane of some malignant epithelial cells. High levels of this tumor-associated antigen have been shown to correlate with a poor prognosis in certain cancer types. The aim of our study was to investigate the expression of Globo H in benign and malignant thyroid neoplasms.

METHODS

Globo H expression was evaluated immunohistochemically using tissue microarrays of various thyroid lesions.

RESULTS

Positive immunoreactivity was observed in 24/98 (24%) papillary, 6/80 (8%) follicular, 2/6 (33%) medullary, and 4/36 (11%) undifferentiated thyroid cancers. None of the 57 normal thyroid tissues or benign goiters had Globo H expression.

CONCLUSION

Globo H is specifically expressed in a subset of thyroid malignancy. Globo H represents a new potential therapeutic target for thyroid cancer treatment.

The Results of Completion Thyroidectomy: A Personal Series

Ali Uzunkoy

Department of General Surgery, Harran University School of Medicine, Şanlıurfa, Turkey

BACKGROUND AND AIMS

Residual thyroid tissue in patients who operated on thyroid pathology may carry a risk for recurrent or residual disease. It is reported that completion thyroidectomy increases operative complications. This study aimed to evaluate the results of completion thyroidectomy.

METHODS

The records of 35 patients who underwent completion thyroidectomy between January 2008 and December 2015 were evaluated. Demographic data, indications for completion thyroidectomy, results of pathology, and operative complications were investigated.

RESULTS

Thirty-one patients were female and four were male. Thirty-one patients were operated for thyroid carcinoma and four were operated for multinodular goiter recurrence. Histopathological examination showed remnant cancer in six patients (17.1%) after completion thyroidectomy. There was no laryngeus recurrens nerve paralysis. Temporary hypoparathyroidism was observed in two (5.7%) patients. There was no mortality in this series.

CONCLUSION

The frequency of complications of completion thyroidectomy is not higher than that of primary total thyroidectomy. As a result, completion thyroidectomy can be safely performed by experienced surgeons with low morbidity.

Effect of Intraoperative Nerve Monitoring on Voice Quality during Thyroid Surgery

¹Erdinc Cekic, ²Turgut Donmez, ³Sinan Uzman, ⁴Sina Ferahman, ⁵Enes Arikan, ⁶Murat Özcan

¹Department of Otolaryngology Head Neck Surgery, Lutfiye Nuri Burat State Hospital, Istanbul, Turkey

²Department of General Surgery, Lutfiye Nuri Burat State Hospital, Istanbul, Turkey

³Department of Anesthesiology, Haseki Training and Research Hospital, Istanbul, Turkey

⁴⁻⁶Department of General Surgery, Istanbul University Cerrahpasa Faculty of Medicine, Istanbul, Turkey

BACKGROUND AND AIMS

In this study we aimed to investigate the voice quality during thyroid surgery under intraoperative neuromonitorization.

METHODS

Thirty-two consecutive total thyroidectomy patients who were operated under intraoperative neuromonitorization were included in this study. During surgery, all recurrent laryngeal nerves (RLN) were stimulated with 1mA, and EMG responses were recorded for both sides before and after the surgical excision. All patients were evaluated for subjective and objective acoustic analysis preoperatively and postoperatively at 3rd week. For subjective analysis, all patients were evaluated with the Turkish version of Voice Handicap Index-10 (VHI-10) pre- and postoperatively. For objective acoustic analysis, all patients' voices were recorded and analyzed pre- and postoperatively with a computer program. Preoperative and postoperative jitter and shimmer values were calculated and compared. Flexible fiberoptic laryngoscopic examinations were performed pre- and postoperatively at an otolaryngology clinic.

RESULTS

Amplitudes of EMG responses were (min-max)/median 510 (124–1550) mV for right-side before excision and 510 (117–1660) for right-side post excision. Amplitudes of EMG responses were 406 (83–1150) for left side before excision and 597.5 (151–1283) mV for left side post excision. The EMG amplitudes were stable for right side, but there was a light increase in the left side.

CONCLUSION

All surgical procedures were done successfully, but because the postoperative control and acoustic analysis at 3rd week were not completed yet, our results were not finished. Also we had three patients with unilateral vocal cord paralysis in case of normal post-excision EMG amplitudes. We think that these were transient paralysis and we wanted to wait for the 3rd month control.

Double Morbidity after Sutureless Thyroidectomy with Energy-based Devices: Cerrahpasa Experience

¹Akif Enes Arikan, ²Serkan Teksoz, ³Selen Soylu, ⁴Murat Ozcan, ⁵Recep Ozgultekin, ⁶Yusuf Bukey, ⁷Ates Ozyegin

¹⁻⁷Department of General Surgery, Istanbul University, Cerrahpasa Medical Faculty, Istanbul, Turkey

BACKGROUND AND AIMS

With the development of energy-based devices (EBD), the operation time has shortened but it has brought its own risks. Due to the thermal spread of EBD, injury to the recurrent laryngeal nerve and parathyroid gland is possible, and sealing of vessels, especially lymphatics, does not completely occur from time to time. However, EBD are still safe and effective. This study investigates the co-occurrence of two morbidity cases after sutureless thyroidectomy.

METHODS

Patients who underwent sutureless total thyroidectomy between January 2014 and October 2015 were analyzed retrospectively. Patients with a history of previous thyroidectomy or parathyroidectomy (incidental or intentional) and hemithyroidectomy were excluded. Vocal cord palsy (VCP) was evaluated with preoperative and postoperative laryngoscopic examination. Hypocalcemia was an accepted symptom when patients complained for perioral of finger numbness, tetany. Hematoma/seroma is defined as a visible or fluctuating swelling in the operation area or ecchymosis. Dual combination (hypocalcemia + VCP, hypocalcemia + hematoma/seroma, VCP + hematoma/seroma) of three morbidities was evaluated. Distribution of morbidities among used EBD was not in equal variance except VCP.

RESULTS

There were 514 patients who underwent thyroidectomy. In 10 (1.9%) symptomatic hypocalcemia, in 57 (11.1%) VCP, and in 12 (2.3%) hematoma/seroma were seen. Thirty-four (59.7%) of the 57 VCP patients were asymptomatic. Detailed results are given in Table 1. All morbidities that occurred were temporary. Except hypocalcemia, there was no difference among used EBD.

CONCLUSION

EBDs are safe and feasible even in double morbidity with acceptable rates similar to that noted in the literature.

Table 1: Distribution of morbidities after sutureless thyroidectomy

	<i>Harmonic Focus® (n = 289)</i>	<i>Ligasure™ LF1212 (n = 225)</i>	<i>Total (n = 514)</i>	<i>p-value</i>
Vocal cord palsy (VCP)	32 (11.1%)	25 (11.1%)	57 (11.1%)	0.989*
Hypocalcemia (Hc)	2 (0.7%)	8 (3.6%)	10 (1.9%)	0.025 [‡]
Hematoma/seroma (HS)	4 (1.4%)	8 (3.6%)	12 (2.3%)	0.142 [‡]
VCP + Hc	0	2 (0.9%)	2 (0.4%)	0.191 [‡]
VCP + HS	0	1 (0.4%)	1 (0.2%)	0.438 [‡]
HS + Hc	0	0	0	N/A

*Pearson's chi-square; [‡]Fisher's exact test; N/A: Not available; p value denoted in bold is statistically significant

To use or Not to use Drain in Sutureless Thyroidectomy: Cerrahpasa Experience

¹Selen Soylu, ²Serkan Teksoz, ³Yusuf Bukey, ⁴Akif Enes Arikan, ⁵Murat Ozcan, ⁶Recep Ozgultekin, ⁷Ates Ozyegin

¹⁻⁷Department of General Surgery, Istanbul University, Cerrahpasa Medical Faculty, Istanbul, Turkey

BACKGROUND AND AIMS

Thyroid surgery is one of the most performed surgical procedures in the world. Thyroid gland is one of the most vascular organs in the human body. It needs a careful surgical technique and hemostasis. By the use of energy-based devices, the time for hemostasis is reduced. For postoperative follow-up of hemostasis, the surgeon either puts or does not put a drain to the surgical zone. However, whether routine use of drain is required or not after sutureless thyroidectomy is an issue in an era of minimally invasive surgery.

METHODS

Patients who underwent sutureless total thyroidectomy between January 2014 and October 2015 were analyzed retrospectively. Patients with a history of previous thyroidectomy or parathyroidectomy or those who underwent any simultaneous operation are excluded. Complications related to or detectable with drain such as seroma and hematoma were compared for groups in which drains were or were not used. There was no equal variance in the distribution of groups, so Fisher's exact test was used for the evaluation of p value.

RESULTS

There were 514 patients who underwent sutureless thyroidectomy. In 105 of the patients, drains were used and in 409 they were not used. In one patient seroma was seen in the drain-used group and in no patient in the drain-not-used group ($p=0.204$). Hematoma was observed in six patients in the drain-not-used group and five patients in the drain-used group ($p=0.053$).

CONCLUSION

The use of drains has no additional value for follow-up of complications like seroma or hematoma after sutureless thyroidectomy.

The Effect of Surgeon-performed Intraoperative Ultrasonography on the Length and Localization of the Incision for Total Thyroidectomy

¹Güldeniz Karadeniz Cakmak, ²Ali Ugur Emre, ³Selcuk Ozkan, ⁴Ali Gencoglu, ⁵Eray Seven

¹⁻⁵Department of General Surgery, Bulent Ecevit University The School of Medicine, Zonguldak, Turkey

BACKGROUND AND AIMS

The incision used for total thyroidectomy has evolved over the last century. The philosophy is to leave the least scar ever. Intraoperative ultrasound (US) in the hands of a surgeon is an efficient device for real-time visualization of the entire gland associated with the advantage of designing incisions according to the position of the superior poles relative to the extent of the disease. The aim of this study was to assess the effect of intraoperative US on the length and localization of the incision.

METHODS

Forty-five consecutive patients scheduled for total thyroidectomy were prospectively evaluated. The exclusion criteria included prior neck surgery and diagnosed malignancy. In the theater, after positioning, the surgeon decided and marked the length of

the incision according to her personal judgement with respect to palpable landmarks. This was followed by surgeon-performed US of the region and designing incision according to real-time sonographic data of the diseased gland.

RESULTS

Ultrasound guidance was found to alter either the length or the localization of the incision in 73% (33/45) of the patients. The length of the incisions was found to be reduced with a mean diameter of 22 ± 5 mm after sonographic evaluation. Moreover, the comparison between predetermined incision localization on the vertical plane revealed a cranial shift of mean 15 ± 0.4 mm following US scan. The localization of the incision was found to be strongly correlated with superior pole border, whereas the biometric factors associated with a significant difference in length were determined to be obesity, male gender, thyroid volume, and neck circumference.

CONCLUSION

In general, thyroid volume has been one of the most significant factors to predict the length of thyroidectomy incisions. Nevertheless, surgeon-performed US guidance after patient positioning resulted in a considerable change in both the length and the localization of incisions in the presented study.

Primary Lymphoma of the Thyroid: A Case Report and Review of the Literature

¹Jain Prakash, ²Hu Shulin Jesse, ³Cheah Wei Keat

¹⁻³Department of General Surgery, Ng Teng Fong General Hospital, Singapore

BACKGROUND AND AIMS

Primary thyroid lymphoma is a rare presentation of extranodal lymphomas, accounting for only 1 to 2% of such disease, most commonly seen with a background of Hashimoto's thyroiditis. The most common presentation is that of rapidly enlarging neck swelling causing compressive airway symptoms. It is often difficult to distinguish it from anaplastic thyroid cancer.

METHODS

We present a 67-year-old Malay male with a 2-week history of rapidly enlarging thyroid swelling and associated compressive symptoms. Imaging of the neck showed a large left lobe of thyroid with tracheal deviation to the opposite side and left carotid displacement laterally with no neck lymphadenopathy or retrosternal extension. Fine needle aspiration cytology revealed sheets of lymphocytes, and core needle biopsy confirmed the diagnosis of diffuse large B cell lymphoma (DLBCL).

Immunohistochemistry and additional staging workup showed stage II disease with no bone marrow involvement.

RESULTS

He underwent immunochemotherapy with R-CEOP with good response and significant reduction in symptoms without the need for surgical debulking.

CONCLUSION

Primary thyroid lymphoma is a rare disease. The role for surgery has diminished with improvements in diagnostic techniques and immunochemotherapy. It is possible to treat even acute compressive symptoms without significant airway compromise by nonsurgical methods with good outcomes. The key is a high index of suspicion, rapid diagnosis, and early initiation of combined modality therapy. Surgical intervention should be restricted to excisional biopsy if core needle is not possible, for diagnosis, or in cases of *in extremis* airway compromise or rarely in debulking extensive disease.

“My Ear Hurts!” – Microbial Inflammatory Thyroiditis: A Case Report and Review of the Literature

¹Jain Prakash, ²Hu Shulin Jesse, ³Cheah Wei Keat

¹⁻³Department of General Surgery, Ng Teng Fong General Hospital, Singapore

BACKGROUND AND AIMS

Microbial inflammatory thyroiditis, also known as acute suppurative thyroiditis, is a rare subtype of thyroiditis most often caused by the presence of Gram-positive bacteria in the thyroid gland. This disorder is rare because the thyroid gland has inherent resistance to infection. It can sometimes be confused with anaplastic carcinoma thyroid.

METHODS

We present a 28-year-old Bangladeshi male with a 10-day history of pain radiating to the left ear and rapidly increasing swelling of the thyroid gland, more on the left than on the right. This was associated with fever and dysphagia, but no airway compromise.

On examination he had anterior neck dermal erythema and tender left lobe of thyroid. He was febrile and had tachycardia, leukocytosis, and elevated CRP. His thyroid function was normal. Fine needle aspiration cytology revealed features of suppuration with neutrophil predominance. Ultrasound and CT neck revealed an enlarged left lobe of thyroid with no cystic changes, pyriform sinus fistula, or intrathyroidal collections. Thyroid aspirate culture grew *Staphylococcus aureus*.

RESULTS

He received parenteral broad-spectrum antibiotics and antiinflammatory agents with good clinical response. He was discharged with oral antibiotic therapy and was afebrile and pain free, with a reduced thyroid swelling.

CONCLUSION

Microbial inflammatory thyroiditis is a rare condition that can present with acute sepsis and compressive symptoms. Emergency surgical therapy is required if there is significant airway compromise. Patients with abscesses require surgical drainage and, sometimes, a thyroid lobectomy. Heat, appropriate antibiotic therapy, and antiinflammatory agents provide symptomatic relief; steroids may offer additional benefit. The disease is usually self-limited, lasting weeks to months, and patients can have complete response with no thyroid dysfunction.

Selective Use of Calcium and Calcitriol after Total Thyroidectomy reduces the Rate of Hypocalcemia, Length of Stay, and Readmission

¹Jake Osborne, ²Anita Skandarajah, ³Minon Tan, ⁴Alexandra Gorelik, ⁵Daniel Hng, ⁶Julie Miller

^{1,5,6}Department of Endocrine Surgery, The Royal Melbourne Hospital, Parkville, Victoria, Australia

^{2,3}Department of Surgery, The University of Melbourne, Parkville, Victoria, Australia

⁴Melbourne EpiCentre, The University of Melbourne, Parkville, Victoria, Australia

BACKGROUND AND AIMS

Hypocalcemia is a well-described complication after total thyroidectomy. The routine use of calcium and calcitriol supplementation to reduce the rates of hypocalcemia after total thyroidectomy remains controversial. The aim of this study was to assess the outcome of a post-thyroidectomy calcium/calcitriol supplementation protocol on the rates of hypocalcemia, the hospital length of stay (LOS), and readmission for hypocalcemia.

METHODS

In 2009 we introduced a protocol to perform a parathyroid hormone (PTH) level in the recovery room for all patients undergoing total or completion thyroidectomy in a public hospital endocrine surgery unit. Patients with PTH < 1.6 pmol/L were put on calcium and calcitriol on the day of surgery. Group A (pre-protocol) included patients from 2005 to 2008, and group B (post-protocol) from 2010 to 2014. Medical records were retrospectively reviewed. Serum PTH in recovery, corrected calcium 1-day postoperatively, and prescription of calcium and calcitriol supplements were recorded. Primary endpoints were hypocalcemia, defined as corrected calcium < 2.0 mmol/L, hospital LOS, and readmission for hypocalcemia.

RESULTS

There were 131 patients in group A and 194 patients in group B. A total of 66.3% of group B patients had low PTH in the recovery room and were prescribed calcium and calcitriol supplementation. When comparing Groups A and B, the mean corrected calcium 1 day postoperatively increased from 2.15 to 2.28 mmol/L ($p < 0.001$). Hypocalcemia decreased from 20.8% in group A to 4.2% in group B ($p < 0.001$). Median LOS decreased from 2 days to 1 day in groups A and B respectively. The readmission rate for hypocalcemia decreased from 6.1 to 0.5% ($p = 0.004$).

CONCLUSION

Calcium and calcitriol supplementation for patients with low recovery room PTH reduces the rates of hypocalcemia, LOS, and readmission for hypocalcemia.

Clinical Features of Papillary Thyroid Carcinoma and Exploration of the Extent of Surgical Resection

¹Peisong Wang, ²Shuai Xue, ³Jia Liu, ⁴Guang Chen, ⁵Gui-min Wang

¹⁻⁵Department of Thyroid Surgery, The First Hospital of Jilin University, Changchun, Jilin, China

BACKGROUND AND AIMS

To investigate the biological characteristics of papillary thyroid carcinoma (PTC) and to discuss its surgical method.

METHODS

A total of 221 patients of PTC underwent total thyroidectomy and conventional central lymph node (CLN) dissection from July 2009 to February 2011 at our hospital. Their clinical data were retrospectively analyzed.

RESULTS

There was no permanent injury of recurrent laryngeal nerve. Only one patient had permanent hypoparathyroidism. Postoperative pathological results showed that bilateral cancer was found in 69 cases (31.2%). Thyroid membrane invasion was found in 143 cases (64.7%), of which the invasion rate of bilateral cancer was 68.1% (47/69). Conventional central lymph node metastasis (CLNM) was found in 95 cases (43%), of which the CLNM rate of bilateral cancer was 46.4% (32/69), the CLNM rate of unilateral cancer was 41.5% (63/152), and the CLNM rate of thyroid membrane invasion was 49.7% (71/143). Thyroid membrane invasion or CLNM rate in all cases was 75.6% (167/221). There were 42 cases that were found with suspicious unilateral cancer before surgery but proved to have bilateral PTC by postoperative pathological diagnosis (60.9%).

CONCLUSION

Most PTC often occurs bilaterally and the ratio of CLNM is very high. We suggest that most patients with PTC should undergo total thyroidectomy, conventional CLN dissection, or a combination of postoperative endocrine suppression therapy and selective I131 treatment.

Follicular Thyroid Carcinoma combined with Squamous Cell Thyroid Carcinoma (One Case Report)

¹Peisong Wang, ²Shuai Xue, ³Jia Liu, ⁴Guang Chen

¹⁻⁴Department of Thyroid Surgery, The First Hospital of Jilin University, Changchun, Jilin, China

BACKGROUND AND AIMS

Follicular thyroid carcinoma combined with squamous cell thyroid carcinoma is rarely reported in the literature.

METHODS

A 60-year-old female patient was diagnosed with follicular thyroid carcinoma combined with squamous cell thyroid carcinoma in our department in October 2008.

RESULTS

Without squamous epithelial cell in normal thyroid tissue, the origin of squamous cell carcinoma in thyroid is controversial. Reasons mainly lie in the following: (1) During embryonic period, branchial arch epithelial nests or thyroid hyoid tube and gills embryonic epithelial cell become malignant, or (2) it may be caused due to metaplasia and transformation of thyroid follicular epithelial cell. Its diagnosis mainly depends on pathology. The patient underwent total thyroidectomy, supplemented by levothyroxine suppression therapy, I131 treatment, radiotherapy, and chemotherapy.

CONCLUSION

Four years later, she eventually died of tumor recurrence in April 2013.

Analysis of Ultrasonic and Pathological Features of Papillary Thyroid Carcinoma

¹Peisong Wang, ²Shuai Xue, ³Guang Chen

¹⁻³Department of Thyroid Surgery, The First Hospital of Jilin University, Changchun, Jilin, China

BACKGROUND AND AIMS

To improve the ultrasonic differential diagnosis of thyroid nodule through analyzing pathological and ultrasonic features of papillary thyroid carcinoma.

METHODS

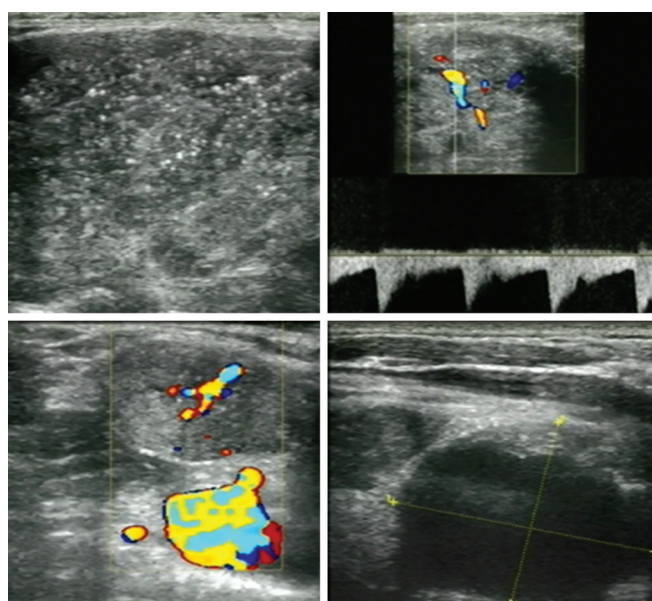
Records of 173 cases of papillary thyroid carcinoma were analyzed retrospectively in terms of preoperative ultrasonic manifestation, lesion size, echo, boundary, calcification, blood supply, lymph node metastasis, accompanying diseases, etc.

RESULTS

Of the 173 papillary thyroid carcinoma cases, the number of cancer nodule was 203. There was no statistical difference between papillary thyroid carcinoma lesion and papillary thyroid microcarcinoma lesion in terms of low echo and ill-defined borders ($p > 0.05$). The former was higher than the latter in blood flow speed, microcalcification rate, and preoperative ultrasonic diagnosis rate ($p > 0.01$, > 0.05 , and > 0.01 respectively). The multifocality rate for the 173 cases with papillary thyroid carcinoma was 33.53% (58/173). There was no statistical difference between papillary thyroid carcinoma and papillary thyroid microcarcinoma in cancer lesion ($p > 0.05$), while the former had a higher rate of lymph node metastasis than the latter ($p > 0.01$). Preoperative diagnosis rate was higher in papillary thyroid microcarcinoma cases without other thyroid diseases than in cases with other thyroid diseases ($p > 0.05$). No statistical difference of preoperative diagnosis rate was seen between papillary thyroid carcinoma patients with other thyroid diseases and those without other thyroid diseases ($p > 0.05$).

CONCLUSION

The overall evaluation of thyroid nodule diameter, boundary, echo, small calcification, lymph node metastasis, blood supply, accompanying diseases, and so on can improve the diagnosis of primary papillary thyroid carcinoma.



Endoscopic Thyroidectomy along with Bilateral Central Neck Dissection (ETBC) increases the Risk of Transient Hypoparathyroidism for Patients with Thyroid Carcinoma

¹Dapeng Xiang, ²Zhiyu Li

^{1,2}Department of General Surgery, Second Affiliated Hospital, Zhe Jiang University College of Medicine, Hangzhou, China

BACKGROUND AND AIMS

Increasing number of patients with thyroid carcinoma, especially young female patients, prefer to choose endoscopic thyroidectomy with bilateral central neck dissection (ETBC) for perfect cosmetic effects. However, the incidence of hypoparathyroidism after ETBC has not been well studied.

METHODS

A total of 96 patients with papillary thyroid carcinoma were enrolled. All patients, including 49 ETBC and 47 open surgery patients, underwent total thyroidectomy with bilateral central neck dissection (CND). Some patients also underwent lateral neck dissection simultaneously. The incidence of hypoparathyroidism and parathyroid hormone (PTH) level was examined.

RESULTS

Patients in the open surgery group had more advanced lesions, with larger tumor ($p = 0.000$), older age ($p = 0.000$), and more serious local involvement. The dissection extent of the open group was significantly larger than that of the ETBC group ($p = 0.006$). In contrast, the ETBC group with less dissection extent showed a significantly higher incidence of transient hypoparathyroidism

than the open group (59.2 vs 29.6%, $p=0.004$). The average PTH decline in the ETBC group was significantly higher than that of the open group on postoperative day 1 (POD1) (32.1 vs 21.6 pg/ml, $p=0.010$). Moreover, more patients' PTH level dropped below the minimum level of 15 pg/ml in the ETBC group on POD1 ($p=0.001$). Furthermore, the ETBC group had a significantly higher portion of patients with a PTH < 10 pg/ml on POD1 ($p=0.001$). One patient in the ETBC group developed permanent hypoparathyroidism. Autotransplantation and inadvertent removal rates of parathyroid did not differ between the two groups.

CONCLUSION

Although generally considered a safe method for patients with thyroid carcinoma, ETBC may increase the risk of transient hypoparathyroidism compared with conventional open surgery. It should be chosen and performed with caution, especially when heavy lymph node involvement is detected.

Table 1: Demographics and clinical characteristics

Characteristics	ETBC (%)	Open surgery	p-value (%)
Sex (female/male)	49/49 (100)	41/47 (87.2)	0.010
Age (year) ^a	34.2 ± 7	46.9 ± 13.3	0.000
Primary tumor			
Size, diameter (cm) ^a	0.77 ± 0.42	1.24 ± 0.79	0.000
Multifocality	26/49 (53.1)	37/47 (78.7)	0.008
Extracapsular invasion	16/49 (32.7)	17/47 (36.2)	0.717
Extrathyroid extension	3/49 (6.1)	8/47 (17)	0.094
Nodal involvement			
Central compartment	20/49 (40.8)	40/47 (85.1)	0.024
Lateral compartment	6/49 (12.2)	17/47 (36.2)	0.005
Extent of surgery			
TT + CND ^b + LND ^c	6/49 (12.2)	17/47 (36.2)	0.006
No of dissected nodes ^a	10.9 ± 6.5	11.1 ± 8.1	0.769
Mean operation time (min) ^a	187 ± 51	135 ± 53	0.000
Postoperative bleeding	0/49 (0)	0/47 (0)	
Chyle leakage	1/49 (2)	1/47 (2)	0.976
Transient vocal palsy	2/49 (41)	0/47 (2)	0.162

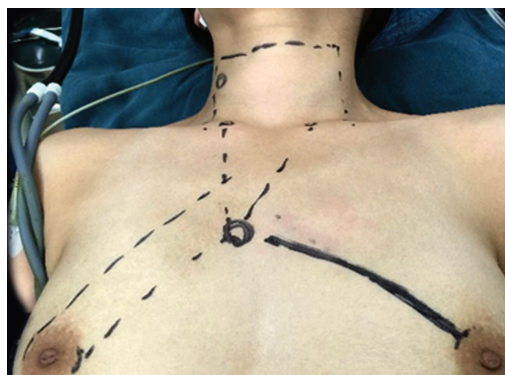^aMean ± SO; ^bCND: Central neck dissection; ^cLND: Lateral neck dissection

Table 2: Hypoparathyroidism incidence and PTH decline

Variables	ETBC(%)	Open surgery (%)	p-value
Preoperative PTH (pg/ml)	48.4 ± 17.9	48.8 ± 14.9	0.578
Δ PTH (PTH decline)	32.1 ± 18.2	21.6 ± 3.1	0.010
Postoperative PTH < 15	30/49 (61.2)	13/47 (27.7)	0.001
Postoperative PTH < 10	23/49 (46.9)	7/47 (14.9)	0.001
Transient hypoparathyroidism	29/49 (59.2)	14/47 (29.8)	0.004
Permanent hypoparathyroidism	1/49 (2)	0/47 (0)	0.325
Inadvertent removal of parathyroid ^a	4/49 (8.2)	3/47 (6.4)	0.737
Autotransplantation of parathyroid ^b	15/49 (30.6)	11/47 (23.4)	0.427

^aNumber of patients who had parathyroid glands removed inadvertently. Inadvertent removed glands were found in the specimen by final pathology. Therefore, an autotransplantation was not possible.

^bNumber of patients who had autotransplantation of parathyroid.



Familial Thyroid Nonmedullary Microcarcinoma is More Invasive than Sporadic Cases: A Retrospective Analysis

¹Zengguang Liu, ²Guang Chen, ³Chang Su, ⁴Jiang Ren, ⁵Zhongying Miao, ⁶Weidong Zhou, ⁷Guimin Wang

¹⁻⁷Department of Thyroid Surgery, The First Hospital of Jilin University, Changchun, Jilin, China

BACKGROUND AND AIMS

To review the clinical and pathological features of familial thyroid papillary microcarcinoma and to investigate the clinical treatment of familial thyroid papillary microcarcinoma.

METHODS

A retrospective analysis of the clinical characteristics of 76 cases with familial thyroid nonmedullary microcarcinoma in 44 families was done, and 73 cases who underwent total thyroid resection out of the 76 cases (group A) were compared with 794 patients who underwent the same operation by the same surgeon in the same period and hospital (group B) out of 1,174 patients with sporadic thyroid carcinoma, of which 904 cases were of thyroid microcarcinoma. At the same time, 35 cases of 12 families with total thyroidectomy by the same surgeon from January 2009 to January 2013 (group C) were compared with group A.

RESULTS

The pathological multifocal carcinoma occurrence rate and central lymph node metastasis rate of group A are higher than those of group B, and the difference is statistically significant ($p=0.035$, 0.037 , and 0.05); the remaining difference is not statistically significant; the central lymph node metastasis of group A is lower than that of group C, and the difference is statistically significant ($p=0.047$, and <0.05 respectively); the remaining difference is not statistically significant.

CONCLUSION

The high multifocal carcinoma occurrence rate and central lymph node metastasis rate of familial thyroid microcarcinoma remind us that familial thyroid microcarcinoma is more invasive than sporadic thyroid microcarcinoma. Therefore, for familial thyroid microcarcinoma, operation range selection should be more active; we suggested that the thyroid total resection and central neck lymph node dissection be used as the routine operation. Screening for familial thyroid cancer can reduce the central lymph node metastasis rate, so more attention should be paid to screening for familial thyroid cancer.

Graves' Disease Associated with Papillary Thyroid Microcarcinoma: A Retrospective Case-control Analysis

¹Guang Chen, ²Shuai Xue, ³Jia Liu, ⁴Peisong Wang, ⁵Zhe Han, ⁶Shuo Wang

¹⁻⁶Department of Thyroid Surgery, The First Hospital of Jilin University, Changchun, Jilin, China

BACKGROUND AND AIMS

Combined with the domestic and foreign literatures, we did a retrospective analysis to investigate the clinical characteristics, diagnosis, and treatment methods for Graves' disease associated with papillary thyroid microcarcinoma.

METHODS

The study subjects were 32 patients all treated at the Department of Thyroid Surgery, The First Hospital of the Jilin University, Changchun, China, from June 2008 to June 2013. At the same time, 32 papillary thyroid microcarcinoma cases with normal thyroid function were randomly selected by a random number table method from the same period as control.

RESULTS

The experimental group of 32 patients were 24 to 71 years old. There were 3 males and 29 females, and the male-to-female ratio was 1:9.7. Fifteen cases in the experimental group of central lymph node metastasis were positive, 17 cases were negative, while in the control group 7 cases were positive and 25 cases were negative. In the experimental group, the mean value of positive lymph nodes was 3 ± 2.88 , while in the control group it was 1.71 ± 1.25 . The ratio of positive lymph node in the metastasis group (the number of positive lymph nodes/the total number of lymph nodes, and the total number of central lymph nodes was ≥ 3) was $50.34 \pm 27.09\%$, while in the control group it was $33.5 \pm 30.79\%$. For three values above central lymph node metastasis, through statistical analysis, the value in the experimental group was higher than in the control group ($p=0.035$, 0.039 , and 0.018).

CONCLUSION

Graves' disease associated with papillary thyroid microcarcinoma was more prone to lymph node metastasis; positive lymph node metastasis number and its metastasis ratio were higher. In order to prevent the postoperative recurrence of Graves' disease and thyroid carcinoma, total thyroidectomy plus central lymph node dissection should be the ideal operation method.

Central Lymph Node Metastasis as a Predictor for Lateral Lymph Node Metastasis in clinically Node-negative T3 and T4 Papillary Thyroid Carcinoma

¹Guang Chen, ²Shuai Xue, ³Jia Liu, ⁴Peisong Wang, ⁵Zhe Han, ⁶Shuo Wang

¹⁻⁶Department of Thyroid Surgery, The First Hospital of Jilin University, Changchun, Jilin, China

BACKGROUND AND AIMS

The objective of the study was to assess the patterns of lateral lymph node metastasis (LLNM) and evaluate the impact of central lymph node metastasis (CLNM) on lymph node resection at levels II–V in clinically node-negative (cN0) T3 and T4 PTC patients.

METHODS

We retrospectively reviewed 151 patients with PTC who underwent total thyroidectomy plus bilateral central lymph node dissection (CLND) and unilateral lymph node dissection (LLND). The LLNM risk factors and the pattern of LLNM in PTC were studied using multivariate analysis.

RESULTS

(1) Central lymph node metastasis was a risk factor for LLNM (odds ratio of 2.776). (2) The numbers of involved central lymph nodes were positively correlated with the incidence of LLNM and the number of LLNM involved regions. (3) Within the lateral cervical lymph node chain, level IV nodes were consistently the most frequently involved.

CONCLUSION

The number of central lymph nodes involved correlated with higher LLNM; total thyroidectomy plus bilateral CLND should be first considered for the T3 and T4 PTC patients in whom we recommended modified radical cervical lymph nodes dissection to remove the ipsilateral level II–V lymph nodes.

Analysis of Ultrasonic Characteristics of Hashimoto's Thyroiditis benign Nodules and Its Relationship with Serum TSH

¹Guang Chen, ²Shuai Xue, ³Jia Liu, ⁴Peisong Wang, ⁵Zhe Han, ⁶Shuo Wang

¹⁻⁶Department of Thyroid Surgery, The First Hospital of Jilin University, Changchun, Jilin, China

BACKGROUND AND AIMS

To discuss the relationship between ultrasonic characteristics of Hashimoto's thyroiditis benign nodules (HTBN) and serum TSH, aimed to guide the clinical diagnosis and treatment.

METHODS

We summarized 117 cases from January 2012 to December 2013 in our department after thyroid fine needle aspiration for the diagnosis of HTBN according to the inclusion criteria. A total of 32 cases were misdiagnosed by ultrasound as malignant nodules. Using a random number table method, according to the 1:1 principle, we selected the ultrasonic diagnosis of 32 cases of the patients in the control group. Comparison was done between the two groups and the relationship with serum TSH was analyzed.

RESULTS

In the ultrasound misdiagnosis group, the serum TSH value was 6.32 ± 1.11 uIU/ml, and in the ultrasound diagnosis group it was 2.08 ± 1.23 uIU/ml ($p=0.047$ and <0.05 respectively). In comparison with the increase in serum TSH concentration, the proportion of HTBN increased gradually ($p=0.002$). In the ultrasound misdiagnosis group, low echo, irregular shape, irregular boundary, inhomogeneous echo, and aspect ratio more than 1 were higher than the ultrasound diagnosis group; the p-values were 0.000, 0.000, 0.000, 0.026, and 0.011. In the ultrasound misdiagnosis group, nodular echo, shape, and boundary characteristics were higher than in the ultrasound diagnosis group; p-values were 0.037, 0.026, and 0.021.

CONCLUSION

In the background of Hashimoto's thyroiditis, the ultrasound characteristics of benign nodules are of great uncertainty. Especially for patients with elevated serum TSH, ultrasound characteristics in nodular echo, shape, and boundary does not have great reference value. Differential diagnosis of benign and malignant nodules in Hashimoto's thyroiditis background should be made according to the patient's condition, using various individual diagnostic techniques. In this way we can improve the accuracy of diagnosis and reduce the clinical misdiagnosis and mistreatment.

Application of the Principle of Continuous En-bloc Resection in Thyroidectomy for Papillary Thyroid Carcinoma

¹Guimin Wang, ²Chang Su, ³Jiang Ren, ⁴Zengguang Liu, ⁵Zhongying Miao, ⁶Weidong Zhou

¹⁻⁶Department of Thyroid Surgery, The First Hospital of Jilin University, Changchun, Jilin, China

BACKGROUND AND AIMS

To explore the application effects between en-bloc resection and piecemeal resection of papillary thyroid carcinoma (PTC) in thyroidectomy.

METHODS

We made a retrospective analysis in this clinical study. During the period between October 2014 and October 2015, 100 cases were diagnosed as PTC after fine needle aspiration (FNA) who accepted thyroidectomy for PTC in the same surgery group. The former 40 cases underwent piecemeal central lymph node dissection (CLND) clearance after ipsilateral lobectomy plus isthmusectomy (piecemeal resection group). The latter 60 cases underwent continuous en-bloc resection with ipsilateral lobectomy plus isthmusectomy and CLND at one time (en-bloc resection). The operative time, the number of dissected central lymph nodes, and the postoperative complications were compared.

RESULTS

All the procedures were accomplished successfully. The transient parathyroid function decline and transient hoarseness were different between the two groups. The occurrence of the transient parathyroid function decline and transient hoarseness in en-bloc resection group compared with the piecemeal resection group significantly decreased ($p=0.048$ and 0.041), which was a statistically significant difference. There was no difference in the number of dissected central lymph nodes and the operative time between the two groups ($p>0.05$). There was no recurrent laryngeal nerve (RLN) everlasting injury and hypocalcemia. The hoarseness recovered gradually within postoperative 8 weeks. All the patients were followed up for 2 to 14 months (mean: 8 months). Neither locoregional recurrence nor distant metastasis was observed.

CONCLUSION

Preliminary impression emerging from this study seems to suggest that en-bloc resection conforms more to non-tumor principle than piecemeal resection, and can be safely applied in the operation for PTC by reducing the occurrence of postoperative complications, without increasing the operative time and affecting the number of dissected central lymph nodes.

Analysis of Pattern and Risk Factors of Central Lymph Node Metastasis in Papillary Thyroid Carcinoma

¹Guimin Wang, ²Wenxin Zhang, ³Chang Su, ⁴Yinping Wang, ⁵Zengguang Liu, ⁶Qiang Guan

¹⁻⁶Department of Thyroid Surgery, The First Hospital of Jilin University, Changchun, Jilin, China

BACKGROUND AND AIMS

In order to provide a guide for clinical treatment, we study and analyze the pattern and risk factors of lymph node metastasis in papillary thyroid carcinoma.

METHODS

The clinical data of patients with clinical diagnosis of papillary thyroid carcinoma treated in the same surgery team of the Department of Thyroid Surgery of the First Hospital of Jilin University from August 2013 to May 2014 and the postoperative paraffin pathological diagnosis was thyroid papillary carcinoma were retrospectively analyzed. The 210 patients underwent radical thyroidectomy and lymphadenectomy by the same surgeon. And we compared lymph node metastasis with clinical features such as sex, age, TSH level, tumor size, tumor location, extra-capsular invasion, etc.

RESULTS

(1) The central neck lymph node metastasis rate of PTC was 55.2% (116/210). (2) Age, tumor size, capsular invasion, TSH level, and multifocal PTC were significantly correlated to lymph node metastasis. And age, tumor size, and multifocal PTC were independent risk factors for lymph node metastasis in PTC. (3) Tumor location was compared with central neck lymph node, which separated into different regions; the superior mediastinal was definitely related with tumor location. Its lymph node metastasis rate went higher as the location of tumor went lower, from 9.68% (3/31), 0.77% (12/39), 1.43% (11/35), 36.17% (17/47), to 43.18% (19/44). (4) When tumor was in the upper region, the metastasis rate of right recurrent chain lymph node was zero, while when tumor was in the lower region, the metastasis rate of right recurrent chain lymph node was 15.38% (10/65).

CONCLUSION

(1) Age younger than 45 years, multifocal PTC, and diameter ≥ 1 cm could be taken as the risk factors for lymph node metastasis. (2) When mass is in the lower region, the risk of lymph node metastasis is higher in superior mediastinal, right recurrent chain, and paratracheal. (3) The lymph node metastasis rate of right recurrent chain is low, especially when mass is in the upper region; the rate is zero, so we should not take this region in patients with no risk factors for lymph node metastasis.

Coexistence of Medullary Carcinoma and Papillary Carcinoma in the Same Lobe of the Thyroid: A Rare Case Report

¹Xianying Meng, ²Qiang Zhang, ³Renzhu Pang, ⁴Shuai Yang, ⁵Guang Chen

¹⁻⁵Department of Thyroid Surgery, The First Hospital of Jilin University, Changchun, Jilin, China

BACKGROUND AND AIMS

We report a rare case of coexistence of medullary thyroid carcinoma (MTC) and papillary thyroid carcinoma (PTC) in the right thyroid lobe.

METHODS

A 60-year-old female patient was diagnosed with MTC and PTC after right hemithyroidectomy. The extreme rarity of this pathological feature is discussed.

RESULTS

While immunohistochemistry for calcitonin and thyroglobulin suggested histogenesis, cytopathology of the biopsy confirmed MTC and PTC. The coexistence of MTC and PTC differs from the more common mixed tumors as both tumors occurred in the single tissue.

CONCLUSION

This case report not only can improve the clinical diagnosis rate of rare cases but can also avoid reoperation of patients and improve the survival and quality of life of patients.

Research for Lymph Node Metastasis of Papillary Thyroid Carcinoma in CN0 Stage: A Retrospective Study of 450 Cases in Northeast China

¹Xianying Meng, ²Qiang Zhang, ³Renzhu Pang, ⁴Shuai Yang, ⁵Guang Chen

¹⁻⁵Department of Thyroid Surgery, The First Hospital of Jilin University, Changchun, Jilin, China

BACKGROUND AND AIMS

To discuss the metastasis rule of cervical lymph nodes in thyroid papillary carcinoma (PTC) to find a rational surgery plan.

METHODS

Clinical data was retrospectively analyzed for 450 PTC patients in CN0 stage who underwent surgery in our hospital from 2008 to 2013.

RESULTS

Lymph node metastasis was most commonly detected in the VI region, about 46.22% (208/450). The incidence of lymph node metastasis was 8.89% (40/450) in the IV region, 6.00% (27/450) in the III region, and 4.44% (20/450) in the IIa region. When the

tumor size was more than 1.0 cm, capsule invasive, and multifocal; when the patient was male; or when the age was <45, the incidence of lymph node metastasis significantly increased ($p < 0.05$). In addition, when the tumor was located in the upper pole of thyroid, the incidence of metastasis was 33.57% (48/143) in the II, III, and IV regions, while when it was in the lower pole, the incidence of metastasis in the contralateral VI region was 10.48% (13/124).

CONCLUSION

Lymph node metastasis occurs most commonly in the VI region in PTC, and neck dissection in this region should be performed regularly. We should expand the extent of neck dissection for patients with high risk factors. Neck dissection in the contralateral VI region should be performed when the tumor is located in the lower pole of thyroid, while for the tumor located in the upper pole, neck dissection in IIa, III, and IV regions should be performed as well.

Research on Influence Factors and Clinical Significance of Delphian Lymph Node Metastasis in Papillary Thyroid Carcinoma

¹Xianying Meng, ²Qiang Zhang, ³Renzhu Pang, ⁴Shuai Yang, ⁵Guang Chen

¹⁻⁵Department of Thyroid Surgery, The First Hospital of Jilin University, Changchun, Jilin, China

BACKGROUND AND AIMS

The objective of this study was to determine the incidence and significance of delphian lymph node metastasis in papillary thyroid cancer and to evaluate the clinical significance of delphian lymph node metastasis in patients with papillary thyroid cancer.

METHODS

This paper reviewed the medical records of 182 patients with pathologically confirmed papillary thyroid carcinoma who underwent thyroid surgery and in whom delphian lymph node was detected between September 2013 and January 2015 in the First Hospital of Jilin University. The relationship between related clinical factors and the delphian lymph node metastasis is analyzed. The clinical factors of statistical significance were analyzed by logistic regression analysis and were to further validate effect. Correlation analysis was carried out between the positive number of delphian lymph node and central paratracheal lymph node and lateral metastasis; the relationship between delphian lymph node metastasis and ipsilateral or contralateral Level VI lymph node metastasis.

RESULTS

Delphian lymph node metastasis is related with the factors of age, biggest diameter of tumor, capsule invasion, and concomitant Hashimoto's thyroiditis. Tumor size larger than 1 cm and capsule invasion are the danger factors of delphian lymph node metastasis. Central and lateral lymph node metastasis rates are positively related with the number of metastatic delphian lymph nodes. When patients are having single side involved and metastatic delphian lymph node, the metastasis rate of affected side and opponent Level VI is higher.

CONCLUSION

Special attention should be paid to the evaluation of delphian lymph node and intraoperative exploration, inspection should be done to determine whether metastasis before operation when patients have relevant risk factors; unilateral carcinoma patients whose delphian lymph node determined to be positive should increase the dissection of contralateral lymph node appropriately. When the number of delphian lymph nodes positive can be relaxed and the dissection indications of ipsilateral cervical lymph nodes dissection should be relaxed appropriate.

Significance of Lateral Neck Dissection on Papillary Thyroid Cancer in CN0

¹Xianying Meng, ²Renzhu Pang, ³Qiang Zhang, ⁴Shuai Yang, ⁵Guang Chen

¹⁻⁵Department of Thyroid Surgery, The First Hospital of Jilin University, Changchun, Jilin, China

BACKGROUND AND AIMS

To discuss the significance of lateral neck dissection for papillary thyroid cancer in CN0.

METHODS

Clinical data of the 121 cases of CN0 PTC patients who underwent surgery were retrospectively analyzed from February 2012 to February 2014 in the First Hospital, Jilin University.

RESULTS

(1) The lymph node metastasis rate was 45.45% in 121 cases of CN0 PTC; among them the highest metastasis rate was 43.80% (53/121) in region VI and 13.22% (16/121) in region II–IV. (2) The difference of metastasis rate between region VI and region II–IV

was statistically significant ($p < 0.05$), and they were significantly correlated (correlation coefficient). (3) The region II–IV lymph node metastasis was most commonly detected in the level of region IV and the difference of metastasis rate between regions II to IV was statistically significant ($p < 0.05$).

CONCLUSION

Papillary thyroid cancer is prone to cervical lymph node metastasis; it is most common in region VI. We suggest that the VI area lymph nodes should be cleaned regularly when it is the initial surgery for CN0 PTC. According to the lymph node metastasis preventive cleaning region II–IV lymph node.

Synergistic Effects of Celecoxib on Trail-induced Apoptosis in Medullary Thyroid Cancer TT Cells

¹Xianying Meng, ²Qiang Zhang, ³Renzhu Pang, ⁴Shuai Yang, ⁵Guang Chen

¹⁻⁵Department of Thyroid Surgery, The First Hospital of Jilin University, Changchun, Jilin, China

BACKGROUND AND AIMS

Tumor necrosis factor–related apoptosis-inducing ligand (TRAIL) currently plays an important role under clinical development as a cancer therapeutic factor because it is capable of preferentially inducing apoptosis in human cancer cells. Medullary thyroid cancer, however, is resistant to TRAIL.

METHODS

Tumor necrosis factor–related apoptosis-inducing ligand (TRAIL) currently plays an important role under clinical development as a cancer therapeutic factor because it is capable of preferentially inducing apoptosis in human cancer cells. Medullary thyroid cancer, however, is resistant to TRAIL.

RESULTS

In the search of cancer therapeutics that can overcome TRAIL resistance, we showed that celecoxib can sensitize TRAIL-resistant TT cell lines to promote TRAIL-induced apoptosis through the upregulation of TRAIL death receptor DR5, the downregulation of cellular Fas-associated death domain-like interleukin-1 β -converting enzyme-inhibitory protein (c-FLIP), and the cleavage of caspase-8 in TT cells.

CONCLUSION

The study suggests a framework for TRAIL-based combination treatment of TT cell line.

Analysis of Central Lymph Nodes Metastatic Risk Factors in Hashimoto's Thyroiditis Coexisting with Papillary Thyroid Carcinoma

¹Zhe Han, ²Guang Chen

^{1,2}Department of Thyroid Surgery, The First Bethune Hospital of Jilin University, Jilin, Changchun, China

BACKGROUND AND AIMS

Currently, there is no clear surgical choice of papillary thyroid carcinoma associated with chronic lymphocytic thyroiditis. We analyzed clinical data of patients with chronic lymphocytic thyroiditis, to discover the characteristics of both the pathology. So an analysis of papillary thyroid carcinoma associated with chronic lymphocytic thyroiditis pathology can provide a guide for clinical treatment.

METHODS

The study subjects were 697 patients all treated at the Department of Thyroid Surgery, First Hospital of the Jilin University, Changchun, China, from September 2012 to September 2013. Inclusion criteria were: the information of the patients was complete and the postoperative paraffin pathological diagnosis was thyroid papillary carcinoma. Intraoperative frozen pathological guided the operation. Of a total of 697 patients, 192 had chronic lymphocytic thyroiditis. We analyzed the pathological difference between papillary carcinoma patients and those associated with chronic lymphocytic thyroiditis, and also the risk factors on lymph node metastasis of PTC patients combined with Hashimoto's thyroiditis (HT).

RESULTS

There were 697 PTC patients, including 192 cases with HT. When the PTC was associated HT, the lymph node metastasis rate decreased. At the same time, in patients with HT, the tumor diameter was smaller. For PTC with HT, age, diameter of tumor, extrathyroidal extension, and multifocal and central lymph node metastasis were significantly correlated at the 0.05 level. There was no significant correlation between gender and the metastatic rate of the lymph node. When the patient was younger than 45 years, the tumor diameter was less than 1 cm, and there was no extrathyroidal extension, the central region lymph node metastasis rate decreased.

CONCLUSION

In thyroid papillary carcinoma with HT, tumor is smaller. For thyroid papillary carcinoma with HT, the lymph node metastasis rate is low. Age < 45 years, tumor diameter ≥ 1 cm, and extrathyroidal extension are the risk factors on central lymph node metastasis of thyroid papillary carcinoma with HT.

A Study of the Impact of Total Thyroidectomy in Unilateral Exophthalmos in Southern India

¹Sankaran Muthukumar, ²Dhalapathy Sadacharan, ³Krishnan Ravikumar, ⁴Mohanapriya Gajarajan, ⁵Zaheer Hussain, ⁶RV Suresh

¹⁻⁶Department of Endocrine Surgery, Madras Medical College, Chennai, Tamil Nadu, India

BACKGROUND AND AIMS

Thyroid-associated exophthalmos is frequently encountered in patients with Graves' disease, which can lead to impaired social and emotional well-being of the individual. Although bilateral eye involvement is more common, around 10 to 15% of patients present with unilateral involvement. We intend to study the impact and outcome of total thyroidectomy (TT) on unilateral exophthalmos (UE) based on the hormonal status.

METHODS

Twenty-one patients with clinically evident UE were enrolled in the study. All patients underwent a complete ophthalmic evaluation, orbital imaging (CT/MRI), and thyroid function tests. Patients were further grouped into group A (hyperthyroid) and group B (euthyroid and hypothyroid). Group A patients were rendered euthyroid by medications and taken up for TT. Hypothyroid patients in group B were placed on supplementary thyroxine therapy. Patients were serially followed up at 1, 3, and 6 months' interval. Patients with clinically evident bilateral exophthalmos were excluded from the study.

RESULTS

Group A comprised 16 (76.2%) patients (males: 2, females: 14) and group B comprised 5 (23.8%) patients (males: 1, females: 4). Both groups were age and sex matched. Although there were no signs of bilateral exophthalmos on imaging, there were other signs of bilateral eye involvement (ophthalmopathy other than exophthalmos) in group A [6/16 (37%)] and none in group B. Clinical decrease in exophthalmos was observed in 14 (87.5%) patients in group A following surgery, whereas 1 (6.2%) had no improvement and 1 (6.2%) had progressive disease. In group B, 1 (20%) hypothyroid patient had some improvement and 4 (80%) did not have any improvement in the UE.

CONCLUSION

Unilateral exophthalmos in a hyperthyroid patient has a more favorable outcome than in euthyroid or hypothyroid patients. Total thyroidectomy offers a good modality of treatment in preventing disease progression (UE) and cure in hyperthyroid patients.

Parameters	Hyperthyroid n = 16	Hypo/Euthyroid n = 5	p-value (significant p < 0.05)
Proptosis (mm) at diagnosis	20.8 \pm 0.9	20.6 \pm 1.14	0.84
Proptosis (mm) after treatment	18.1 \pm 1.4	20.2 \pm 1.3	0.018
Improvement	87.5% (n = 14)	12.5% (n = 1)	0.004

The Impact of Thyroiditis on Morbidity and Safety in Patients undergoing Total Thyroidectomy in Iodine-sufficient Areas

¹Krishnan Ravikumar, ²Dhalapathy Sadacharan, ³Sankaran Muthukumar, ⁴Gajarajan Mohanapriya, ⁵Zahir Hussain, ⁶RV Suresh

¹⁻⁶Department of Endocrine Surgery, Madras Medical College, Chennai, Tamil Nadu, India

BACKGROUND AND AIMS

The prevalence of thyroiditis is higher in iodine-sufficient areas. Indications for surgery in thyroiditis vary from compressive symptoms to cosmesis. We performed analysis of the incidence of complications in patients undergoing total thyroidectomy (TT) in goiters associated with thyroiditis.

METHODS

This retrospective study was done in an endocrine surgical center in the coastal part of south India over a period of 4 years (May 2011–April 2015). Out of 724 TT done for benign conditions, 272/724 (37.56%) cases whose histopathology showed thyroiditis were included in the study. Malignancy, non-thyroiditis cases, and reoperative cases were excluded from the study. Based on histopathology, 272 cases were divided into two groups: Group A [nodular goiter with associated thyroiditis cases, n = 164 (60.29%)] and group B [Hashimoto's thyroiditis cases, n = 108 (39.70%)]. The preoperative parameters analyzed were demography, serum calcium, serum vitamin D, serum PTH, and vocal cord status. The intraoperative parameters observed were operating time, parathyroids preserved, parathyroids autotransplanted, and course of recurrent laryngeal nerve (RLN). Postoperative parameters monitored were serum calcium, serum PTH, serum magnesium, signs and symptoms of hypocalcemia, and vocal cord status. Follow-up was done at 3 and 6 months with serum calcium, serum PTH, and video laryngoscopy.

RESULTS

Both groups were age and sex matched. All preoperative and intraoperative parameters were comparable among groups. Transient hypocalcemia was observed in 72/164 (43.9%) in group A and 63/108 (58.30%) in group B ($p=0.014$). Transient RLN palsy occurred in 18/164 (11.0%) in group A and 21/108 (19.4%) in group B ($p=0.039$). On follow-up, permanent hypoparathyroidism was observed in 6/164 (3.7%) in group A and 10/108 (9.3%) in group B ($p=0.049$). Permanent RLN palsy was observed in 5/164 (3.0%) in group A and 7/108 (6.5%) in group B ($p=0.148$). All parameters are given in Table 1.

CONCLUSION

Surgery for thyroiditis is associated with increased morbidity. Anticipation of complications and meticulous dissection of RLN and parathyroids will minimize the complications in thyroiditis cases.

Table 1: Comparison of NCAT and HT cases

<i>Parameters</i>	<i>NCAT Group A (n = 164)</i>	<i>HT Group B (n = 108)</i>	<i>p-value</i>
Preoperative Parameters			
Age (Years)	37.45 ± 12.20	38.16 ± 11.50	0.630
Sex (M:F)	21:143	12:96	0.413
Sr Magnesium (mg/dL)	2.04 ± 0.19	2.07 ± 0.19	0.160
Sr PTH (pg/ml)	44.70 ± 8.22	46.08 ± 8.52	0.186
Sr 25 OH Vitamin D(ng/ml)	21.27 ± 7.15	20.62 ± 6.86	0.460
Intraoperative Parameters			
Operating Time (minutes)	102.05 ± 12.86	103.02 ± 11.64	0.398
Parathyroids Preserved (numbers)	3.69 ± 0.50	3.78 ± 0.46	0.142
Parathyroid Autotransplantation	33/164 (20.1%)	31/108 (28.7%)	0.069
Postoperative Parameters			
Sr PTH (pg/ml)	16.96 ± 8.13	17.66 ± 9.88	0.526
Sr Magnesium (mg/dL)	1.88 ± 0.19	1.91 ± 0.18	0.131
Transient Hypocalcemia, n (%)	72/164 (43.9%)	63/108 (58.3%)	0.014
Transient RLN palsy, n (%)	18/164 (11.0%)	21/108 (19.4%)	0.039
Follow-up			
Permanent Hypoparathyroidism, n (%)	6/164 (3.7%)	10/108 (9.3%)	0.049
Permanent RLN palsy, n (%)	5/164 (3.0%)	7/108 (6.5%)	0.148

Values: Mean ± standard deviation; NCAT: Nodular goiter with associated thyroiditis; HT: Hashimoto's thyroiditis; RLN: Recurrent laryngeal nerve

Efficacy of Story Telling in Thyroid Surgery

¹Sabaretnam Mayilvaganan, ²Gyan Chand, Anjali Mishra, ³Gaurav Agarwal, ⁴Amit Agarwal, ⁵AK Verma, ⁶Saroj Mishra

¹⁻⁶Department of Endocrine Surgery, Sanjay Gandhi Postgraduate Institute of Medical Sciences, Lucknow, Uttar Pradesh, India

BACKGROUND AND AIMS

Introduction

In the modern-day busy clinical practice, the communication between patient/relative and care giver is at the minimal level. The patients and relatives feel apprehensive when advised about the surgical/interventional treatment. In such a situation they feel the need for detailed information from the care givers, which on many occasions is not available. Story telling is such a technique of health communication made out in lay people's language, which can be animated and made interactive using virtual characters and can operate in a virtual environment eliminating the need of health professionals. We intended to study the efficacy of story telling technique on patients undergoing hemithyroidectomy for benign cytology.

METHODS

A story of a lady (cartoon version) aged 25 years with a benign thyroid nodule who underwent uneventful hemithyroidectomy is depicted in this movie including the history, clinical examination, investigations, counseling, and operative procedure, and the running time of the animation movie is 4 minutes. For developing this movie, high-end graphic computer work station and various multimedia authoring tools like Adobe Flash, Photoshop, Captivate, Maya, and Final Cut Pro were used. The story was shown to patients with clinically solitary thyroid nodules who were provisional candidates for surgery in the outpatient department. The patients filled in the evaluation of multimedia animation questionnaire at the time of discharge.

RESULTS

Twenty patients filled the questionnaire. Nineteen found the movie useful and their remaining questionnaire was analyzed. The mean age was 35.45 ± 12.8 years, and 15 (75%) were females. All patients were euthyroid. The mean weight was 40.80 ± 20.79 gm. The final histopathology was colloid in majority. In the questionnaire, the mean score for improved understanding of the disease was 73.9 ± 14.7 ($p=0.003$), better organization of treatment was 78.6 ± 13.1 ($p=0.000$), stimulated interest in relatives was 70.8 ± 15.8 , and saved unnecessary discussion with the consultant was 55.5 ± 7.8 .

CONCLUSION

Story telling is a useful tool in health communication. With widespread availability of high-speed internet and affordable mobile computing devices such kind of information can be of use to the patients and relatives in decision making and also saves valuable time of the treating consultant. Future studies with larger numbers are needed.

Post-thyroidectomy Parathyroid Hormone Measurement on the Morning after: A Useful Predictor for Early and Safe Discharge

¹Suganya Sekar, ²Victoria Job, ³Pooja Ramakant, ⁴Deepak Thomas Abraham, ⁵Paul Mazhuvanchery Jacob

^{1,3-5}Department of Endocrine Surgery, Christian Medical College Hospital, Vellore, Tamil Nadu, India

²Department of Biochemistry, Christian Medical College Hospital, Vellore, Tamil Nadu, India

BACKGROUND AND AIMS

Early discharge of patients after thyroidectomy is reportedly feasible and safe. In many low- to middle-income countries where insurance and costs do not drive same-day discharge, the day after surgery maybe optimal, allowing nausea and vomiting to settle and most bleeding complications to be managed in the hospital. Delayed hypocalcemia, however, is a problem. Serum parathormone assay has been shown to be an effective predictor, but with variable timing and cut-off values. We evaluated a protocol using parathyroid hormone (PTH) ≥ 6 pg/ml on the morning after surgery based on a cut off derived from our retrospective data.

METHODS

A prospective study of 125 consecutive patients in a tertiary care hospital in India was done over a period of 2 years. Patients with PTH ≥ 6 pg/ml and normocalcemia were discharged. Those with PTH < 6 pg/ml or serum calcium < 8 mg/dl or both were not discharged till serum calcium values were stable or rising with oral supplements.

RESULTS

The rate of temporary hypocalcemia was 28.8%; 72.2% of these patients had PTH < 6 pg/ml. PTH with a cut-off at 6 pg/ml had sensitivity 73.5%, specificity 94.5%, and positive predictive value 83.3% in predicting hypocalcemia; testing was found reliable by ROC.

A total of 85 patients had normal PTH and serum calcium and 88.2% of them accepted discharge; the others had a drain, postoperative hemorrhage, or wished to stay. Mean duration of stay was 1.5 days. One patient discharged on day 1 had delayed hypocalcemia on follow-up but was managed uneventfully with oral calcium and vitamin D supplements.

CONCLUSION

A PTH-based protocol can be effectively used for early discharge of thyroidectomy patients in resource-limited settings. In our study, PTH ≥ 6 pg/ml was an effective cut-off permitting early discharge. The majority (88.2%) of those eligible for early discharge could leave safely with no readmissions.

Surgical Audit of Thyroid Surgery in a Tertiary Care Center: Keeping Complications Low in Spite of a High Cancer Load

¹Deepak Thomas Abraham, ²Siddharth Chakravarthy, ³Anish Jacob Cherian, ⁴Pooja Ramakant, ⁵Paul M Jacob

¹⁻⁵Department of Endocrine Surgery, Christian Medical College, Vellore, Tamil Nadu, India

BACKGROUND AND AIMS

Thyroid surgery is the most common operation performed in an endocrine surgery department. We present the surgical audit for thyroid surgery from a dedicated endocrine surgery center.

METHODS

Retrospective review of a prospectively maintained database in the department as well the hospital information system was done for the years 2012–2014.

RESULTS

In the study period, 437, 440, and 543 thyroid operations were done annually and total thyroidectomy was the most common operation performed [263 (60.1%), 306 (69.5%), and 378 (67.3%)]. Hemithyroidectomy formed a small subset of thyroid operations [41 (9.4%), 16 (3.6%), and 28 (5.1%)].

Histopathological examination revealed thyroid malignancy in the majority of patients [270 (61.78%), 292 (66.36%), and 285 (52.48%)], of which the classic type of papillary thyroid cancer (PTC) was the most common subtype. Nodular hyperplasia was seen in 130, 119, and 150 patients in the 3-year study period.

Recurrent laryngeal nerve injury was observed in 27/797 (3.4%), 19/826 (2.3%), and 21/971 (2.16%) cases where the denominator was the nerves at risk. Recovery of voice was seen in 6, 6, and 4 patients respectively.

Biochemical hypocalcemia was seen in 129/392 (33%), 114/413 (28%), and 128/515 (25%) patients in the immediate postoperative period for the study period. Symptomatic hypocalcemia was seen in 10.71, 7.2, and 14.75% patients respectively. Permanent hypocalcemia for the year 2012 and 2013 was seen in 1.27 and 1.21% patients respectively. Chyle leak was observed in 8/93 (8.6%), 7/89 (7.9%), and 6/84 (7.1%). All patients did not require re-exploration. Postoperative hematoma was seen in 1.8, 1.36, and 1.1% patients during the 3 years.

Sternotomy was needed in four patients in each year of the study. The indications included malignancy, mediastinal nodal disease, tracheal resection, and retrosternal extension of benign goiters.

CONCLUSION

Thyroid malignancy is the most common indication for thyroidectomy in the institution. However, this operation can be done with minimal morbidity when done in dedicated endocrine surgical units with a high patient load.

BRAF V600E Mutations in Fine needle Aspirates from Thyroid Nodules: Useful Information for the Surgeon

¹MJ Paul, ²Hemalatha Yadav, ³Rekha Pai, ⁴Marie Therese Manipadam, ⁵Deepak Thomas Abraham

⁶Pooja Ramakant, ⁷Simon Rajaratnam, ⁸Nihal Thomas

¹⁻⁸Department of Endocrine Surgery, Christian Medical College and Hospital, Vellore, Tamil Nadu, India

BACKGROUND AND AIMS

Thyroid nodules are increasingly being detected and the use of fine needle aspiration (FNA) is the mainstay of management though limited by indeterminate diagnosis in a significant proportion. Several molecular markers have been considered as potential adjuncts to cytology. The BRAFV600E mutation has been found to be highly specific to papillary thyroid carcinomas (PTC) and is believed to provide additional information as a prognostic marker correlating with aggressive disease and recurrence. However,

information on the use of FNA for detection of these mutations preoperatively is limited. This study evaluated the utility of FNA samples for the detection of BRAF mutations and correlation with clinical and pathological parameters.

METHODS

Fine needle aspiration samples from suspicious nodules in 407 patients were prospectively collected and 277 adequate samples were assessed for the presence of BRAF mutations by PCR followed by sequencing. Size of tumor, multifocality, extrathyroidal extension, and lymph node metastasis were correlated with the mutational pattern.

RESULTS

A total of 277 thyroid nodules tested revealed 33% malignant by cytological examination with 88 PTCs. Twenty-four percent of the PTCs were positive for the V600E mutation. The mutation was not seen among the other subtypes of tumor including the anaplastic and the poorly differentiated types. A comparison of the clinicopathological features with the BRAF status showed that BRAF-positive cases were significantly associated with LN metastasis ($p = 0.006$) and with extrathyroidal extension (0.013).

CONCLUSION

The FNA yield was sufficient for BRAF analysis consistent with published reports. Mutation presence significantly predicted higher risk disease and lymph node involvement. This information can be used for planning surgical strategy and extent of dissection.

Endoscopic Thyroidectomy by Ipsilateral Axilla and Areola Approach with Gas Insufflations: Initial Experience

Gyan Chand

Department of Endocrine Surgery, Sanjay Gandhi Postgraduate Institute of Medical Sciences, Lucknow, Uttar Pradesh, India

BACKGROUND AND AIMS

To evaluate the feasibility and outcome of endoscopic thyroidectomy through ipsilateral axilla and areola approach.

METHODS

The clinical data of 31 cases that underwent thyroid surgery through ipsilateral axilla and areola approach from December 2013 to November 2015 at our institute were reviewed. All cases were operated by single surgeon.

RESULTS

The mean age was 30.0 ± 10.0 years, the male-to-female ratio was 2:7, the mean duration of goiter was 34.14 months, and the surgery performed was total thyroidectomy in 10%, hemithyroidectomy in 84%, completion thyroidectomy in 3%, and converted to open in 3%. Mean nodule size was 4.48 cm and mean gland weight was 16.10 gm. The mean duration of surgery was 148.27 minutes for hemithyroidectomy and 270 minutes for total thyroidectomy. Mean hospital stay was 2.36 days for hemithyroidectomy and 6.33 days for total thyroidectomy. Final histopathology was benign colloid nodule 78%, follicular adenoma 13%, follicular carcinoma 3%, hurthle cell adenoma 3%, and follicular variant of papillary thyroid carcinoma 3%. The postoperative complications included hypoparathyroidism in three patients of total thyroidectomy, parasthesia around neck in four patients, and bad scar around nipple in one patient; all were managed conservatively. There was one conversion to open due to hemorrhage from upper pole of thyroid. There was no case of permanent hypoparathyroidism and recurrent laryngeal nerve palsy. The cosmetic outcome was excellent.

CONCLUSION

The ipsilateral axilla and areola approach is feasible in a selected group of patients of thyroid tumor with excellent cosmetic outcome.

Outcome of 18F-fluorodeoxyglucose Positron Emission Tomography-directed Resections in Differentiated Thyroid Carcinoma: Experience in a Developing Country

¹Chandan Kumar Jha, ²Anjali Mishra, ³Prasanta Kumar Pradhan, ⁴Amit Agarwal

⁵Gaurav Agarwal, ⁶Gyan Chand, ⁷Sanjay Gambhir, ⁸Saroj Kanta Mishra

^{1,2,4,6,8}Department of Endocrine Surgery, Sanjay Gandhi Postgraduate Institute of Medical Sciences, Lucknow, Uttar Pradesh, India

^{3,7}Department of Nuclear Medicine, Sanjay Gandhi Postgraduate Institute of Medical Sciences, Lucknow, Uttar Pradesh, India

BACKGROUND AND AIMS

Scarce information is available about the outcome of patients with recurrent or persistent DTC who undergo surgery based on PET findings. The aim of this study was to know the value of PET in localizing the disease and influencing the outcome of patients with DTC who underwent reoperation based on PET results.

METHODS

Retrospective study was done (December 2007–July 2015) consisting of a select group of 26 patients with recurrent or persistent DTC. All had raised thyroglobulin (Tg) levels, positive PET, and negative radioiodine (RAI) scans. All had received RAI therapy (263 ± 193 mCi). Clinical details, pre- and postoperative Tg levels, PET, operative, histology, and follow-up findings were noted.

RESULTS

Mean age was 44 years (M:F=1:1.9). Interval between the last surgery for DTC and PET-directed surgery was 39 ± 41 (11–204) months. FDG-PET disclosed 63 hot spots (central compartment 17, lateral neck 25, mediastinum 8, axilla 8, lung 2, and 1 each in sternum, trachea, and breast) in 26 patients. A total of 49 out of 63 sites were explored and 35 of those were metastatic lesions from DTC on histopathology. The histopathology of other 14 sites were reported as granulomatous lesion (4), other malignancy (2), and neither malignancy nor granulomatous inflammation (8). Follow-up after reoperation was 41 ± 25 (6–88) months. Patient- and lesion-based positive predictive value of PET was 88.5 and 71.4% respectively. Post-surgery (6 months) Tg levels were significantly low ($p < 0.001$), but only 2 out of 18 patients who were treated with a curative intent had biochemical cure ($Tg < 2$ ng/ml) after surgery for recurrent disease. On long-term follow-up, Tg showed a rising trend.

CONCLUSION

PET-directed reoperations may not contribute to long-term disease control in patients with DTC. False positive scans are frequent in regions with high prevalence of inflammatory diseases.

Role of BRAF Mutation in Determining the Central Lymph Node Dissection in Papillary Thyroid Carcinomas

¹Nelson George, ²Amit Agarwal, ³Niraj Kuamri, ⁴Sarita Agarwal, ⁵Sushil Gupta, ⁶Narendra Krishnani, ⁷PK Singh

^{1,2}Department of Endocrine Surgery, Sanjay Gandhi Postgraduate Institute, Lucknow, Uttar Pradesh, India

^{3,6}Department of Pathology, Sanjay Gandhi Postgraduate Institute, Lucknow, Uttar Pradesh, India

⁴Department of Medical Genetics, Sanjay Gandhi Postgraduate Institute, Lucknow, Uttar Pradesh, India

⁵Department of Endocrinology, Sanjay Gandhi Postgraduate Institute, Lucknow, Uttar Pradesh, India

⁷Department of Anesthesia, Sanjay Gandhi Postgraduate Institute, Lucknow, Uttar Pradesh, India

BACKGROUND AND AIMS

Some studies have proposed using BRAF V600E mutation to justify the surgical management of patients with papillary thyroid cancer (PTC). But there are few studies that state the BRAF association with the lymph node metastasis in patients who have undergone centre lymph node dissection. The aim of our study is to find the role of BRAF in determining whether center compartment lymph node dissection (CCLND) along with total thyroidectomy (TT) should be performed.

METHODS

A total of 75 patients with PTC who have undergone TT and CCLND were selected for the study. The study was approved by the Institutional Ethical Committee. BRAF mutation status was determined in fresh frozen tissue samples and FFPE tissues. DNA was isolated by using Quiagen DNA isolation kit. RFLP PCR was performed for the BRAF V600E. Randomly selected samples were confirmed for mutation by sequencing.

RESULTS

In a total of 75 PTC cases selected, histopathology revealed 34 (45.33%) had lymph node metastasis (LNM); among this group, 26 (76.47%) showed BRAF positivity. In the other group with negative LNM, 51.21% (21/41) were screened for BRAF positivity. There was a significant association of BRAF with LNM in which TT and CCLND were performed.

CONCLUSION

Since our study has shown positive correlation between CCLND and BRAF positivity, those cases that show BRAF positivity on preoperative FNAC specimens may be subjected to prophylactic CCLND.

Study on Ultrasound-guided Fine Needle Aspiration Cytology for Palpable Thyroid Tumors (> 1 cm) along with Assessment of Clinical and Sonological Features predicting Thyroid Malignancy

¹Siddhartha Chakravarthy Nalukurthi, ²Deepak Abraham, ³Anuradha Chandramohan, ⁴NK Shyamkumar, ⁵Pavithra Mannam
⁶Anne Jennifer, ⁷Nihal Thomas, ⁸Dukhabandhu Naik, ⁹Gowri Mahasampath, ¹⁰MJ Paul

^{1,2,10}Department of Endocrine Surgery, Christian Medical College, Vellore, Tamil Nadu, India

³⁻⁵Department of Radiology, Christian Medical College, Vellore, Tamil Nadu, India

⁶Department of Pathology, Christian Medical College, Vellore, Tamil Nadu, India

^{7,8}Department of Endocrinology, Christian Medical College, Vellore, Tamil Nadu, India

⁹Department of Biostatistics, Christian Medical College, Vellore, Tamil Nadu, India

BACKGROUND AND AIMS

To determine the adequacy and accuracy of ultrasound-guided fine needle aspiration cytology (US-FNAC) from palpable thyroid nodules (> 1 cm). To study the clinical and sonological features predictive of thyroid malignancy in palpable thyroid nodule.

METHODS

Ultrasound-guided fine needle aspiration cytology was done in 290 patients from December 2013 to December 2014 by the radiologist in the presence of a surgeon and an onsite cytotechnician. All the samples were reported by a dedicated cytopathologist. Accuracy was calculated by comparing FNAC with histopathology for those who had thyroidectomy. Clinical features of the thyroid were recorded by the surgeon and ultrasound features were recorded using the thyroid imaging reporting and data system (TIRADS). Statistical analysis was performed using Stata 13.1; chi square was performed to see the association between clinical variables, US-FNAC, and final histopathology.

RESULTS

A total of 80.1% of the samples were adequate excluding 17 cystic swellings. A total of 117/290 patients were operated till February 2015. The sensitivity and specificity of US-FNAC in this study was 83.1 and 81.3% respectively with an accuracy of 82.4% in predicting malignancy. Thirty-six benign FNAC patients underwent thyroidectomy and 10 (28%) of them were malignant on histopathology (8/10 were follicular variant of papillary thyroid carcinoma).

Univariate analysis showed the following factors: US-FNAC, hypoechoic/markedly hypoechoic, taller than wide, ill-defined margins, microcalcification, significant lymph nodal involvement, solid lesion, and TIRADS to be significant in predicting malignancy. Multivariate analysis showed US-FNAC, hypoechoic, and solitary thyroid nodules to be significant in predicting thyroid malignancy.

CONCLUSION

The use of US-FNAC in palpable thyroid nodules reduces the rates of inadequate samples. Each institute should validate the Bethesda system of thyroid FNAC reporting, as the rate of malignancy may vary in individual categories. The accuracy rate in inadequate, benign, and AUS categories needs to improve in this study. Ultrasound and clinical features have an important role in the management of thyroid carcinoma.

How Reliably Zuckerkandl's Tubercle can be Helpful as an Anatomical Landmark to identify and Safeguard Recurrent Laryngeal Nerve and Superior Parathyroid during Thyroid Surgery

¹Kailash Chandra Mohapatra, ²Geetanjali Panda, ³Reena Minz

¹⁻³Department of Surgery, SCB Medical College, Cuttack, Odisha, India

BACKGROUND AND AIMS

Aim

To study the Zuckerkandl's tubercle in regard to its constancy, position, grade, type and relationship with RLN and Superior Parathyroid and how helpful it is to safeguard these structures.

Background

Zuckerkandl's tubercle (ZT) is defined as posterior extension of thyroid. Identification and preservation of recurrent laryngeal nerve (RLN) is an important step in thyroid surgery. Research has shown that Zuckerkandl tubercle is of considerable help as an anatomical pointer to RLN and superior parathyroid for their effective preservation in thyroid surgery.

METHODS

Fifty consecutive thyroidectomies from July 2014–July 2015 were evaluated. All cases were operated by a single surgeon. The incidence and size of the ZT and its positional relationship to RLN and SP were investigated and classified according to size: Grade 0 (unrecognizable), Grade I (≤ 5 mm), Grade II (6–10 mm) and Grade III (> 10 mm). The running pathway of the RLN in the ZT area was classified as: Type A=posterior to ZT surface, type B=anterior to ZT surface, type C=passing through ZT parenchyma and type D=Lateral of ZT. Relationship of ITA with RLN and PT was also studied side by side and compared.

RESULTS

Zuckerkindl's tubercle was identified in 34(/50) cases, 20 on the right and 14 on the left. Out of 18(/50) total thyroidectomies, 8 had bilateral ZT, 3 right and 3 left ZT. Out of 20 right hemithyroidectomies 12 had right ZT. Out of 12 left hemithyroidectomies 10 had left ZT. ZTs were mostly Grade II (40.2%) and RLNs were mostly type A (90.1%).

CONCLUSION

Zuckerkindl's tubercle is a frequently encountered anatomical structure in our study (68%). Constant relationship has been observed between ZT, RLN and SP. ZT can be used as a landmark to identify and safeguard RLN and PT during thyroid surgery.

Association of Drain Tip Culture with Post Thyroidectomy Wound Infection

¹Ali Ramouz, ²Seyed Ziaeddin Rasihashemi, ³Homan Alipour

^{1,3}Medicine Faculty and Students Research Committee, Tabriz University of Medical Sciences, Tabriz, Iran

²Department of Cardiothoracic Surgery, Tabriz University of Medical Sciences, Tabriz, Iran

BACKGROUND AND AIMS

One of the rare but hazardous complications of thyroid surgery is wound infection. Due to current controversy on routine use of the drain among surgeons and considering its presence as a foreign material, current study evaluated the clinical significance of the drain tip culture relevant to wound infection.

METHODS

From March 2014 to March 2015, 243 patients underwent thyroid surgery and 150 enrolled our study. Wound infection defined as those occurring within 14 days of surgery and in case of suspicion for wound infection sterile wound sampling was performed immediately and sample was sent to microbiology laboratory.

RESULTS

During 2 weeks follow-up, postoperative infection developed in 13 patients (8.6%). The sensitivity and specificity of the drain tip culture were 15% and 82%, respectively with a positive predictive value of 7.6%. During multivariate analysis, we found that coexisting age 50 years or older and positive drain tip culture are associated with wound infection. The only independent risk factor for wound infection in thyroid surgery was prolonged operative time, but there was no significant relationship between drain tip culture and wound infection.

CONCLUSION

We concluded that the drain tip culture is not a predictor of the wound complications in thyroid surgeries; in addition, our analysis suggests that the routine use of the surgical drain can lead to increase the incidence of the wound infection. However, prolonged operative time is an independent risk factor associated with wound complications in thyroid surgeries.

Downhill Varices in the Hypopharynx Due to Huge Thyroid Tumor: A Case Report

¹Ryuta Nagaoka, ²Marie Sanada, ³Kiyotaka Nagahama, ⁴Ritsuko Okamura, ⁵Haruki Akasu

⁶Takehito Igarashi, ⁷Kazuhiko Yokoshima, ⁸Ryuji Ohashi, ⁹Iwao Sugitani

^{1,2,4,6,9}Department of Endocrine Surgery, Nippon Medical School, Bunkyo, Tokyo, Japan

^{3,8}Department of Analytic Human Pathology, Nippon Medical School, Bunkyo, Tokyo, Japan

⁵Department of Endocrine Surgery, Nippon Medical School Musashikosugi Hospital, Bunkyo, Tokyo, Japan

⁷Department of Otorhinolaryngology, Nippon Medical School, Bunkyo, Tokyo, Japan

BACKGROUND AND AIMS

Downhill varices are usually caused by superior vena cava (SVC) obstruction due to bronchogenic carcinoma or mediastinal tumors. They have a retrograde blood flow and located in the proximal esophagus. Varices in the hypopharynx as a result of mediastinal thyroid tumor are extremely rare.

METHODS

A 70-year-old male initially visited a neighbor hospital for huge enlarging thyroid tumor in his right neck. The patient had noticed the tumor for over 35 years. Fine needle aspiration cytology of the tumor revealed benign goiter. Contrast enhanced computed tomography showed large tumor (13 × 10 × 5 cm) in the right lobe of the thyroid extending into the mediastinum. Furthermore, well-enhanced mass mimicking hypopharyngeal cancer was pointed out at the posterior hypopharynx and the patient was referred to our department. Endoscopic examination demonstrated varices at the dorsal wall of the hypopharynx and we avoided biopsy. Preoperative diagnosis was huge adenomatous goiter and hypopharyngeal varices caused by obstruction of the internal jugular and brachiocephalic vein due to the goiter. Total thyroidectomy was carried out and the varices in the hypopharynx disappeared on the next day.

RESULTS

Histopathological diagnosis for the thyroid tumor was poorly-differentiated carcinoma. He is free from any sign of recurrence and complication 1 year after surgery.

CONCLUSION

Mediastinal thyroid tumor rarely causes “downhill varices” due to SVC obstruction. However, in this case, signs of SVC obstruction were absent and the varices were not found in the upper esophagus, but in the hypopharynx. Obstructed venous flow from thyroid plexus might bypass via superior laryngeal vein and cause varices in the posterior hypopharynx. When a patient with large mediastinal goiter is accompanied by tumor-like lesion in the hypopharynx, it is important to consider the possibility of downhill varices before conducting immediate biopsies.

Skip Metastasis to Lateral Neck Lymph Nodes in Papillary Thyroid Cancer

¹Young Jae Ryu, ²Dong Hoon Cho, ³Jin Seong Cho, ⁴Jung Han Yoon, ⁵Min Ho Park

¹⁻⁵Department of Surgery, Chonnam National University Hwasun Hospital and Medical School, Buk-gu, South Korea

BACKGROUND AND AIMS

Papillary thyroid cancer (PTC) is commonly related with cervical lymph node metastases, which are usually in a consecutive pattern from central to lateral. However, a small number of patients have skip metastases, which present in a pattern of leaping metastasis without central lymph node metastasis. We conducted this study to evaluate the clinicopathological features of skip metastases in PTC.

METHODS

We retrospectively reviewed 346 patients who underwent total thyroidectomy, central lymph node dissection, and modified radical neck dissection. The clinicopathological results were analyzed according to the presence or absence of skip metastases.

RESULTS

Skip metastases were found in 74 patients (21.4%). Patients with skip metastases tended to have tumors that were no more than 1 cm in diameter ($p=0.008$) and primary tumors of the upper pole ($p=0.031$). The lateral lymph node metastases ratio was lower (0.28 ± 0.16 vs 0.20 ± 0.17 , $p=0.001$) and the frequency of single lateral neck level involvement was higher (26.5% vs 47.3%, $p=0.001$) in the patients with skip metastases. Tumors of the upper pole and tumors ≤ 1 cm in size were correlated with skip metastasis in the multivariate analysis.

CONCLUSION

Skip metastases can occur frequently in PTC patients. Primary tumors of the upper pole or tumors that are no more than 1 cm in diameter can be closely correlated with skip metastases in PTC. Therefore, lateral neck lymph nodes should be carefully evaluated to decide the extent of surgery.

The Size of Tumor is the Most Important Predictor for the Number of Lymph Node Metastases

¹Jeonghun Lee, ²Euy-Young Soh

^{1,2}Department of Surgery, Ajou University Hospital, Suwon-si, Gyeonggi-do, South Korea

BACKGROUND AND AIMS

The papillary thyroid cancer (PTC) is the most frequent subtype among thyroid cancers. Lymph node (LN) metastases are frequent in PTC and the incidence is 60% on average. Recent studies have shown the recurrence was related with the number of LN metastases. Therefore, we investigated the predictive factors for the number of LN metastases.

METHODS

From January 2009 to December 2013, we retrospectively enrolled 1,287 PTC patients, who underwent thyroidectomy at Ajou University Hospital. One thousand one hundred eight female patients accounted for 86% and 1,030 patients with positive BRAF mutation made up 80% of them.

RESULTS

The number of LN metastases was statistically related to age, gender, height, the size of tumor, the multifocality of cancer, capsular invasion, and lymphovascular invasion. However, BRAF mutation was not related to the number of LN metastases. In multivariate analysis, the number of LN metastases increased in large tumor (partial R²; pR²,0.33), lymphovascular invasion (pR²,0.28), male gender (pR², 0.15), age (pR²,0.108), and multifocality (pR², 0.156). Additionally, lymphovascular invasion was associated with large tumor (p < 0.001) and, the lymphovascular invasion was found 2.1, 7.3, or 11.3 times more frequently in the tumor with 1–2 cm, 2–3 cm or ≥ 3 cm than in the tumor with the size of < 1 cm (p < 0.001).

CONCLUSION

The size of tumor is the most important predictor for the number of LN metastases, and the lymphovascular invasion, which is considerably related with the number of LN metastasis. Therefore, the size of tumor is considered an important factor for preoperative management.

Variables	Total no. of metastatic LNs	
	Pearson coefficient	p-value
Age	−0.1	<0.001
Tumor size	0.278	<0.001
Height	0.088	<0.001
Weight	0.041	0.024

Variable	Total no. of metastatic LNs		p-value
Gender	Male	3.2 ± 0.44	<0.001
	Female	1.7 ± 0.11	
Multiplicity	Absent	1.4 ± 0.12	<0.001
	Present	2.6 ± 0.23	
Capsular invasion	Absent	2.3 ± 0.1	<0.001
	Present	4.9 ± 0.18	
Lymphovascular invasion	Absent	1.6 ± 0.09	<0.001
	Present	6.6 ± 0.94	
BRAF	Absent	4.3 ± 0.27	0.518
	Present	4.0 ± 0.12	

Variable	Total no. of metastatic LNs		
	β ± SE	Partial R ²	p-value
Age	−0.04 ± 0.012	−0.108	<0.001
Gender	2.095 ± 0.416	0.156	<0.001
Height			0.999
Weight	−0.27 ± 0.013	−0.063	0.043
Tumor size	0.218 ± 0.021	0.330	<0.001
Multiplicity	0.906 ± 0.274	0.156	0.001
Capsular invasion			0.593
Lymphovascular invasion	5.058 ± 0.543	0.289	<0.001
BRAF			0.410

Lymphovascular invasion

Variable	Lymphovascular invasion		p-value
	Absent	Present	
Age	46.9 ± 0.32	44.0 ± 1.31	0.024
Height	161.2 ± 0.29	162 ± 0.99	0.356
Weight	62.4 ± 0.42	59.9 ± 1.24	0.133
Tumor size	8.6 ± 0.166	11.0 ± 1.22	<0.001

Variable	Lymphovascular invasion		p-value
	Absent	Present	
Gender			0.841
Male	169 (93.4%)	12 (6.6%)	
Female	1037 (93.8%)	69 (6.2%)	
Multiplicity			<0.001
Absent	783 (95.6%)	36 (4.4%)	
Present	423 (90.4%)	45 (9.6%)	
Capsular invasion			0.002
Absent	543 (96.2%)	22 (3.9%)	
Present	663 (91.8%)	59 (8.2%)	
BRAF mutation			0.009
Absent	231 (89.9%)	26 (10.1%)	
Present	975 (94.7%)	55 (6.3%)	

Variable	Lymphovascular invasion	
	p-value	Odd ratio
Age (<55 years)	0.021	2.1
Capsular invasion	0.034	1.8
Multiplicity	0.002	2.1
Tumor size	<0.001	
1–2 cm	0.006	2.1
2–3 cm	<0.001	7.3
≥ 3 cm	<0.001	11.3
BRAF mutation (-)	<0.001	2.6

Bilateral Axillo-Breast Robotic Thyroidectomy can be performed Safely in Differentiated Thyroid Carcinoma Larger Than 2 cm

¹Young Jun Chai, ²Jung-Woo Woo, ³Ra-Yeong Song, ⁴Hyeong Won Yu, ⁵Hyungju Kwon

⁶Jin Wook Yi, ⁷Joon-Hyop Lee, ⁸Su-jin Kim, ⁹June Young Choi, ¹⁰Kyu Eun Lee

¹Department of Surgery, Seoul National University Boramae Medical Center, Seoul, Korea

^{2-6,8,10}Department of Surgery, Seoul National University Hospital and College of Medicine, Seoul, Korea

^{7,9}Department of Surgery, Seoul National University Bundang Hospital and College of Medicine, Seoul, Korea

BACKGROUND AND AIMS

The safety of robotic thyroidectomy (RT) has been well established for an early stage differentiated thyroid carcinoma and it is generally indicated for the tumors ≤ 2 cm. In this study, we evaluated the surgical outcomes of RT for differentiated thyroid carcinoma larger than 2 cm.

METHODS

The medical records were retrospectively reviewed for the patients who underwent total thyroidectomy or hemithyroidectomy accompanied by completion thyroidectomy due to 2–4 cm differentiated thyroid carcinoma from 2009 to 2014. As an RT procedure, bilateral axillo-breast approach was used.

RESULTS

Totally 86 patients were eligible (21 RT, 65 OT). Mean age was 30.8 for RT, and 51.6 years for the OT group ($p < 0.001$). The mean tumor size was 2.8 cm for both groups. Operation time was longer in the RT than in the OT group (165.1 ± 43.9 vs 93.5 ± 30.8 minutes, $p < 0.001$). No significant differences were found in the number of retrieved central lymph nodes in papillary thyroid carcinoma patients (RT 6.4 ± 3.5 vs OT 6.1 ± 3.9 , $p = 0.816$), vocal cord palsy rate (transient, RT; 19.0% vs OT; 9.2%, $p = 0.250$, permanent, 0% vs 1.5%, $p = 1.000$), or the postoperative hypoparathyroidism rate (transient, RT 19.0% vs OT; 33.8%, $p = 0.199$, permanent, 0% for both). At initial radioactive iodine treatment, the proportion of the patients with serum stimulated thyroglobulin level of < 1.0 ng/ml in the absence of anti-Tg antibody was 53.8% (7/13) for RT group and 65.3% (32/49) for OT group ($p = 0.525$). Neither group had recurrences during the median follow up period of 36.9 months for RT and 25.5 months for OT group.

CONCLUSION

BABA RT is a safe and oncologically sound treatment option for 2–4 cm differentiated thyroid carcinoma for a selected group of patients. Its role in advanced thyroid carcinoma management should be continually evaluated as the RT experience and technology evolve.

Aggressive Variants of Papillary Microcarcinoma

¹Hyeung Kyoo Kim, ²Seok-Mo Kim, ³Hojin Chang, ⁴Bup-woo Kim, ⁵Yong sang Lee, ⁶Hang-Seok Chang, ⁷Cheong Soo Park

¹⁻⁷Department of Surgery, Gangnam Severance Hospital, Yonsei University College of Medicine, Seoul, South Korea

BACKGROUND AND AIMS

The widespread use of ultrasonography and US-guided fine needle aspiration cytology (FNAC) which has led to diagnosis of small papillary carcinoma less than 10 mm in greatest dimension. One of the latest issues of PTMC has rising observation trial. And the other is not recommended FNAB in PTMC. But there is also aggressive pathologic type in PTMC. The aim of this study is to evaluate clinicopathologic features of aggressive variants PTMC and to comparison of the clinicopathologic characteristics of aggressive variants of PTMC and conventional PTMC.

METHODS

Between January 2009 and December 2014, 8,549 patients were analyzed. Of these patients, 120 had aggressive pathologic type (tall cell variant, diffuse sclerosing variant, solid variant) and 8,429 had conventional pathologic type. The clinicopathologic characteristics including gender, age, multiplicity, thyroiditis, capsule invasion, and nodal status of the two groups were compared.

RESULTS

The two groups were not different in regard to the gender. Aggressive pathologic type PTMC presented with significantly young age ($p < 0.001$), multiplicity ($p < 0.001$), thyroiditis ($p < 0.001$), capsule invasion (0.003) and node metastasis ($p < 0.001$); central node metastasis 87 pts. (72.5%, $p < 0.001$) and lateral node metastasis 33 pts. (27.5%, $p < 0.001$) compared to conventional pathologic type PTMC.

CONCLUSION

Usually, PTMC have good prognosis and grows slowly. But, Papillary thyroid microcarcinoma also have an aggressive variants pathology. It is dilemmas in the management of PTMC. We should reconsider that FNAB in PTMC was not recommended.

Utility of Completion Thyroidectomy and Radioactive Iodine Remnant Ablation for minimally Invasive Follicular Thyroid Carcinoma diagnosed after Hemithyroidectomy: Verification by Inverse Probability of Treatment Weighting

¹Yu-mi Lee, ²Yi Ho Lee, ³Tae-Yon Sung, ⁴Jong Ho Yoon, ⁵Ki-Wook Chung, ⁶Suck Joon Hong

¹⁻⁶Departments of Surgery, Asan Medical Center, University of Ulsan College of Medicine, Ulsan, South Korea

BACKGROUND AND AIMS

There is still controversy about performing additional treatment for patients with minimally invasive follicular thyroid carcinoma (MIFTC) after diagnostic hemithyroidectomy. The aim of this study is to compare clinical outcome based on surgical extent in patients with MIFTC.

METHODS

A review of patient records identified 259 patients who underwent surgery at Asan Medical Center from 1996 to 2010 and were subsequently diagnosed with MIFTC. Patients who underwent total thyroidectomy initially or had distant metastasis at initial diagnosis or within 12 months of the initial operation were excluded. Finally, 166 patients were included in this study. We verified the impact of surgical extent on distant metastasis using weighted logistic regression models with inverse probability of treatment weighting (IPTW).

RESULTS

A total of 166 patients included 31 males (18.7%) and 135 females (81.3%), with mean age 41.5 ± 13.5 years (13–74 years). The median follow-up period was 103.5 months (13–244 months). Seven patients (4.2%) had distant metastases during follow-up. Male gender and vascular invasion showed significant affect to distant metastasis in univariate analysis ($p = 0.018$ and 0.004 , respectively), but only vascular invasion was an independent risk factor in multivariate analysis ($p = 0.007$). Surgical extent did

not influence distant metastasis in both univariate and multivariate analysis ($p=0.419$ and 0.585 respectively). Logistic regression with IPTW using the propensity scores estimated by adjusting all parameters also demonstrated that completion thyroidectomy did not influence the development of distant metastasis ($p=0.761$).

CONCLUSION

Completion thyroidectomy followed by radioactive iodine remnant ablation after diagnostic hemithyroidectomy in patients with MIFTC did not reduce the development of distant metastasis during the follow-up period.

Navigation Program: Is It Helpful for Perioperative Care with Thyroid Cancer Patients?

¹Kyung Ah Park, ²Young Ja Oh, ³Yong Sang Lee, ⁴Hang-Seok Chang, ⁵Cheong Soo Park

^{1,2}Thyroid Cancer Center, Division of Nursing, Gangnam Severance Hospital, Yonsei University College of Medicine, Seoul, South Korea

³⁻⁵Department of Surgery, Thyroid Cancer Center, Gangnam Severance Hospital, Yonsei University College of Medicine, Seoul, South Korea

BACKGROUND AND AIMS

As the number of thyroid cancer patients has increased, the patients' need to receive proper perioperative care has increased. Patients want to secure enough time for medical consultation and education about the surgery that they are confronted with. The patient navigation programs have been proposed as a potential solution for assisting with cancer care delivery and assessing for underserved patients. The recent professional navigation program has been designed to provide continuous care to the patients who are diagnosed with cancer. The purpose of this study was to develop and evaluate a navigation program for patients with thyroid cancer.

METHODS

This study was designed with methodological research and a case-control study. The navigation program was developed following an analysis of the patients' unmet needs, using the five phases of the ADDIE (Analysis, Design, Development, Implementation, and Evaluation) model. The patients who received surgery for thyroid cancer participated in this study. A total of 99 patients in the control group received usual care, and the 95 patients in the navigated group received a navigation program during perioperative period. In order for the effectiveness of the navigation program to be evaluated, both groups received a questionnaire with an explanation of the study.

RESULTS

Overall, the navigated group showed higher satisfaction scores ($p=0.025$) than the control group. The patients' satisfaction scores regarding the continuity of information ($p<0.001$), continuity of management ($p=0.002$), continuity of relationship ($p<0.001$), and empowerment of patients ($p<0.001$) were also higher in the navigated group.

CONCLUSION

The newly developed navigation program for patients with thyroid cancer was effective in raising the satisfaction level of patients and in actively managing the disease in perioperative care.

Usefulness of Determination for Central Lymph Node Metastasis by a Surgeon using the Palpation in Papillary Thyroid Cancer

¹Wan Wook Kim, ²Jin Hyang Jung, ³Seung Ook Hwang, ⁴Jeeyeon Lee, ⁵Taek Ju Kwon, ⁶Jin Ho Jung, ⁷Ho Yong Park

¹⁻⁷Department of Surgery, Kyungpook National University, Daegu, South Korea

BACKGROUND AND AIMS

Prophylactic *vs* therapeutic central node dissection (CND) in papillary thyroid carcinoma (PTC) is still controversial.

The intraoperative frozen section biopsy is useful to evaluate the LN metastasis; however, it is not much available in many institutions.

The purpose of this study was to evaluate the accuracy of judgment for central LN metastasis in PTC by a single surgeon using inspection and palpation to determine whether CND is needed.

METHODS

From October 2014 to February 2015, 127 PTC patients with clinically LN negative who had thyroidectomy and CND were enrolled in this study. One specialized thyroid surgeon examined all each LNs after CND by inspection and palpation. The criterion of

suspicious LN was hardness (harder than rubber) rather than enlargement or discoloration. We analyzed the accuracy of judgment for central LN metastasis in PTC by a single surgeon using inspection and palpation.

RESULTS

Central LN metastases were found in 50.4% (64/127) and micro-metastases in 36 patients (57.8%). Suspicious LN was determined by the surgeon in 20.5% (28/127) cases, and 26 of them (92.8%) were diagnosed with metastasis on final pathology. The metastatic LNs were found in 38 patients (38.3%); among 99 patients with no suspicious LN, 29 patients of them (76.3%) had micro-metastases. The sensitivity, specificity, positive and negative predictive values of determination of LN metastasis by surgeon were 40.6, 96.8, 92.8 and 61.6% respectively. The determination of central LN metastasis by the surgeon had low sensitivity and NPV due to a high percentage of micrometastasis. However, it is found to be high specificity and PPV.

In addition, specificity, PPV in cases without thyroiditis is much higher (100%).

CONCLUSION

The determination of central LN metastasis by the surgeon using inspection and palpation could be used to determine whether CND is needed due to high specificity and positive predictive value.

Prognosis of Papillary Thyroid Cancer with Extrathyroidal Extension according to the Location of Primary Tumor

¹Seok-Mo Kim, ²Soo Young Kim, ³Hyeung Kyoo Kim, ⁴Ho Jin Chang, ⁵Bup-Woo Kim,
⁶Yong Sang Lee, ⁷Cheong Soo Park, ⁸Hang-Seok Chang

¹⁻⁸Thyroid Cancer Center, Gangnam Severance Hospital, Yonsei University College of Medicine, Seoul, South Korea

BACKGROUND AND AIMS

Extrathyroid extension (ETE) has been recognized as a prognostic factor in papillary thyroid carcinoma (PTC). Even though there were posterior extensions to larynx, trachea, esophagus, or recurrent laryngeal nerve, complete resection with no microscopic residual tumor (R0 resection) could be performed. In this study, we investigated the prognostic significance of location of primary tumor in PTC with ETE.

METHODS

Between January 2007 and December 2009 at Gangnam Severance Hospital (Seoul, Korea), we identified 1,078 patients who had PTC with ETE and 1,199 patients with no or microscopic ETE. In 1,078 patients, we compared anterior and posterior ETE.

RESULTS

The mean follow-up period was 6.4 years. Although patients with ETE showed a significantly worse disease-free survival (DFS) rate than those with no or microscopic extension ($p < 0.001$), there was no difference in the DFS rate between patients with anterior extension and those with posterior extension in case of R0 resection.

CONCLUSION

Extrathyroidal extension of primary tumor appears to be an important prognostic factor for PTC; however, the location of primary tumor could have little or no prognostic significance in case of R0 resection.

The Recurrence of Thyroid Cancer on the Same or Different Levels of the Primary Lateral Neck Metastatic Nodes

¹Woo Young Kim, ²Jeonghun Lee, ³Euy-Young Soh

¹⁻³Department of Surgery, Ajou University Hospital, Suwon-si, Gyeonggi-do, South Korea

BACKGROUND AND AIMS

Previously published retrospective studies have suggested that regional lymph node (LN) metastases do not affect survival in patients with papillary thyroid cancer (PTC). N1b status in patients with differentiated thyroid carcinoma is implied to result in worse disease-free survival (DFS). The objective of this study was to investigate whether the recurred thyroid cancer having the differently located LNs has more aggressive features than the equally located LNs when recurred thyroid cancer has the same or different located lateral neck metastatic LNs.

METHODS

Charts were reviewed to obtain clinical details regarding the preoperative, intraoperative, and pathological findings and follow-up data. From January 1995 to December 2013, we retrospectively enrolled 6,694 thyroid cancer patients who underwent thyroidectomy with more central neck dissection at Ajou University Hospital. The study set included 88 recurrent thyroid cancer patients with lateral neck dissection. Fifty-two patients had the recurrence on the same location or level as primary metastatic LNs and 36 on different locations. All cases of recurrent disease were confirmed pathologically.

RESULTS

A total of 44.2% of the recurrence on the same location and 66.7% at a different location had multiplicity ($p=0.012$). The M stage of primary thyroid cancer had an influence on the locations of recurrence ($p=0.043$). The time until recurrence was 54.6 ± 23.8 months at the same location and 75.6 ± 38.4 months at different locations ($p<0.001$). In multivariable logistic regression analysis, only time until recurrence was the significant factor associated with the location of metastatic LNs in the recurrent thyroid cancer ($p=0.018$, odds ratio (95% CI) 1.832 (1.386–3.552)).

CONCLUSION

There were a few studies for the status of recurrence such as locations or extranodal extension etc. We supposed that if the locations of recurrent, metastatic lateral nodes were different from the previous locations of primary metastatic lateral nodes, primary thyroid cancer had more aggressive characteristics and the recurrent cancer had more extensively metastatic status.

Revisiting Risk Factors for Thyroid Malignancy in a State Endemic of Iodine Deficiency Goiter

¹MeiWan Wong, ²Imisairi Abdul Hadi, ³Kamarul Imran Musa

^{1,2}Department of Surgery, Hospital Raja Perempuan Zainab II, Kota Bharu, Kelantan, Malaysia

³Department of Community Medicine, School of Medical Sciences, University Sains Malaysia, Kubang Kerian, Kelantan, Malaysia

BACKGROUND AND AIMS

Thyroid malignancy has been increasingly common recently. One reason for the rising incidence of thyroid malignancy is accidental finding of cancer in the resected specimen of thyroidectomies performed for benign goiters. This study aims to reevaluate the types and risk for thyroid malignancy in patients who underwent primary thyroid surgery at the surgical department of Raja Perempuan Zainab II Hospital, Kota Bharu Kelantan.

METHODS

Data from 699 patients who had thyroid surgery between June 2007 and December 2014 were retrospectively reviewed. We used unadjusted logistic regression to estimate the risk of age, duration, and weight of resected specimen for thyroid malignancy.

RESULTS

The mean age, duration of neck swelling, and weight of resected specimen were 43.5 years (SD=14.0), 5.9 months (SD=6.7), and 157 gm (SD=161.0) respectively. Of all patients, 26.9% had thyroid malignancy ($n=188$). The commonest type of thyroid malignancy was papillary (77.13%), followed by follicular (17.6%) and others (5.3%). Age associates with risk for malignancy ($p<0.001$), but the duration of neck swelling ($p=0.513$) and the weight of resected specimen ($p=0.955$) do not. With an increase of 1 year of age, the odds to have thyroid cancer increases by 2%. This is equivalent with 14.4% increase in cancer for every 5-year increase in age.

CONCLUSION

The incidence of thyroid malignancy in our sample is high; hence it necessitates a careful approach in the management of thyroid disease. In our setting, increasing age is associated with higher prevalence for thyroid cancer. High index of suspicion for cancer is warranted when managing elderly patients presenting with goiter.

Childhood Thyroid Cancer: An Angel within a Devil

¹Shun Siang Chong, ²Normaya Kitan, ³Sarina Basro

¹⁻³Department of Surgery, Ministry of Health, Putrajaya, Malaysia

BACKGROUND AND AIMS

Childhood thyroid cancer is rare with the incidence of 0.5 per million per year.

METHODS

Data were collected from operation registry of the hospital. All patients below 20 years who underwent thyroidectomy were analyzed.

RESULTS

We encountered 23 cases of childhood thyroid cancer among 63 patients who were 19 years old and below undergoing thyroidectomy since the year 2000 when the hospital started providing service as endocrine tertiary referred center of Malaysia. All patients presented with neck nodule. A total of 17 out of 23 patients presented in their teenage (74.0%); 14 patients (60.8%) presented during the first year of symptom. The sex ratio of male:female was 1:2 with 7 males and 15 females. Twenty patients had papillary thyroid cancer and two patients had follicular thyroid cancer. One patient underwent prophylactic total thyroidectomy at the age of 7 years. She had strong family history of MEN-2A and tested proto-oncogene codon 634 positive with raised calcitonin level. One patient underwent hemithyroidectomy for solitary thyroid nodule of 2 cm, found to have micropapillary thyroid cancer of 7 mm. For all the other patients, total thyroidectomy had been done. Thirteen out of 23 patients underwent modified radical neck dissection as well. Radio-iodine ablation was given to 20 patients as adjuvant therapy. A total of 22 patients are still under our follow-up with one defaulter from Hong Kong. To date, there has been no mortality. Twelve patients are disease free, 6 patients have remnant detected at thyroid bed on diagnostic whole body scan, and four patients have lung metastases.

CONCLUSION

This paper reviewed the demography, pathology, treatment, and survival of thyroid cancer patients in childhood and adolescent. It also discusses the optimal management provided to this unique population.

Early Experience with Robot-assisted Transaxillary Thyroid Surgery at Hospital Kuala Lumpur, Malaysia

¹MW Wong, ²NA Hakim, ³RA Rafli, ⁴EN Aina

¹⁻⁴Department of Breast and Endocrine Surgery, Hospital Kuala Lumpur, Kuala Lumpur, Malaysia

BACKGROUND AND AIMS

Robot-assisted thyroid surgery is gaining popularity due to good cosmetic outcome along with the advantages of having three-dimensional videoscopic visualization, surgery ergonomics, and dexterity. However, many centers do not utilize this technique due to its high cost and long learning curve. Hospital Kuala Lumpur is the only endocrine center in Malaysia that has started to embark on performing this procedure. We report our experience in this surgery in terms of patient acceptance, operating times, and complications.

METHODS

This is a retrospective review of robot-assisted transaxillary thyroidectomy surgeries performed from March 2013 until September 2015. Twenty-three patients underwent hemithyroidectomy, four patients had total thyroidectomy, while three patients had total thyroidectomy with central lymph node dissection for papillary thyroid carcinoma. Patients rated whether they were satisfied with the operative scar and surgery. Operating times were divided into position time, working space time, docking time, and thyroid surgery time. Complications such as recurrent laryngeal nerve injury, brachial plexus injury, and hypocalcemia were documented.

RESULTS

The range of patients' age in this case series was 22 to 65 years, all of them females. The average time for hemithyroidectomy were: positioning 14.78 minutes, working space 58.57 minutes, docking 12.48 minutes, and surgery 71.09 minutes. The average time for total thyroidectomy were: positioning 16.83 minutes, working space 59.33 minutes, docking 23.50 minutes, and surgery 100.17 minutes. All patients were satisfied with the surgical scar and surgery. Two patients experienced transient recurrent laryngeal nerve injury. No patient had brachial plexus injury, but one patient complained of chronic pain over the upper chest wall of the operating site. Two patients post total thyroidectomy developed temporary hypocalcemia.

CONCLUSION

Robot-assisted transaxillary thyroid surgery is well accepted considering good patient satisfaction and acceptable complication rate. Long operating hours can be improved with practice and experience of the surgeon.

Evaluation of Post-thyroidectomy/Parathyroidectomy Scar Cosmesis with Vancouver Scar Scale and Patient Satisfaction

¹Jih Huei Tan, ²Henry Chor Lip Tan, ³Junaidi Ai, ⁴Seniyah Md Sikin, ⁵Sarajah Arulanantham

¹⁻⁵Department of General Surgery, Hospital Sultan Ismail, Johor Bahru, Johor, Malaysia

BACKGROUND AND AIMS

Though there have been advances in the minimally invasive technique, the majority of the thyroid and parathyroid surgery remains via a standard neck collar incision. These patients are left with a scar to the neck with different cosmetic outcome and self-satisfaction.

METHODS

The study was conducted in the endocrine surgery unit of Hospital Sultan Ismail, Johor Bahru. We included 31 patients who had undergone parathyroid and thyroid surgery in 2015. Data were collected prospectively. Key factors such as material for skin closure, wound length, comorbidities, gland size, duration of surgery, histopathological diagnosis, extent of surgery, and postoperative infection were recorded on each follow-up. Incomplete data were excluded. A photo of the neck scar was taken 2 weeks to 6 months postoperatively. Ratings of scar were done using Vancouver scar scale (VSS) (0–13) by a single dermatology expert. All subjects were asked on their satisfaction score (SS) on scar cosmesis on a Likert scale of 0 to 10.

RESULTS

The mean age of the sample population was 48 years. There were 8 male and 23 female patients. The mean scar length was 5.97 cm (SD 1.52). Nineteen patients underwent total thyroidectomy, 5 right hemi-thyroidectomy, 6 parathyroid surgeries and 1 had secondary surgery for recurrent follicular thyroid cancer. Mean VSS score was 8.0 (SD 2.18) and the mean satisfaction score was 7.9 (SD 1.60). The usage of glue *vs* suture had no difference in the VSS ($p=0.193$) and patient's satisfaction ($p=0.590$) both in short and long term. The three ethnicities were not statistically different in the cosmetic outcome. But in the Malay group (mean SS=7.6), they had a lower satisfaction score compared to the Chinese (mean SS=8.1) and Indian (mean SS=8.0) groups.

CONCLUSION

The Malaysian population is concerned about neck scar cosmesis even in the Malay ethnicity though the neck is covered due to religious reason.

Is Prophylactic Continuous Infusion of Calcium Solution Better Than Bolus Calcium in Preventing Hypocalcemia after Total Thyroidectomy?

¹Nor Safariny Ahmad, ²Hussain Mohamad, ³Siti Hartinie Muhammad, ⁴Chang Bing Chi

¹⁻⁴Department of Surgery, Hospital Sultanah Nur Zahirah, Kuala Terengganu, Terengganu, Malaysia

BACKGROUND AND AIMS

Hypocalcemia is a frequent complication after total thyroidectomy widely ranging from 0.33 to 65%. A significant decrease in postoperative hypocalcemia was identified in patients who received prophylactic calcium. Prophylactic infusion of calcium solution reduced the prevalence of tetany from 8.6 to 2.1%. At present, there is no established study indicating the suitable dose and route of administration of calcium. The aim of this study is to identify whether prophylactic continuous infusion of calcium solution is better than bolus calcium in preventing hypocalcemia after total thyroidectomy.

METHODS

A prospective randomized study was conducted on patients who underwent total thyroidectomy. Two groups were identified: Group A received continuous intravenous calcium gluconate 3 gm in 500 ml normal saline for 24 hours and group B received intravenous bolus calcium gluconate 1 gm in 20 ml normal saline 8 hourly for 24 hours. Routine oral calcium and vitamin D supplement were given on postoperation day 1. Serum calcium was measured at 6, 12, 18, and 24 hours postoperation. Incidence of hypocalcemia, adverse effects of intravenous calcium, and duration of hospital stay were recorded (Table 1).

RESULTS

Sixty patients were recruited: 30 patients in group A and 30 patients in group B. The incidence of symptomatic hypocalcemia was higher in group A (8 *vs* 1 patient, $p<0.026$). Serum calcium at 12 and 18 hours postoperation were significantly higher in group B. Serum calcium at 12 hours in group A was 1.98 ± 0.21 $\mu\text{mol/L}$ (mean \pm SD) and in group B was 2.14 ± 0.15 $\mu\text{mol/L}$, $p<0.002$. Serum calcium at 18 hours in group A was 2.03 ± 0.20 $\mu\text{mol/L}$ and in group B was 2.15 ± 0.26 $\mu\text{mol/L}$, $p<0.049$. However, serum calcium at 6 and 24 hours were not significantly different. There was no difference in the adverse effect of intravenous calcium and the duration of hospital stay postoperation (Table 2).

CONCLUSION

Prophylactic treatment with intravenous bolus calcium gluconate 1 gm in 20 mL normal saline 8 hourly for 24 hours is better than continuous calcium gluconate infusion 3 gm in 500 ml normal saline for 24 hours in reducing the incidence of hypocalcemia after total thyroidectomy.

Table 1: Clinical characteristics of the patients

Variable	Group A	Group B	p-value**
No. of patients	30	30	
Age [#]	47.8 (24–70)	47.5 (30–73)	0.606 ^a
Sex (Men: Women)	5:25	7:23	0.519 ⁺
Graves' disease	0	2 (7%)	0.492 ^β
Preoperative calcium level (μmol/L) [#]	2.14 (1.72–2.47)	2.10 (1.69–2.46)	0.796 ^a
Surgeon			0.418 ⁺
Consultant Endocrine Surgeon	15 (50%)	20 (67%)	
Fellow Endocrine Surgeon	11 (37%)	7 (23%)	
General Surgeon	4 (13%)	3 (10%)	
Operation			0.389 ⁺
Total thyroidectomy	26 (87%)	28 (93%)	
Completion thyroidectomy & MRND	4 (13%)	2 (7%)	
No. of parathyroid gland preserved*	2.53 (± 1.20)	2.70 (± 1.15)	0.584 ⁺
Weight of thyroid gland (gram)*	92 (10–833)	114 (17–535)	0.439 ⁺

MRND=modified radical neck dissection; **p<0.05 was considered as significant; *Mean ± standard deviation; [#]Median (IQR); ^aMan-Whitney test; ^βFisher's exact test; ⁺Chi-square test

Table 2: Comparison of measures parameters in each group

Variable	Group A	Group B	p-value**
No. of patients	30	30	
Serum calcium (μmol/L)*			
6 hours postoperation	2.04 ± 0.20	2.08 ± 0.18	0.400 ⁺
12 hours postoperation	1.98 ± 0.21	2.14 ± 0.15	0.002 ⁺
18 hours postoperation	2.03 ± 0.20	2.15 ± 0.26	0.049 ⁺
24 hours postoperation	2.03 ± 0.26	2.15 ± 0.24	0.083 ⁺
Symptom and Sign of hypocalcemia			
Numbness	8 (27%)	1 (3%)	0.026 ^β
Chovstek's sign positive	0	0	
Tetany	0	0	
Adverse effects associated with intravenous calcium infusion (vein sclerosis, thrombophlebitis or allergic reaction)	0	0	
Postoperation hospital stay (day)	4.63 ± 4.70	5.50 ± 5.80	0.528 ⁺

**p<0.05 was considered as significant; *Mean ± standard deviation; ⁺Student's t test; ^βFisher's exact test

Incidence and Outcome of Patients diagnosed with Incidental Thyroid Cancer after Thyroidectomy for Presumed Benign Disease

¹Ee Wen Lim, ²Francis Yee, ³Kee Yuan Ngiam, ⁴Rajeev Parameswaran, ⁵Wee Boon Tan

^{1,2}Department of Medicine, National University of Singapore, Singapore

³⁻⁵Department of Thyroid and Endocrine Surgery, Division of General Surgery, National University Hospital, Singapore

BACKGROUND AND AIMS

We aim to examine the incidence of incidental thyroid cancer in patients undergoing thyroidectomy for presumed benign thyroid disease in a tertiary hospital. Treatment and outcome of the thyroid cancer patients will also be analyzed.

METHODS

This was a retrospective study of 355 patients who underwent total or hemi-thyroidectomy for a presumed benign thyroid disease from January 1, 2005, to December 31, 2014, at National University Hospital, Singapore.

RESULTS

Of the 355 patients, 75 (21.1%) were males and 280 (78.9%) were females, with ages ranging 21 to 79 years (mean = 45.89). Thyroid carcinomas were detected in 34 (9.6%) of the patients, with the distribution shown in Table 1. Of these, 15 (44.1%) had undergone a hemi-thyroidectomy, with 19 (55.9%) having total thyroidectomies.

For patients with incidental thyroid cancer and who had hemi-thyroidectomy as the initial procedure, 8/15 (53.3%) were followed-up with completion hemi-thyroidectomies. Thyroid carcinoma was detected in the contralateral thyroid lobe in 6/8 (75.0%) cases. A different cancer subtype from the initial surgery was diagnosed in four of them. Out of the remaining seven (46.7%) managed conservatively without completion thyroidectomy, cancer recurrence was noted in one case (14.3%).

Three patients with incidental thyroid cancer were lost to follow-up, with the average duration of follow-up being 48.5 months (0–126 months).

Sixteen (47%) were treated with radioiodine postoperation. The overall rate of recurrence was 11.8% with no thyroid cancer-related mortality.

Table 1: Distribution of types of thyroid carcinoma

Type of cancer		Incidence no. (%)
Papillary	Micro (< 1 cm)	17 (50)
	Classic	6 (17.6)
	Variant	6 (17.6)
Follicular		4 (11.8)
Undifferentiated		1 (2.9)

CONCLUSION

The rate of incidental cancer in presumed benign thyroid disease was 9.6% in our institution. This should be conveyed to the patient preoperatively even though they generally have a good clinical outcome.

Anatomic Variations of Inferior Laryngeal Nerve

¹Ismail Cem Sormaz, ²Ahmet Yalın İscan, ³İlker Özgür, ⁴Serhat Meric, ⁵Fatih Tunca, ⁶Yasemin Giles Senyurek

¹⁻⁶Department of General Surgery, Istanbul Medical Faculty, Istanbul University, Istanbul, Turkey

BACKGROUND AND AIMS

Inferior laryngeal nerve (ILN) palsy is one of the most common and dreaded complications of thyroid surgery. Unilateral palsy of ILN results in hoarseness and tolerable respiratory problems but bilateral palsy of ILN can result in serious disturbances in ventilation. Anatomic variations of ILN can increase the complication rate. In this study we aimed to evaluate the extralaryngeal branching of ILN and its relation with inferior thyroid artery.

METHODS

Five hundred consecutive patients who underwent total thyroidectomy as a primary procedure were included in this prospective, non-randomized study. Demographic data, indications for surgery, anatomic variations of ILN, and the frequency of complications were analyzed retrospectively.

RESULTS

A total of 500 patients with surgical thyroid disease were included in the study. The mean age of the patients was 46.1 ± 15.4 years (4–78 years), and the female:male ratio was 4.5:1. Of the 500 patients, 289 (57.8%) underwent surgery for malignant disease and 211 (42.2%) for benign disease.

Extralaryngeal terminal divisions of ILNs were determined in 276/1,000 (27.6%) nerves. The division of ILN on both sides was observed in 94 (18.8%) patients. The rate of division of the ILN was 26.6 (133/500) and 28.6% (143/500) at right and left sides respectively.

CONCLUSION

More than 25% of inferior laryngeal nerves have two or more branches before entering the larynx. To protect the extralaryngeal branches of ILN, the whole length of the nerve must be identified at the dissection.

The Impact of Sentinel Lymph Node Biopsy on the Decision of Prophylactic Central Lymph Node Dissection in Papillary Thyroid Cancer

¹Ismail Cem Sormaz, ²Ahmet Yalın İscan, ³İlker Özgür, ⁴Onur Bayram, ⁵Fatih Tunca, ⁶Yasemin Giles Senyurek

¹⁻⁶Department of General Surgery, Istanbul Medical Faculty, Istanbul University, Istanbul, Turkey

BACKGROUND AND AIMS

Routine application of prophylactic central dissection is controversial for papillary thyroid cancer (PTC) surgery. The fact is that metastasis can not be detected by histopathological examination by some PTC patients with routine dissection. Thus, prophylactic lymph node dissection on these patients would be an unnecessary intervention. The aim of this study was to evaluate the effect of intraoperative pathological examination for sentinel lymph node (SLN) metastasis diagnosed by preoperative lymphoscintigraphy in deciding for a prophylactic central ganglion.

METHODS

Data from 21 patients who underwent surgery with a clinical diagnosis of N0 PTC and preoperative lymphoscintigraphy were retrospectively reviewed. All patients had preoperatively ultrasonography guided 99m Tc-nanocolloid injection in malignant thyroid nodules, followed by lymphoscintigraphy imaging. Following thyroidectomy, an intraoperative gamma probe scan was performed and lesions with highest counts were considered as SLN. These lesions were excised and sent for frozen section examination, followed by a routine prophylactic ipsilateral central lymph node dissection.

RESULTS

Sentinel lymph node detection rate by lymphoscintigraphy was 71% (n=15). One SLN in 14 (93%) patients and two SLNs in one (7%) patient were detected and excised. Nine (56%) of these 16 excised SLNs were detected in the pretracheal and 7 (44%) in the paratracheal area. Metastatic SLN was detected at frozen section examination of SLNs that were excised from 15 patients. A total of 162 lymph ganglions were dissected from the central area, of which 35 (21.6%) were metastatic. For the detection of ipsilateral central area involvement of SLN biopsy by lymphoscintigraphy, the accuracy, sensitivity, and specificity values were 81, 33, and 100% respectively; PPV and NPV were 100 and 79%.

CONCLUSION

The specificity and PPV of lymphoscintigraphy with 99mTC-nanocolloid and SLN biopsy on clinical N0 PTC patients to detect central area involvement were found to be high. But the sensitivity rate of this technique was 33%. For a better evaluation of SLN biopsy's effect on N0 PTC patients in determining an SND decision, further studies with a greater number of patients are needed.

Thyroid Cancer Recurrence in Right Paraesophageal Lymph Node: The Most Common Overlooked LN during Central LN Dissection

¹Ping Jui Su, ²Shih Ming Huang

^{1,2}Department of Surgery, College of Medicine and Hospital, National Cheng-Kung University, Tainan, Taiwan

BACKGROUND AND AIMS

Central compartment dissection (CCD) typically involves removal of level VI lymph nodes, including the pretracheal, paratracheal, and prelaryngeal nodes on both sides. Right paraesophageal lymph node (RPLN) may be overlooked generally during CCD due to its unique anatomy. Recent studies have been reported that the rate of RPLN metastasis ranges from 12 to 20%. We applied the intraoperative nerve monitoring for eight patients with thyroid cancer who received reoperation for recurrent RPLN metastasis and we analyzed the clinical data.

METHODS

A total of eight patients (all females), seven with papillary thyroid cancers and one medullary cancer, who underwent total thyroidectomy with central lymph node dissection (CLND) in the initial operation were enrolled in this study. Their mean age was 50 years (28–77 years). The interval between initial surgery and revision surgery was from 1 to 17 years. Intraoperative nerve monitoring was routinely used, and four of them were added with Continuous Monitoring-Automatic Periodic Stimulation. The operation time, additional cost, and operative mobility were compared with 30 papillary cancer patients who underwent RPLN dissection during routine CLND

RESULTS

All but one (with medullary cancer) patient received radioiodine treatment before recurrent RPLN was found. Initial pathological staging was: three cases with stage III, three with stage II, and two with stage I. All of them were diagnosed by elevated serum Tg

or calcitonin and ultrasonography. The typical operative finding was that the adhesion between nerve and surrounding tissue or recurrent L/N was usually below the nerve. Four cases with tight adhesion had transient loss of signal of nerve monitor during operation due to traction. One case needed microscope dissection due to severe adhesion between nerve and RPLN. Four patients had transient hypocalcemia, but no permanent hypoparathyroidism or nerve damage. For the first operation, six operators were endocrine surgeons and two general surgeons. The cost of reoperation was 1.5 times that of the first operation, and the operative time for RPLN dissection was 82 ± 21 minutes compared with 6 ± 2 minutes in first operation.

CONCLUSION

Right paraesophageal lymph node dissection should be emphasized in the education of CCD. Missing or overlooking those RPLN will cause not only incomplete treatment but also increasing surgical mobility and medical cost during reoperation. Intraoperative nerve monitoring is useful for protecting nerve injury during reoperation.

Routine Use of Intraoperative Neuromonitoring of Recurrent Laryngeal Nerve improves Surgical Completeness and Safety in Thyroid Cancer Surgery

¹Si-Yuan Wu, ²Quan-Yang Duh, ³Chung-Bao Hsieh, ⁴De-Chan Chan, ⁵Jyh-Cheng Yu, ⁶Ming-Lang Shih

^{1,3-6}Department of Surgery Division of General Surgery, National Defense Medical Center, Taipei, Taiwan

²Department of Surgery, University of California, San Francisco, California, USA

BACKGROUND AND AIMS

Intraoperative neuromonitoring (IONM) was introduced to help surgeons confirm the location and function of recurrent laryngeal nerve (RLN). However, most published outcome data showed only its benefit in preventing nerve injury. The study aimed to demonstrate how IONM helps surgeons' learning curve and improves surgical completeness of total thyroidectomy for thyroid cancer over time.

METHODS

From July 2008 to December 2015, 670 patients, 1,074 nerves at risk, underwent thyroidectomy by a single surgeon at TSGH. Intraoperative neuromonitoring was used routinely after July 2010. We divided the cohort into two groups: Group A: with neuromonitoring (n=511). Group B: without neuromonitoring (n=241). Among them, 278 patients underwent total thyroidectomy and subsequent radioactive iodine (RAI) ablation treatment for differentiated thyroid cancer. A total of 229 patients had IONM while 49 did not. We analyzed the demographics, rates of RLN injury, identification, and operation time. The surgical completeness was compared by postoperative RAI uptake and TSH-stimulated thyroglobulin (Tg) level.

RESULTS

Intraoperative neuromonitoring helped identify 96.5% vs 27.7 of RLN ($p < 0.01$). The RLN injury rate decreased over time after routine use in transient: 3.6% vs 5.0% ($p = 0.5$) and permanent 0 vs 1.6% ($p = 0.063$) as well as the operation time, 125 minutes vs 146 minutes between groups A and B. The mean RAI uptake was significantly less in the IONM group (0.28 vs 0.64%, $p < 0.001$), and the transition point was at the time of routine use. The mean Tg level was lower in the IONM group, without significant difference (10.79 vs 27.27, $p = 0.14$).

CONCLUSION

Routine use of IONM improves surgeons' learning curve by increasing the RLN identification rate and decreasing the injury rate, shortening the operation time over time. In addition, IONM improves the surgical completeness by decreasing postoperative RAI uptake and Tg level.

Sentinel Lymph Node Biopsy in Medullary Thyroid Microcarcinoma using Methylene Blue Dye Mapping: A Pilot Study

^{1,2}Radan Dzodic, ³Nada Santrac, ⁴Merima Goran, ⁵Marko Buta, ⁶Igor Djuricic, ⁷Gordana Pupic, ⁸Ognjen Zivkovic, ^{9,10}Ivan Markovic

^{1,9}Surgical Oncology Clinic, National Cancer Research Center, Pasterova, Belgrade, Serbia

^{2-6,10}Medical School, University of Belgrade, Dr Subotica, Belgrade, Serbia

^{7,8}Department of Pathology, National Cancer Research Center, Pasterova, Belgrade, Serbia

BACKGROUND AND AIMS

Serum calcitonin level (sCt) is a precise marker for medullary thyroid carcinoma (MTC). However, lymph node (LN) metastases can be found in lower sCt, as well, and preoperative ultrasound may provide false negative findings on regional LNs. The

aim was to present the original technique of sentinel lymph node (SLN) biopsy of jugulo-carotid regions, after methylene blue dye mapping procedure, and its usefulness for selection of clinically N0 patients with MTC for modified radical neck dissection (MRND).

METHODS

From 2007 to 2015, 14 patients were operated in our surgical clinic due to MTC with sCt lower than 1000 pg/ml, tumors 10 mm or less in size, and clinically negative regional LNs. Central dissection was done in all patients. The SLN mapping was performed with 0.2 to 0.5 ml of 1% methylene blue dye. Levels II and III were explored on both sides; blue-stained SLNs were removed and examined by frozen section analysis. If benign, additional surrounding noncolored LNs were removed for a more precise evaluation. If SLNs were positive, MRND was performed.

RESULTS

One patient had hereditary form of MTC, with bilateral subcentimeter tumors, while others had sporadic, unilateral MTC. Sporadic MTCs showed no central or lateral LN metastases on bilateral SLN biopsy, with no indication for MRND. Hereditary MTC had central LN metastases, with positive SLNs on both sides; thus, one-time bilateral MRND was performed. This patient had metastases in other dissected LNs, as well, and sCt of 200 pg/ml. Frozen section and definite pathological analysis were 100% matching.

CONCLUSION

Sentinel lymph node biopsy after methylene blue dye injection can be precisely used for intraoperative assessment of lateral LNs. It optimizes surgery for patients with MTCs, selecting clinically N0, but true positive patients for MRND. This pilot study was the first reported experience with SLN biopsy of jugulo-carotid regions in MTC, using methylene blue dye.

The Maximal Size of Metastatic Foci and Radioactive Iodine Avidity are Useful Prognostic Indicators in Patients with Lung Metastases of PTC

¹Mijin Kim, ²Won Gu Kim, ³Su-yeon Park, ⁴Hyemi Kwon, ⁵Min Ji Jeon, ⁶Jong Jin Lee

⁷Jin-Sook Ryu, ⁸Tae Yong Kim, ⁹Young Kee Shong, ¹⁰Won Bae Kim

^{1,2,5,8-10}Department of Internal Medicine, University of Ulsan College of Medicine, Ulsan, South Korea

^{6,7}Department of Nuclear Medicine, University of Ulsan College of Medicine, Ulsan, South Korea

BACKGROUND AND AIMS

Radioactive iodine (RAI) therapy is an effective therapeutic modality for patients with lung metastasis of papillary thyroid carcinoma (PTC). The RAI avidity was known to be an important prognostic factor. In this study, we evaluated the pattern of lung metastases as an independent early prognostic indicator predicting the survival of patients with lung metastasis of PTC.

METHODS

This retrospective cohort study included 72 patients with PTC who confirmed only lung metastases and underwent high-dose RAI treatment (RAIT) in a single center. We evaluated prognostic factors associated with overall survival (OS) and treatment response of RAI according to the pattern of lung metastasis in chest computed tomography (CT). Diffuse micronodular lung metastasis was defined as diffuse metastatic lung lesions less than 1 cm in chest CT.

RESULTS

The mean age of 72 patients (28 male and 44 female) was 47.9 years and 54 patients (75%) had diffuse micronodular lung metastases. The median follow-up period was 9.1 years and the median dose of RAI therapy was 350 mCi. There was more significant biochemical response after RAI therapy in patients with diffuse micronodular metastases (72%) compared with others (31%, $p=0.009$). Patients with diffuse micronodular metastases had significantly better OS compared with others (HR=0.09, 95% CI 0.02–0.31, $p<0.001$). After adjusting for age, sex, tumor size, extrathyroidal invasion, cervical lymph node metastasis, time of lung metastasis, and RAI avidity in metastatic lesion, diffuse micronodular lung metastasis was an independent and better prognostic factor in OS compared with others (HR=0.06, 95% CI 0.01–0.58, $p=0.014$).

CONCLUSION

Patients with diffuse micronodular lung metastases had better survival and response to RAI therapy. The patterns of lung metastasis in CT scan could be an early prognostic indicator in lung metastasis of PTC.

Thyrotoxic Periodic Paralysis and Genetic Susceptibility in Korean Male Patients with Graves' Disease

¹Suyeon Park, ²Tae-Yong Kim, ³Soyoung Sim, ⁴Mijin Kim, ⁵Hyemi Kwon, ⁶Yun Mi Choi, ⁷Min Ji Jeon
⁸Won Gu Kim, ⁹Young Kee Shong, ¹⁰Won Bae Kim

^{1,2,4-10}Department of Internal Medicine, Asan Medical Center, University of Ulsan College of Medicine, Ulsan, South Korea

³Department of Life Science, Asan Institute, Seoul, South Korea

BACKGROUND AND AIMS

Thyrotoxic periodic paralysis (TPP) is characterized by acute-onset paralysis and hypokalemia in male patients with thyrotoxicosis. Many studies suggested that genetic predisposition contributes to TPP susceptibility. This study examined the single-nucleotide polymorphisms (SNP; rs312691) near the inward-rectifying potassium channel, KCNJ2, for association with TPP.

METHODS

This study recruited 48 male Graves' disease (GD) patients with TPP and 48 male GD patients without TPP. Forty samples of TPP patients and 43 samples of GD patients without TPP were analyzed. We extracted genomic DNA from each group and evaluated the differences of the SNP polymorphism allele frequency between two groups.

RESULTS

The CC genotype distribution of the polymorphism rs312691(C > T) adjacent to KCNJ2 was 0.51 in TPP patients and 0.05 in controls (p-value = 6.18×10^{-6}). The allele frequency of CC genotype of the SNP polymorphism showed significant association with TPP (OR = 3.24, 95% CI 1.65–6.51, p-value = 3.1×10^{-4}).

CONCLUSION

The polymorphism of the SNP (rs312691) is significantly associated with TPP susceptibility in Korean male GD patients.

Can Robotic Surgery really be applied to Papillary Thyroid Carcinoma with Lateral Lymph Node Metastasis?

¹Kyung Ho Kang, ²Se Hyun Paek, ³Byung Sup Kim, ⁴Sung Jun Park

^{1,4}Department of Surgery, Chung-Ang University, Seoul, South Korea

²Department of Surgery, On Nu Ri Hospital, Korea

³Department of Surgery, Hi You Thyroid Clinic, Korea

BACKGROUND AND AIMS

Robotic thyroid surgery with bilateral axillobreast approach (BABA) has been settled down as a good alternative to conventional open surgery for early thyroid cancer when performed by experienced endocrine surgeon. Nowadays some initiative surgeons are trying to expand the indications for robotic thyroid surgery to thyroid cancer with lateral lymph node metastasis. Here, we compared surgical outcomes of robotic BABA and conventional open modified radical neck dissection (MRND) for papillary thyroid carcinoma (PTC) with lateral lymph node metastasis.

METHODS

Between March 2012 and August 2015, 112 patients diagnosed as PTC with lateral lymph node metastasis underwent total thyroidectomy, routine bilateral central neck dissection, and selective lateral neck dissection of level IIa, III, IV, and Vb area. Of these patients, robotic BABA procedures were performed in 28 patients and open procedures in 84 patients. Surgical outcomes of these two groups were compared retrospectively.

RESULTS

The robotic group was statistically younger (35.29 ± 8.54 vs 43.89 ± 11.37 , $p < 0.001$) and had smaller tumor size (1.07 ± 0.69 vs 1.61 ± 1.31 , $p = 0.006$) than the open group. The operating time was longer (335.3 ± 45.7 minutes vs 200.9 ± 41.3 minutes, $p < 0.001$) but hospital stay was shorter (4.89 ± 1.73 vs 5.88 ± 4.43 days, $p < 0.046$) in the robotic group. Postoperative complication rates were similar in the two groups and there was no difference in the number of retrieved lymph nodes, metastatic lymph nodes, or postoperative stimulated thyroglobulin (sTg) level between the two groups. But the proportion of patients with less than 1.0 ng/ml of sTg level was significantly higher in the robotic group (Table 1).

CONCLUSION

Patients with PTC with lateral lymph node metastasis can be managed safely and effectively with robotic surgery with oncologic and postoperative outcomes comparable to those of the open procedure (Table 2).

Table 1: Clinicopathological characteristics

Variables	Open MRND (n = 84)	Robotic MRND (n = 28)	p-value
Mean age in years	43.89 ± 11.37	35.29 ± 8.54	0.000
Gender [M:F (F%)]	30:54 (64.3%)	6:22 (78.6%)	0.161
Operation time, min	200.9 ± 41.3	335.3 ± 45.7	0.000
Hospital stay	5.88 ± 4.43	4.89 ± 1.73	0.046
Mean tumor size, cm	1.61 ± 1.31	1.07 ± 0.69	0.006
Extrathyroidal extension	71.4% (60/84)	50% (14/28)	0.038
Central LN			
Mean number of retrieved LNs	11.24 ± 6.02	11.43 ± 5.85	0.884
Mean number of metastatic LNs	5.11 ± 4.34	4.46 ± 3.42	0.425
Lateral LN			
Mean number of retrieved LNs	27.37 ± 11.26	30.07 ± 10.68	0.268
Mean number of metastatic LNs	4.94 ± 3.63	4.43 ± 3.83	0.525

Table 2: Operative outcomes

Variables	Open MRND (n = 84)	Robotic MRND (n = 28)	p-value
Transient hypoparathyroidism	IS (17.9%)	3 (10.7%)	0.373
Permanent hypoparathyroidism	1 (1.2%)	0 (0%)	0.562
Transient VC palsy	6 (7.1%)	2 (7.1%)	1.000
Permanent VC palsy	1 (1.2%)	1 (3.6%)	0.410
Postoperative bleeding	0		1.000
Wound infection	0		1.000
Chyle leak	1	0	0.562
Stimulated Tg level, ng/mL (median)	0.82 (0.08–2860.29)	0.38 (0.08–11.77)	0.466
Proportion of sTg < 1.0 ng/ml	51.3%	74.1%	0.040

A Study on the Incidence of Recurrent Laryngeal Nerve Palsy without Neuromonitoring

¹Periyasamy Selladurai, ²Dhalapathy Sadacharan, ³Gajarajan Mohanapriya, ⁴Zahir Hussain, ⁵RV Suresh

¹⁻⁵Department of Endocrine Surgery, Madras Medical College, Chennai, Tamil Nadu, India

BACKGROUND AND AIMS

Recurrent laryngeal nerve (RLN) palsy is still the most dreaded complication in total thyroidectomy (TT). The incidence of permanent RLN palsy ranges from 0.5 to 4%. We intend to study the incidence of RLN palsy in patients undergoing TT in a tertiary care center and compare it with the global scenario.

METHODS

This retrospective study was done at an endocrine surgical center in south India, between September 2014 and April 2015. A total of 139 patients (16 males and 113 females) who underwent TT for benign thyroid disorder were included in the study. Malignant and reoperative cases were excluded. Video laryngoscopy was done for all cases and documented preoperatively. All cases were done by a single endocrine surgeon. The direct visualization method was used to identify the course of RLN. Follow-up was done at 1, 3, and 6 months postoperatively with video laryngoscopy.

RESULTS

The mean age of the study population was 38.45 ± 3.34 years. At 1-month follow-up, 20/139 (12.94%) had transient RLN palsy. At 3 months' follow-up, 8/139 (5.75%) had transient RLN palsy. On further follow-up at 6 months, only 2/139 (1.43%) had RLN palsy. These two patients were labeled as having permanent RLN palsy. A systematic review of literature was done, comparing our study with other similar studies done with/without neuromonitoring for RLN identification (Table 1).

CONCLUSION

A thorough anatomical knowledge and meticulous dissection of RLN course definitely reduces the incidence of RLN injury. Although transient RLN palsy may be high without neuromonitoring, the incidence of permanent RLN palsy is comparable.

Table 1: Review of literature

<i>University</i>	<i>Transient rln palsy %</i>	<i>Permanent rln palsy %</i>
(1) Celakovsky P et al.	4.5	0.8
(2) Calo PG et al.(2011)		
Without Neuro monitoring (NM)	2.22	0.74
With NM	1.86	0.8
(3) Chiang F et al.		
With NM	2.7	1.2
Without NM	7.9	5.2
(4) Calo PG et al.(2014)		
Without NM	2.11	0.7
With NM	1.63	0.58
(5) Our study	12.9	1.43